A 55-year-old woman comes to the emergency department with nausea, fever, fatigue, and anorexia. She returned a week ago from a trip to Mexico, where she underwent an emergency cholecystectomy without complications. Her temperature is 38.3 C (101 F), blood pressure is 100/60 mm Hg, pulse is 90/min, and respirations are 12/min. The patient is alert and answers questions but appears extremely weak and slightly icteric. She has no other medical problems and takes no medications. She does not use tobacco, alcohol, or illicit drugs. The patient is admitted to the hospital, but her condition worsens and she dies 2 days later. Postmortem viral serologies are negative. Gross examination of the liver on autopsy is shown in the image below.

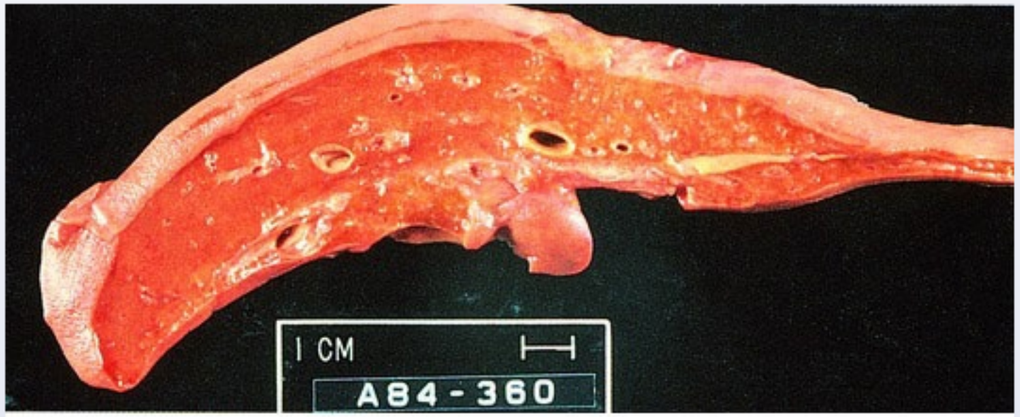

Displayed with permission from Springer Healthcare Ltd. © Copyright 2006 by Current Medicine

Which of the following additional findings would have most likely been found in this patient?

- A. Decreased serum albumin level
- B. Distended abdominal veins and ascites
- C. Normal alanine aminotransferase level
- D. Palmar erythema
- E. Prolonged prothrombin time

hospital, but her condition worsens and she dies 2 days later. Postmortem viral serologies are negative. Gross examination of the liver on autopsy is shown in the image below.

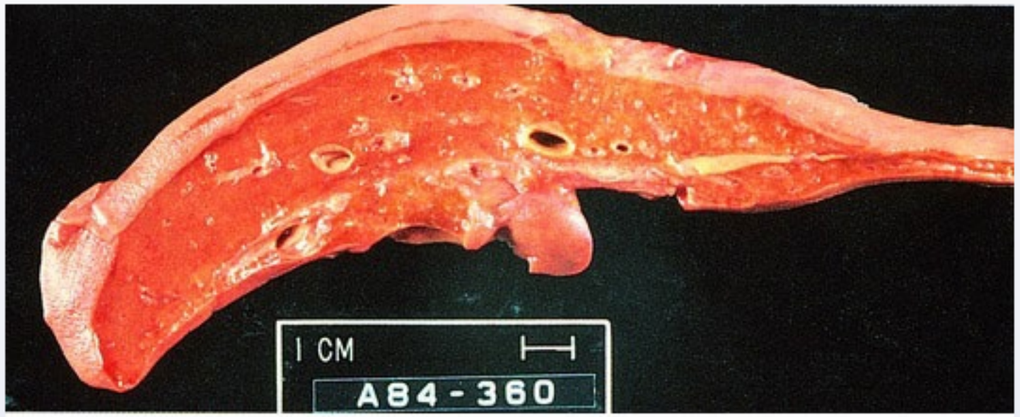

Displayed with permission from Springer Healthcare Ltd. © Copyright 2006 by Current Medicine

Which of the following additional findings would have most likely been found in this patient?

- A. Decreased serum albumin level
- B. Distended abdominal veins and ascites
- C. Normal alanine aminotransferase level
- D. Palmar erythema
- E. Prolonged prothrombin time
- F. Splenomegaly

Submit

hospital, but her condition worsens and she dies 2 days later. Postmortem viral serologies are negative. Gross examination of the liver on autopsy is shown in the image below.

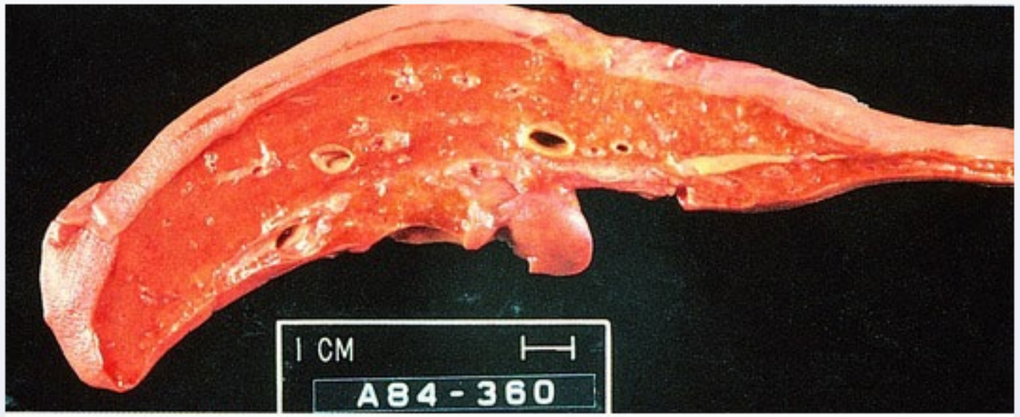

Displayed with permission from Springer Healthcare Ltd. © Copyright 2006 by Current Medicine

Which of the following additional findings would have most likely been found in this patient?

- A. Decreased serum albumin level (17%)
- B. Distended abdominal veins and ascites (15%)
- C. Normal alanine aminotransferase level (15%)
- D. Palmar erythema (6%)
- ✓ E. Prolonged prothrombin time (32%)
- F. Splenomegaly (12%)

Omitted
Correct answer

32%
Answered correctly

05 secs
Time Spent

06/21/2020
Last Updated

This patient presents after a recent surgery with signs and symptoms consistent with **drug-induced liver injury**, most likely due to inhaled anesthetic use. **Inhaled anesthetic hepatotoxicity** is most frequently associated with halothane, which remains one of the most commonly used inhaled anesthetics worldwide. In the United States, halothane has been largely replaced with other halogenated anesthetics, such as enflurane, isoflurane, desflurane, and sevoflurane. Although these agents are safer than halothane, there have been reports of associated hepatotoxicity.

Halogenated inhaled anesthetics predominantly cause a **hepatocellular pattern** of liver injury. This can range from mild asymptomatic aminotransferase elevation to **fulminant hepatitis** with a 50% fatality rate. In severe cases, extensive hepatocellular damage causes the liver to rapidly atrophy and appear **shrunken** on autopsy. Histologically, widespread centrilobular necrosis and inflammation of the portal tracts and parenchyma are observed, making the condition indistinguishable from fulminant viral hepatitis. The underlying mechanism is thought to be a hypersensitivity reaction to the drug that causes an immune-mediated attack against hepatocytes.

Patients suffering from inhaled-anesthetic hepatotoxicity typically have fever, anorexia, nausea, myalgias, arthralgias, and rash. Tender hepatomegaly (reflecting widespread liver inflammation) and jaundice can be present on physical examination. Laboratory findings typically include markedly **elevated serum aminotransferase levels, prolonged prothrombin time**, leukocytosis, and eosinophilia. The prolonged prothrombin time is due to failure of hepatic synthetic function and deficiency of factor VII (which has the shortest half-life of all the procoagulant factors).

(Choice A) Decreased serum albumin levels are commonly seen in patients with chronic, end-stage liver disease as the remaining hepatocytes have reduced functionality. However, acute liver injury presents with normal albumin levels due to the long half-life of albumin (~20 days).

(Choices B and D) Distended abdominal veins with ascites and palmar erythema are usually seen in patients with end-stage liver disease (eg, cirrhosis). These findings are not associated with acute hepatic failure.

(Choice C) A markedly elevated alanine aminotransferase level would be expected with fulminant hepatic failure.

(Choice F) Splenomegaly develops secondary to portal hypertension and can be seen in cirrhotic patients. It is not associated with acute hepatitis.

Educational objective:
Inhaled anesthetics, such as halothane, can be associated with a highly lethal fulminant hepatitis that cannot be distinguished histologically from acute viral hepatitis. Patients have significantly elevated aminotransferase levels due to massive hepatocellular injury and a prolonged

hypersensitivity reaction to the drug that causes an immune-mediated attack against hepatocytes.

Patients suffering from inhaled-anesthetic hepatotoxicity typically have fever, anorexia, nausea, myalgias, arthralgias, and rash. Tender hepatomegaly (reflecting widespread liver inflammation) and jaundice can be present on physical examination. Laboratory findings typically include markedly **elevated serum aminotransferase levels, prolonged prothrombin time**, leukocytosis, and eosinophilia. The prolonged prothrombin time is due to failure of hepatic synthetic function and deficiency of factor VII (which has the shortest half-life of all the procoagulant factors).

(Choice A) Decreased serum albumin levels are commonly seen in patients with chronic, end-stage liver disease as the remaining hepatocytes have reduced functionality. However, acute liver injury presents with normal albumin levels due to the long half-life of albumin (~20 days).

(Choices B and D) Distended abdominal veins with ascites and palmar erythema are usually seen in patients with end-stage liver disease (eg, cirrhosis). These findings are not associated with acute hepatic failure.

(Choice C) A markedly elevated alanine aminotransferase level would be expected with fulminant hepatic failure.

(Choice F) Splenomegaly develops secondary to portal hypertension and can be seen in cirrhotic patients. It is not associated with acute hepatitis.

Educational objective:
Inhaled anesthetics, such as halothane, can be associated with a highly lethal fulminant hepatitis that cannot be distinguished histologically from acute viral hepatitis. Patients have significantly elevated aminotransferase levels due to massive hepatocellular injury and a prolonged prothrombin time due to failure of hepatic synthetic function.

References

- Halothane-induced hepatitis: a forgotten issue in developing countries.

Pathophysiology	Gastrointestinal & Nutrition	Acute liver failure
Subject	System	Topic

Copyright © UWorld. All rights reserved.

A 33-year-old man with a 2-year history of Crohn ileocolitis comes to the clinic with left-sided flank pain that started in the morning. The pain is 8 on a scale of 0-10 in intensity and is characterized as sharp. The pain is also colicky and radiates to the left groin. The patient has no nausea or vomiting. He is in moderate distress and has trouble lying still during the examination. Urinalysis shows hematuria. A day later, the patient passes a urinary stone. Abdominal imaging reveals several additional kidney stones. Which of the following is the most likely underlying cause of this patient's kidney stones?

A. Defective amino acid transport

B. Increased bone resorption

C. Rapid cell turnover

D. Reduced intestinal calcium oxalate formation

E. Urinary tract infection

Submit

A 33-year-old man with a 2-year history of Crohn ileocolitis comes to the clinic with left-sided flank pain that started in the morning. The pain is 8 on a scale of 0-10 in intensity and is characterized as sharp. The pain is also colicky and radiates to the left groin. The patient has no nausea or vomiting. He is in moderate distress and has trouble lying still during the examination. Urinalysis shows hematuria. A day later, the patient passes a urinary stone. Abdominal imaging reveals several additional kidney stones. Which of the following is the most likely underlying cause of this patient's kidney stones?

- A. Defective amino acid transport (8%)
- B. Increased bone resorption (8%)
- C. Rapid cell turnover (7%)
- ✓ D. Reduced intestinal calcium oxalate formation (72%)
- E. Urinary tract infection (2%)

Omitted
Correct answer
D

72%
Answered correctly

02 secs
Time Spent

07/09/2020
Last Updated

Explanation

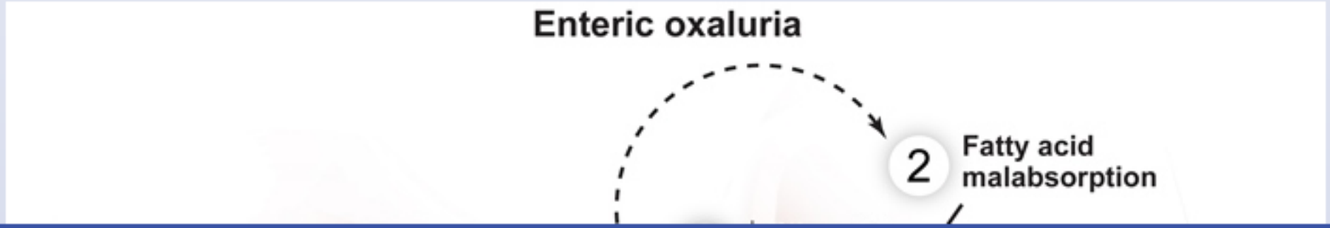

Explanation

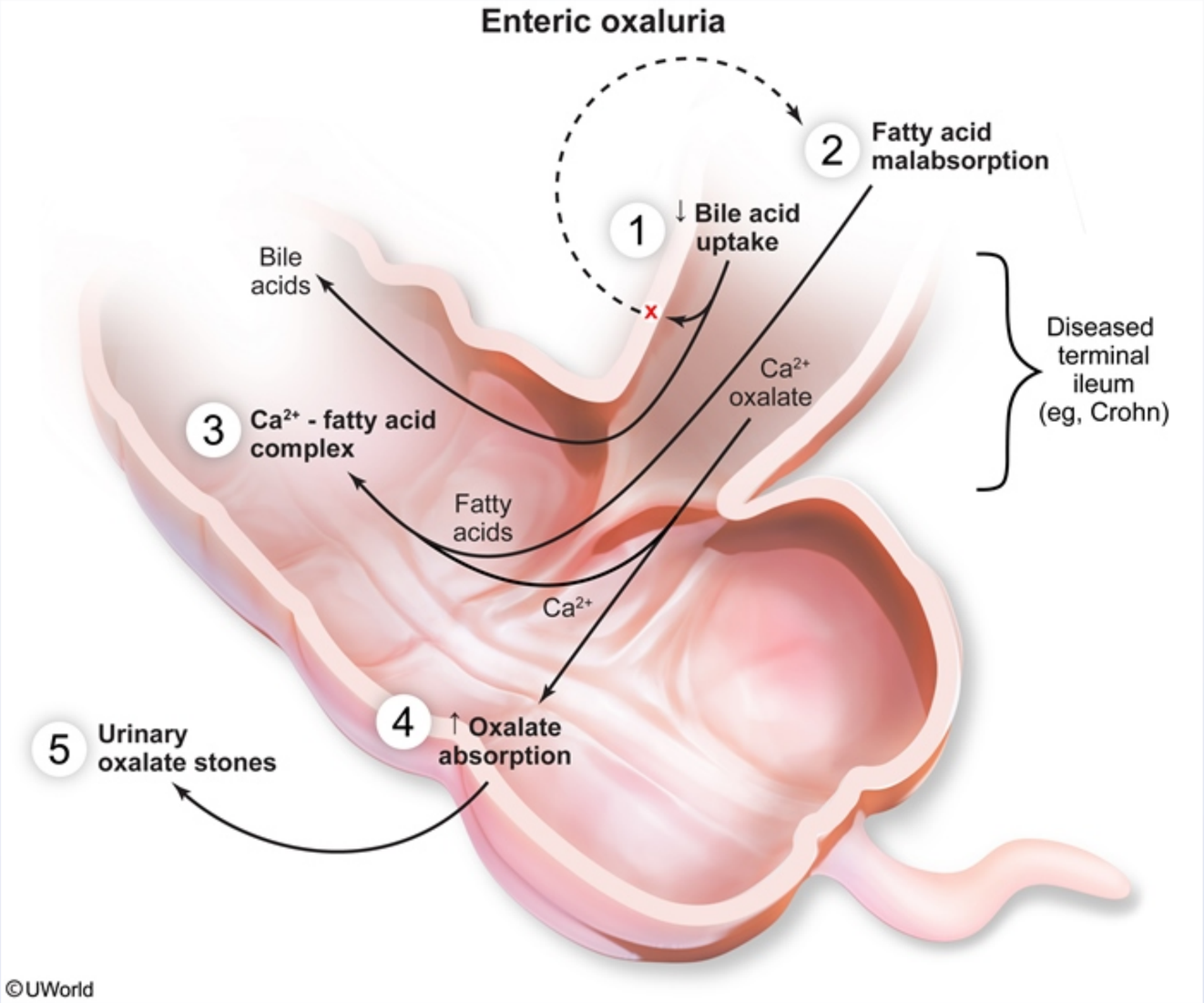

©UWorld

Crohn disease is an inflammatory bowel disease characterized by patchy granulomatous inflammation. Any area of the gastrointestinal tract may be involved, but involvement of the **terminal ileum** is especially common. Bile acids, which facilitate the absorption of fats and fat-soluble vitamins, are normally reabsorbed in the ileum, recycled in the liver, and then reused in the absorptive process. When the terminal ileum is inflamed, bile acids are lost in the feces, leading to **impaired fat absorption**.

In the healthy bowel, dietary calcium binds to dietary oxalate, producing insoluble calcium oxalate salts that are eliminated in the feces. But in malabsorptive syndromes such as Crohn disease, calcium forms soap complexes with the excess fat in the intestinal lumen and is unavailable for complexing with oxalate. As a result, free **oxalate absorption** is increased and subsequently filtered into the urine, promoting the formation of **oxalate kidney stones** (enteric oxaluria).

(Choice A) Cystinuria is an autosomal recessive condition characterized by defective dibasic amino acid transport in the proximal renal tubules. The urine becomes supersaturated with cystine, leading to formation of cystine stones beginning in childhood or adolescence. Crohn disease can cause malabsorption of dietary protein and amino acids, but this is due to inflammation, not abnormal amino acid transporters; patients are not predisposed to cystine stones.

(Choice B) Patients with Crohn disease commonly develop vitamin/nutrient deficiencies (eg, vitamin D, calcium) due to malabsorption, which can reduce bone mineral density and increase the risk of fractures. Secondary hyperparathyroidism may be present, but unlike primary hyperparathyroidism does not promote kidney stone formation.

(Choice C) Uric acid stones may develop from conditions associated with rapid cell turnover (eg, myeloproliferative disease, hemolytic anemia) due to chronically increased uric acid production. The stones seen in Crohn disease are composed of calcium oxalate rather than uric acid.

(Choice E) Alkalinization of the urine by urease-producing organisms (eg, *Proteus*, *Klebsiella*) in the upper urinary tract can promote formation of stones made up of magnesium ammonium phosphate (struvite) and calcium carbonate apatite. Although patients with Crohn disease can develop enterovesicular fistulas and recurrent urinary tract infections, this patient has no features of urinary infection (eg, fever, dysuria, pyuria).

Educational objective:
Crohn disease is associated with oxalate kidney stones. Impaired bile acid absorption in the terminal ileum leads to loss of bile acids in feces with subsequent fat malabsorption. Intestinal lipids then bind calcium ions, and the resulting soap complex is excreted. Free oxalate (normally bound by calcium to form an unabsorbable complex) is absorbed and forms urinary calculi (enteric oxaluria).

complexing with oxalate. As a result, free **oxalate absorption** is increased and subsequently filtered into the urine, promoting the formation of **oxalate kidney stones** (enteric oxaluria).

(Choice A) Cystinuria is an autosomal recessive condition characterized by defective dibasic amino acid transport in the proximal renal tubules. The urine becomes supersaturated with cystine, leading to formation of cystine stones beginning in childhood or adolescence. Crohn disease can cause malabsorption of dietary protein and amino acids, but this is due to inflammation, not abnormal amino acid transporters; patients are not predisposed to cystine stones.

(Choice B) Patients with Crohn disease commonly develop vitamin/nutrient deficiencies (eg, vitamin D, calcium) due to malabsorption, which can reduce bone mineral density and increase the risk of fractures. Secondary hyperparathyroidism may be present, but unlike primary hyperparathyroidism does not promote kidney stone formation.

(Choice C) Uric acid stones may develop from conditions associated with rapid cell turnover (eg, myeloproliferative disease, hemolytic anemia) due to chronically increased uric acid production. The stones seen in Crohn disease are composed of calcium oxalate rather than uric acid.

(Choice E) Alkalinization of the urine by urease-producing organisms (eg, *Proteus*, *Klebsiella*) in the upper urinary tract can promote formation of stones made up of magnesium ammonium phosphate (struvite) and calcium carbonate apatite. Although patients with Crohn disease can develop enterovesicular fistulas and recurrent urinary tract infections, this patient has no features of urinary infection (eg, fever, dysuria, pyuria).

Educational objective:
Crohn disease is associated with oxalate kidney stones. Impaired bile acid absorption in the terminal ileum leads to loss of bile acids in feces with subsequent fat malabsorption. Intestinal lipids then bind calcium ions, and the resulting soap complex is excreted. Free oxalate (normally bound by calcium to form an unabsorbable complex) is absorbed and forms urinary calculi (enteric oxaluria).

References

- Urolithiasis in inflammatory bowel disease and bariatric surgery.

Pathophysiology	Gastrointestinal & Nutrition	Inflammatory bowel disease
Subject	System	Topic

Copyright © UWorld. All rights reserved.

A 44-year-old man with a long-standing history of heartburn comes to the office due to worsening substernal burning, particularly at night. The discomfort has been less responsive than usual to over-the-counter antacids. The patient also now has significant substernal pain after swallowing food. However, swallowing does not result in coughing, choking, or a sensation of food getting stuck. He has no other chronic medical conditions. Recent HIV testing was negative. The patient takes no other medications. He drinks 2 or 3 beers each evening and smokes a pack of cigarettes daily. BMI is 34 kg/m^2. Vital signs are within normal limits. Physical examination reveals no abnormalities. The recent worsening of this patient's symptoms is most likely related to which of the following?

A. Columnar metaplasia
B. Herpes simplex infection
C. Malignancy
D. Stricture
E. Ulceration

Submit

A 44-year-old man with a long-standing history of heartburn comes to the office due to worsening substernal burning, particularly at night. The discomfort has been less responsive than usual to over-the-counter antacids. The patient also now has significant substernal pain after swallowing food. However, swallowing does not result in coughing, choking, or a sensation of food getting stuck. He has no other chronic medical conditions. Recent HIV testing was negative. The patient takes no other medications. He drinks 2 or 3 beers each evening and smokes a pack of cigarettes daily. BMI is 34 kg/m^2. Vital signs are within normal limits. Physical examination reveals no abnormalities. The recent worsening of this patient's symptoms is most likely related to which of the following?

- A. Columnar metaplasia (33%)
- B. Herpes simplex infection (1%)
- C. Malignancy (11%)
- D. Stricture (5%)
- ✓ E. Ulceration (47%)

Omitted
Correct answer
E

47%
Answered correctly

03 secs
Time Spent

05/23/2020
Last Updated

Explanation

Gastroesophageal reflux disease	
Pathophysiology	• Decreased tone or excessive transient relaxation of LES • Anatomic disruption to gastroesophageal junction (eg, hiatal hernia)

Gastroesophageal reflux disease	
Pathophysiology	• Decreased tone or excessive transient relaxation of LES • Anatomic disruption to gastroesophageal junction (eg, hiatal hernia) • ↑ Risk with obesity, pregnancy, smoking, alcohol intake
Manifestations	• Regurgitation of acidic material in mouth • **Heartburn** • Odynophagia (often indicates reflux esophagitis) • Extraesophageal symptoms (eg, cough, laryngitis, wheezing)
Complications	• Erosive esophagitis • Strictures • Barrett esophagus → adenocarcinoma
Initial treatment	• Lifestyle (eg, weight loss) & dietary changes • H2R blocker or proton pump inhibitor

H2R = histamine 2 receptor; **LES** = lower esophageal sphincter.

Gastroesophageal reflux disease (GERD) is caused by the retrograde flow of acidic stomach contents through the lower esophageal sphincter into the esophagus. Common symptoms include burning pain in the retrosternal area (**heartburn**) and **acid regurgitation** into the back of the mouth. GERD usually does not cause esophageal mucosal injury, but frequent exposure to highly acidic secretions can overwhelm esophageal mucosal defense mechanisms and result in epithelial damage and **complications**, such as:

- **Erosive esophagitis** with esophageal **ulcers** - often marked by a worsening of baseline GERD symptoms and the development of **odynophagia** (painful swallowing).
- Barrett esophagus - metaplastic columnar epithelium replaces the normal stratified squamous epithelium in the distal esophagus. Most cases are asymptomatic with no change in baseline GERD manifestations. However, Barrett esophagus is a premalignant condition for

H2R = histamine 2 receptor; LES = lower esophageal sphincter.

Gastroesophageal reflux disease (GERD) is caused by the retrograde flow of acidic stomach contents through the lower esophageal sphincter into the esophagus. Common symptoms include burning pain in the retrosternal area (**heartburn**) and **acid regurgitation** into the back of the mouth. GERD usually does not cause esophageal mucosal injury, but frequent exposure to highly acidic secretions can overwhelm esophageal mucosal defense mechanisms and result in epithelial damage and **complications**, such as:

- **Erosive esophagitis** with esophageal **ulcers** - often marked by a worsening of baseline GERD symptoms and the development of **odynophagia** (painful swallowing).
- Barrett esophagus - metaplastic columnar epithelium replaces the normal stratified squamous epithelium in the distal esophagus. Most cases are asymptomatic with no change in baseline GERD manifestations. However, Barrett esophagus is a premalignant condition for esophageal adenocarcinoma, which typically presents with dysphagia and weight loss **(Choices A and C)**.
- Esophageal stricture - typically develops in the setting of a healing esophageal ulcer when collagen fibers contract and cause narrowing of the esophageal lumen. Patients usually present with dysphagia and a sensation of food getting stuck in the esophagus **(Choice D)**.

(Choice B) Infectious esophagitis can be caused by a number of agents, including cytomegalovirus, Candida, and herpes simplex virus. However, it occurs most commonly in immunosuppressed patients (eg, AIDS, prolonged steroids). This patient has no evidence of an immunocompromised state (eg, recent HIV testing was negative) and has long-standing GERD, making erosive esophagitis more likely.

Educational objective:
New-onset odynophagia in the setting of chronic gastroesophageal reflux disease should raise suspicion for erosive esophagitis with esophageal ulcers. Diagnosis is made by upper endoscopy.

References

- Pathophysiology of gastro-oesophageal reflux disease.

Pathophysiology	Gastrointestinal & Nutrition	Gastroesophageal reflux disease
Subject	System	Topic

Copyright © UWorld. All rights reserved.

1
2
3
4
5
6
7
8
9
10
11
12
13
14
15
16
17
18
19
20
21
22
23
24
25
26
27
28
29
30
31

A 63-year-old woman dies of congestive heart failure. Autopsy shows a dilated heart with brownish pigmentation of the myocardium. Light microscopy of her liver after Prussian blue staining is shown in the image below:

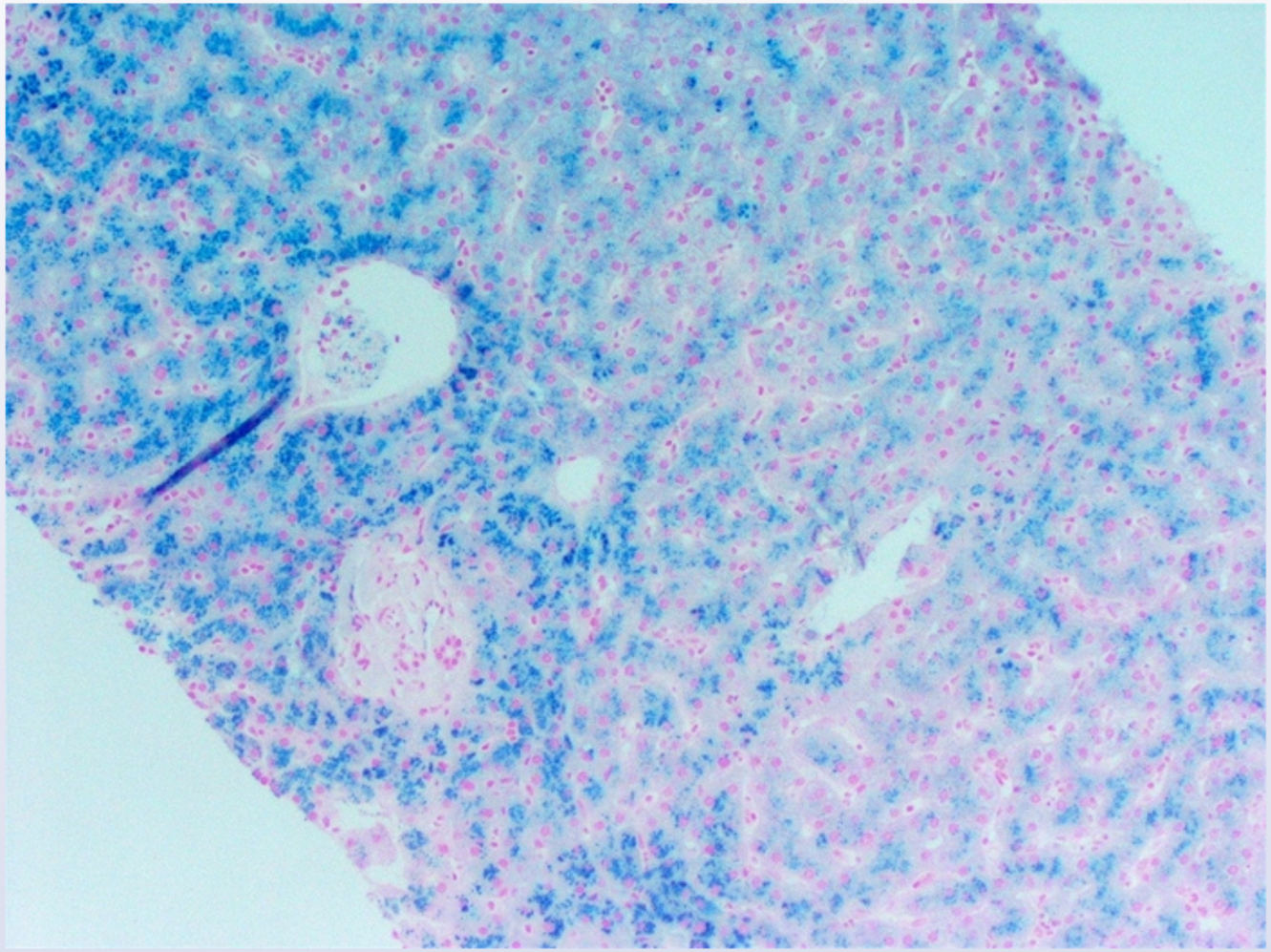

The patient's brother died of profuse upper gastrointestinal bleeding at age 43. Assuming this patient's disorder is hereditary, which of the

1
2
3
4
5
6
7
8
9
10
11
12
13
14
15
16
17
18
19
20
21
22
23
24
25
26
27
28
29
30
31

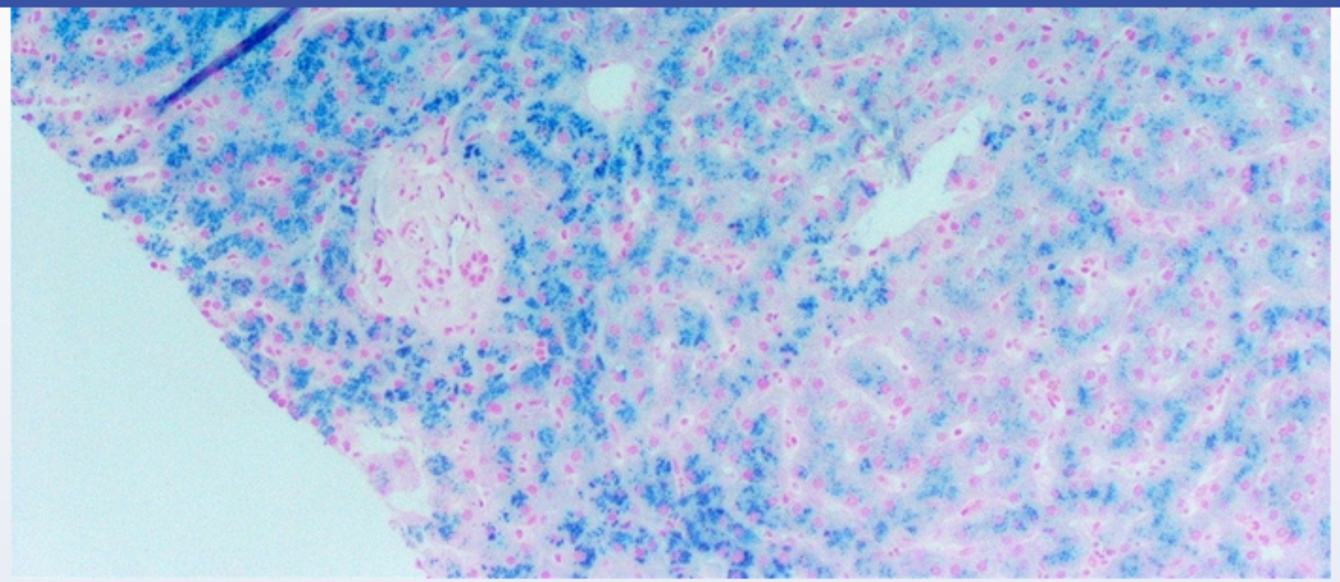

The patient's brother died of profuse upper gastrointestinal bleeding at age 43. Assuming this patient's disorder is hereditary, which of the following most likely contributed to the delayed onset of her disease compared to her brother?

A. Heterozygosity for *HFE* gene mutation

B. High-dose vitamin C intake

C. Incomplete penetrance of homozygotic *HFE* mutations

D. Premenopausal menstrual bleeding

E. Receipt of blood transfusions

Submit

1
2
3
4
5
6
7
8
9
10
11
12
13
14
15
16
17
18
19
20
21
22
23
24
25
26
27
28
29
30
31

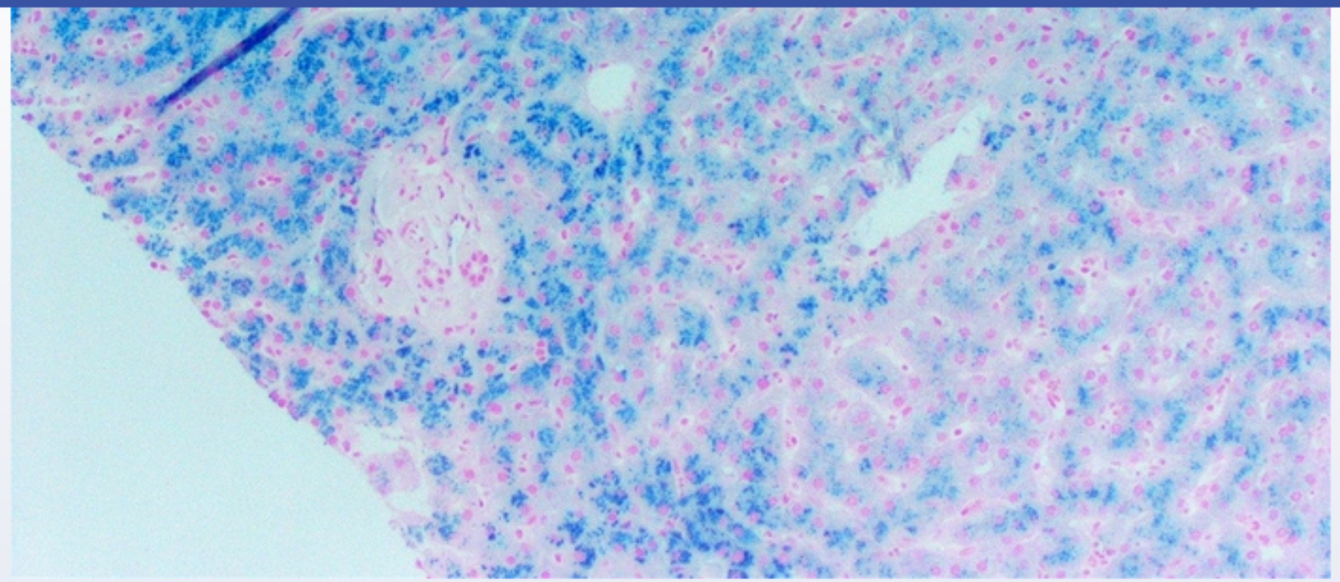

The patient's brother died of profuse upper gastrointestinal bleeding at age 43. Assuming this patient's disorder is hereditary, which of the following most likely contributed to the delayed onset of her disease compared to her brother?

A. Heterozygosity for *HFE* gene mutation (10%)

B. High-dose vitamin C intake (0%)

C. Incomplete penetrance of homozygotic *HFE* mutations (11%)

✓ D. Premenopausal menstrual bleeding (74%)

E. Receipt of blood transfusions (2%)

Omitted
Correct answer

74%
Answered correctly

07 secs
Time Spent

06/30/2020
Last Updated

1
2
3
4
5
6
7
8
9
10
11
12
13
14
15
16
17
18
19
20
21
22
23
24
25
26
27
28
29
30
31

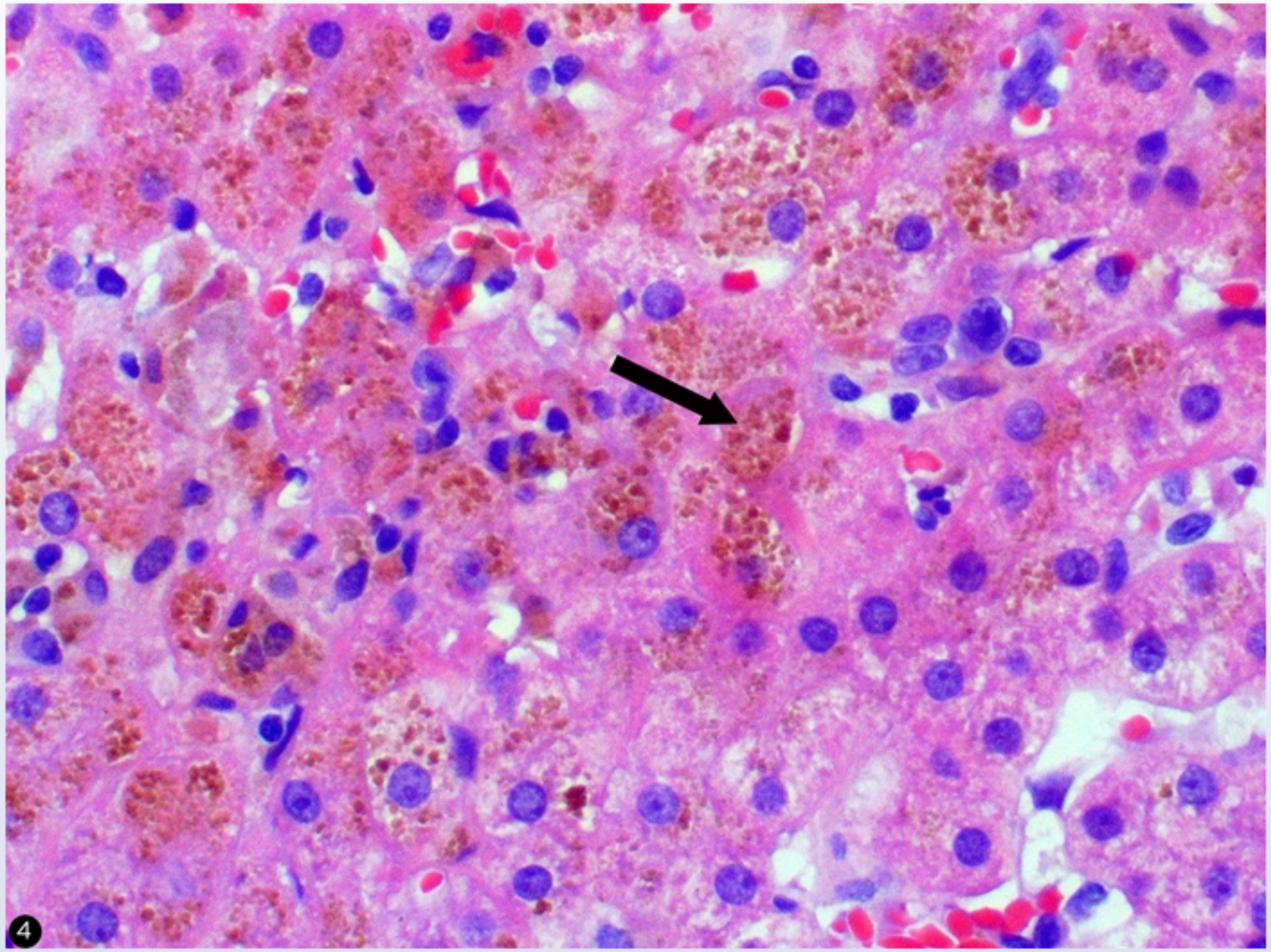

This patient has cardiomyopathy with visible brown discoloration, which could represent lipofuscin (age-related pigment) or hemosiderin (iron deposition). However, her liver specimen shows diffuse infiltration of iron (visible as blue pigment granules after **Prussian blue** staining), confirming a diagnosis of iron overload. Given that her brother likely developed cirrhosis complicated by variceal hemorrhage in his 40s, the most probable underlying cause is **hereditary hemochromatosis (HH)**.

confirming a diagnosis of iron overload. Given that her brother likely developed cirrhosis complicated by variceal hemorrhage in his 40s, the most probable underlying cause is **hereditary hemochromatosis (HH)**.

Total iron stores in the body are tightly regulated at the point of intake, with gastrointestinal absorption adjusted to match daily losses. HH is an autosomal recessive disorder characterized by **increased intestinal iron absorption**; because there is no specific mechanism to excrete unneeded iron, the excess iron (typically 0.5-1.0 g/yr) accumulates in the parenchymal organs (eg, liver, heart).

HH is usually silent in early adulthood, manifesting only after >20 g of iron has accumulated in the body. Men typically begin to develop symptoms in their 30s and 40s. However, **premenopausal women** have ongoing **blood (and iron) losses** due to **menstruation**, which partially offsets the excess iron absorption. Women therefore **develop manifestations later**, typically several years after menopause (ie, variable expressivity based on sex).

(Choices A and C) Most patients with HH have inactivating mutations in the *HFE* gene that cause impaired hepcidin secretion. Disease development requires biallelic genetic mutations (ie, affecting both alleles); heterozygotes are unaffected. Although biallelic *HFE* inactivation is necessary to develop the condition, most patients (>70%) with biallelic mutations never develop HH (ie, the disease exhibits incomplete penetrance) due to genetic and environmental modifiers. However, this patient developed HH manifestations at a typical age for women, which would not be explained by heterozygosity or incomplete penetrance.

(Choice B) Ascorbic acid (vitamin C) and citric acid enhance the absorption of inorganic iron in the gastrointestinal tract and therefore might lead to earlier disease manifestations instead of slowing its onset.

(Choice E) Frequent blood transfusions can also lead to iron overload and hemosiderosis (iron accumulation in parenchymal tissues). The opposite, therapeutic phlebotomy, is the preferred treatment for HH and has been shown to slow its progression.

Educational objective:
Hereditary hemochromatosis is characterized by increased intestinal iron absorption with deposition of excess iron in parenchymal tissues. Men typically develop manifestations in their 30s and 40s. However, premenopausal women have ongoing blood and iron losses due to menstruation, which partially offsets the excess iron absorption and delays the onset of symptoms.

Pathophysiology	Gastrointestinal & Nutrition	Hemochromatosis
Subject	System	Topic

A 38-year-old man comes to the office with abdominal discomfort and loose stools over the past year. He has also lost 10 kg (22 lb) despite having a normal appetite. The patient eats a balanced diet that includes a variety of fruits and vegetables, meats, whole grains, and dairy products. He has had no international travel, works indoors as an office manager, and has no sick contacts. Medical history is insignificant and the patient takes no medications. The patient drinks alcohol socially and does not use tobacco. Vital signs and physical examination are normal. Serum chemistry panel, complete blood count, and thyroid function tests are normal. Which of the following is the best next step for assessing for impaired nutrient absorption in this patient?

A. Abdominal ultrasound

B. Colonoscopy

C. Jejunal biopsy

D. Stool evaluation for ova and parasites

E. Stool microscopy with Sudan III stain

F. Vitamin B_{12} level

Submit

A 38-year-old man comes to the office with abdominal discomfort and loose stools over the past year. He has also lost 10 kg (22 lb) despite having a normal appetite. The patient eats a balanced diet that includes a variety of fruits and vegetables, meats, whole grains, and dairy products. He has had no international travel, works indoors as an office manager, and has no sick contacts. Medical history is insignificant and the patient takes no medications. The patient drinks alcohol socially and does not use tobacco. Vital signs and physical examination are normal. Serum chemistry panel, complete blood count, and thyroid function tests are normal. Which of the following is the best next step for assessing for impaired nutrient absorption in this patient?

- A. Abdominal ultrasound (4%)
- B. Colonoscopy (19%)
- C. Jejunal biopsy (29%)
- D. Stool evaluation for ova and parasites (9%)
- ✓ E. Stool microscopy with Sudan III stain (27%)
- F. Vitamin B_{12} level (9%)

Omitted
Correct answer
E

27%
Answered correctly

02 secs
Time Spent

06/04/2020
Last Updated

Explanation

Impaired intestinal absorption of nutrients is called **malabsorption**. Significant malabsorption may present with diarrhea and **steatorrhea** (bulky, foul-smelling stools; visible oil droplets; greasy toilet ring), but more often patients have nonspecific symptoms such as weight loss, fatigue, or vague abdominal discomfort. Patients may also have characteristic findings due to specific nutrient deficiencies. Generalized malabsorption is

Impaired intestinal absorption of nutrients is called **malabsorption**. Significant malabsorption may present with diarrhea and **steatorrhea** (bulky, foul-smelling stools; visible oil droplets; greasy toilet ring), but more often patients have nonspecific symptoms such as weight loss, fatigue, or vague abdominal discomfort. Patients may also have characteristic findings due to specific nutrient deficiencies. Generalized malabsorption is commonly due to defects in pancreatic secretion (eg, chronic pancreatitis, cystic fibrosis), mucosal disorders (eg, celiac disease, inflammatory bowel disease), bacterial overgrowth (eg, gastrointestinal surgery, abnormal motility), or parasitic diseases (eg, *Giardia*).

Dietary lipids are the macronutrient with the most complex digestive pathway. Fats are typically the earliest and most severely affected nutrient in generalized malabsorption, and **testing for fat** malabsorption is therefore the **most sensitive** strategy for screening for malabsorptive disorders. A qualitative assay of stool with **Sudan III stain** can quickly and easily identify unabsorbed fat and confirm malabsorption. (Stool should normally contain no measurable fat.)

(Choices A, B, C, and D) Abdominal imaging can be used to identify thickening of the bowel wall due to inflammation or structural disorders of the pancreas (eg, chronic pancreatitis). Endoscopy with jejunal biopsy can diagnose celiac disease, and colonoscopy can identify inflammatory bowel disease. Stool inspection for ova and parasites can identify infectious causes of malabsorption such as *Giardia* and *Cryptosporidium*. Although these tests are useful for determining **specific causes** of generalized malabsorption, fecal fat testing is a less invasive and more sensitive test for confirming malabsorption of any etiology.

(Choice F) Iron and vitamin B_{12} deficiency occur commonly in patients with malabsorption. However, vitamin B_{12} levels have a low sensitivity for malabsorption; deficiency develops only after years and is more common with specific etiologies (eg, pernicious anemia). In addition, this patient's normal complete blood count makes vitamin B_{12} deficiency less likely.

Educational objective:
Malabsorption is a syndrome of impaired intestinal digestion and absorption. Fats are typically the most severely affected macronutrient in generalized malabsorption, and testing the stool for fat (eg, with Sudan III stain) is the most sensitive strategy for screening for malabsorptive disorders.

Pathophysiology	Gastrointestinal & Nutrition	Malabsorption
Subject	System	Topic

Copyright © UWorld. All rights reserved.

Exhibit Display

Nutrient deficiencies associated with malabsorption	
Nutrient	**Clinical presentation**
Protein	Muscle wasting, edema
Fat	Weight loss
Iron **Folate** **Vitamin B_{12}**	Anemia
Calcium **Vitamin D**	Bone pain, muscle weakness, tetany
Vitamin A	Hyperkeratosis, night blindness
Vitamin K	Petechiae, easy bruising

©UWorld

Zoom In
Zoom Out
Reset
Add To New Card | Existing Card

Copyright © UWorld. All rights reserved.

A 68-year-old man comes to the office due to increased abdominal distension. The patient was discharged from the hospital last week after an acute pulmonary embolism. He also has a history of emphysema caused by extensive tobacco use. The patient has no other medical conditions and does not use alcohol or illicit drugs. Temperature is 37.6 C (99.7 F), blood pressure is 112/78 mm Hg, pulse is 85/min, and respirations are 18/min. BMI is 27 kg/m^2. Examination shows increased jugular venous pressure and lower extremity edema. The abdomen is distended, and a fluid wave is present. This patient's ascites most likely developed due to which of the following changes in portal capillary exchange parameters?

	Portal capillary oncotic pressure	Portal capillary hydrostatic pressure	Portal capillary permeability
A.	↓	↑	↑
B.	↓	↑	Normal
C.	↑	↓	Normal
D.	Normal	↑	↑
E.	Normal	↑	Normal
F.	Normal	Normal	↑

Submit

A 68-year-old man comes to the office due to increased abdominal distension. The patient was discharged from the hospital last week after an acute pulmonary embolism. He also has a history of emphysema caused by extensive tobacco use. The patient has no other medical conditions and does not use alcohol or illicit drugs. Temperature is 37.6 C (99.7 F), blood pressure is 112/78 mm Hg, pulse is 85/min, and respirations are 18/min. BMI is 27 kg/m². Examination shows increased jugular venous pressure and lower extremity edema. The abdomen is distended, and a fluid wave is present. This patient's ascites most likely developed due to which of the following changes in portal capillary exchange parameters?

	Portal capillary oncotic pressure	Portal capillary hydrostatic pressure	Portal capillary permeability
A. (23%)	↓	↑	↑
B. (24%)	↓	↑	Normal
C. (1%)	↑	↓	Normal
D. (12%)	Normal	↑	↑
✓ E. (36%)	Normal	↑	Normal
F. (1%)	Normal	Normal	↑

Omitted
Correct answer
E

36%
Answered correctly

02 secs
Time Spent

04/11/2020
Last Updated

Ascites can develop in a variety of disease states (eg, cirrhosis, peritoneal metastasis). In this case, the presence of jugular venous distension and lower extremity edema shortly after pulmonary embolism (PE) are highly suggestive of **right-sided heart failure (RHF)** (ie, cor pulmonale) as the cause of this patient's ascites.

Patients with chronic respiratory disorders (eg, **emphysema**, obstructive sleep apnea) often have **baseline pulmonary hypertension** due to hypoxia-induced pulmonary vasoconstriction and associated vascular remodelling, which increases the pressure that the right ventricle (RV) must work against to maintain forward flow. These patients are **predisposed to RHF**, which can develop subacutely from progressive pulmonary hypertension or **acutely** in the setting of a PE (due to abrupt obstruction of an already compromised pulmonary capillary bed).

Ascites due to RHF is associated with the following findings:

- **Increased hydrostatic pressure:** RV dysfunction results in the backup of blood within the venous circulation, leading to increased central venous pressure, which is transmitted to the portal capillaries (ie, hepatic sinusoids).

- **Normal oncotic pressure:** Although passive congestion from prolonged RHF eventually causes sinusoidal injury, leading to cirrhosis and hepatic synthetic dysfunction (ie hypoalbuminemia), this alteration occurs after a prolonged period (weeks). Albumin has a half-life of approximately 21 days; therefore, early in the disease process, oncotic pressure remains normal **(Choice B)**.

- **Normal capillary permeability:** Hepatic congestion is characterized by sinusoidal engorgement, but sinusoidal permeability, which is already high at baseline due to the discontinuous sinusoidal endothelium, remains essentially unchanged.

(Choices A, D, and F) Portal capillary permeability may be increased in the setting of hepatic malignancies due to disruption of portal capillary integrity; however, it is unaffected by RHF. Portal oncotic pressure remains normal early in the disease process.

(Choice C) Both increased portal capillary oncotic pressure and decreased portal capillary hydrostatic pressure would help resolve ascites rather than contribute to its formation.

Educational objective:
Right-sided heart failure promotes the formation of ascites due to increased central venous pressure, which is transmitted to the hepatic sinusoids, leading to increased capillary hydrostatic pressure. Capillary permeability is unaffected. Although chronic passive congestion may eventually result in hepatic synthetic dysfunction (hypoalbuminemia) with low oncotic pressures, the oncotic pressure will remain normal for several weeks at

hypertension or **acutely** in the setting of a PE (due to abrupt obstruction of an already compromised pulmonary capillary bed).

Ascites due to RHF is associated with the following findings:

- **Increased hydrostatic pressure:** RV dysfunction results in the backup of blood within the venous circulation, leading to increased central venous pressure, which is transmitted to the portal capillaries (ie, hepatic sinusoids).

- **Normal oncotic pressure:** Although passive congestion from prolonged RHF eventually causes sinusoidal injury, leading to cirrhosis and hepatic synthetic dysfunction (ie hypoalbuminemia), this alteration occurs after a prolonged period (weeks). Albumin has a half-life of approximately 21 days; therefore, early in the disease process, oncotic pressure remains normal **(Choice B)**.

- **Normal capillary permeability:** Hepatic congestion is characterized by sinusoidal engorgement, but sinusoidal permeability, which is already high at baseline due to the discontinuous sinusoidal endothelium, remains essentially unchanged.

(Choices A, D, and F) Portal capillary permeability may be increased in the setting of hepatic malignancies due to disruption of portal capillary integrity; however, it is unaffected by RHF. Portal oncotic pressure remains normal early in the disease process.

(Choice C) Both increased portal capillary oncotic pressure and decreased portal capillary hydrostatic pressure would help resolve ascites rather than contribute to its formation.

Educational objective:
Right-sided heart failure promotes the formation of ascites due to increased central venous pressure, which is transmitted to the hepatic sinusoids, leading to increased capillary hydrostatic pressure. Capillary permeability is unaffected. Although chronic passive congestion may eventually result in hepatic synthetic dysfunction (hypoalbuminemia) with low oncotic pressures, the oncotic pressure will remain normal for several weeks at least.

Pathophysiology	Gastrointestinal & Nutrition	Ascites
Subject	System	Topic

Copyright © UWorld. All rights reserved.

1
2
3
4
5
6
7
8
9
10
11
12
13
14
15
16
17
18
19
20
21
22
23
24
25
26
27
28
29
30
31

A 43-year-old man comes to the office with a several-month history of fatigue, rash, flushing, and abdominal cramps. His rash is worse with rubbing or scratching, and he has diffuse itching after hot showers. The patient is frequently dizzy and light-headed after prolonged standing and had an episode of syncope while working in the hot sun. He used to be healthy and physically active but has had to reduce his normal activity. The patient does not use tobacco, alcohol, or illicit drugs. Vital signs are normal. Skin examination shows a maculopapular rash. Skin biopsy shows large clusters of mast cells that are positive for KIT (CD 117). Which of the following additional findings are most likely present in this patient?

A. Bacterial colonization of the stomach
B. Gastric atrophy
C. Gastric hypersecretion
D. Gastric hypomotility
E. Pancreatic endocrine tumor
F. Pernicious anemia

Submit

A 43-year-old man comes to the office with a several-month history of fatigue, rash, flushing, and abdominal cramps. His rash is worse with rubbing or scratching, and he has diffuse itching after hot showers. The patient is frequently dizzy and light-headed after prolonged standing and had an episode of syncope while working in the hot sun. He used to be healthy and physically active but has had to reduce his normal activity. The patient does not use tobacco, alcohol, or illicit drugs. Vital signs are normal. Skin examination shows a maculopapular rash. Skin biopsy shows large clusters of mast cells that are positive for KIT (CD 117). Which of the following additional findings are most likely present in this patient?

- A. Bacterial colonization of the stomach (3%)
- B. Gastric atrophy (8%)
- ✓ C. Gastric hypersecretion (32%)
- D. Gastric hypomotility (8%)
- E. Pancreatic endocrine tumor (33%)
- F. Pernicious anemia (14%)

Omitted
Correct answer
C

32%
Answered correctly

02 secs
Time Spent

01/29/2020
Last Updated

Explanation

Parietal cell acid secretion

Vagus nerve

1
2
3
4
5
6
7
8
9
10
11
12
13
14
15
16
17
18
19
20
21
22
23
24
25
26
27
28
29
30
31

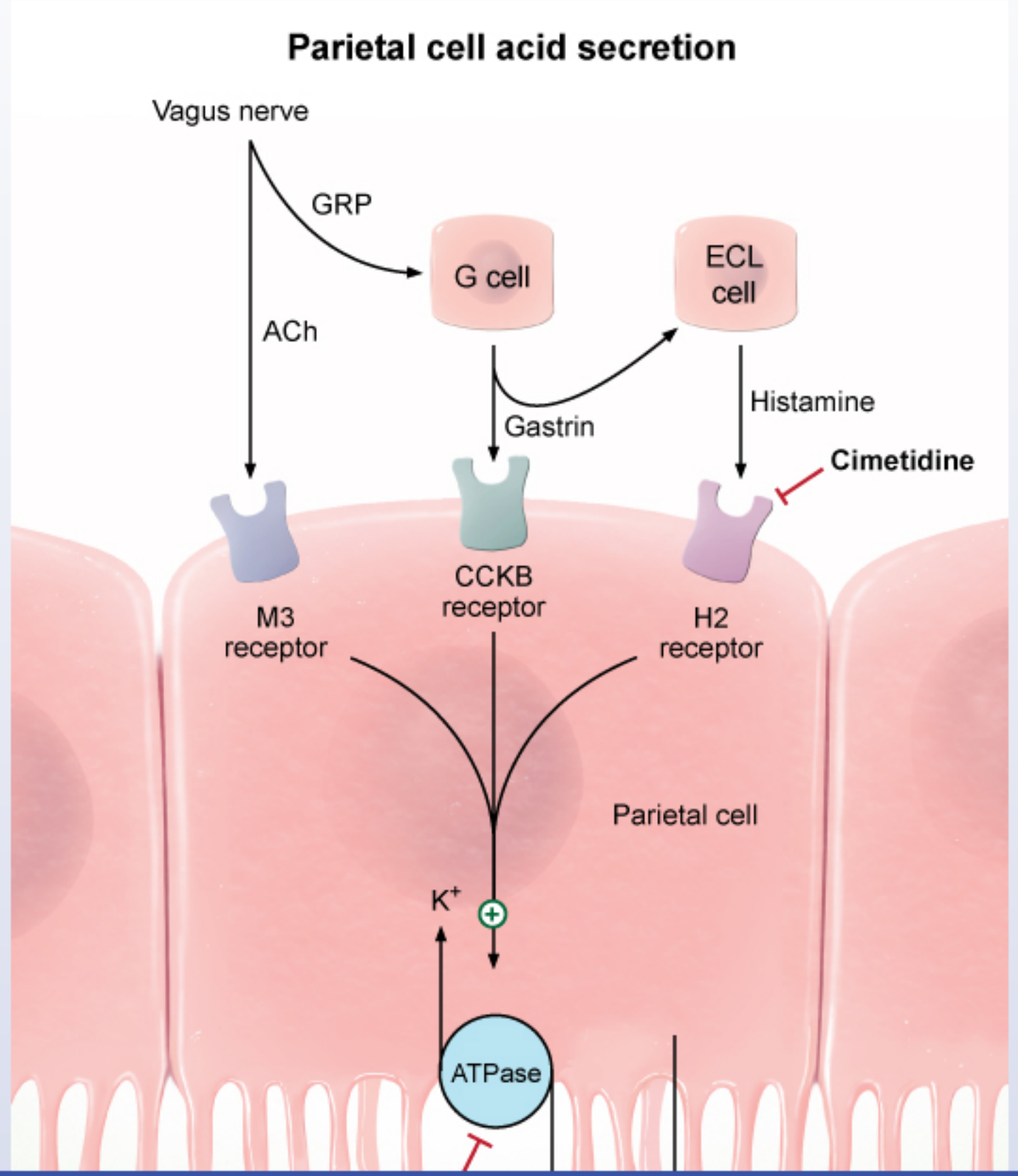

1
2
3
4
5
6
7
8
9
10
11
12
13
14
15
16
17
18
19
20
21
22
23
24
25
26
27
28
29
30
31

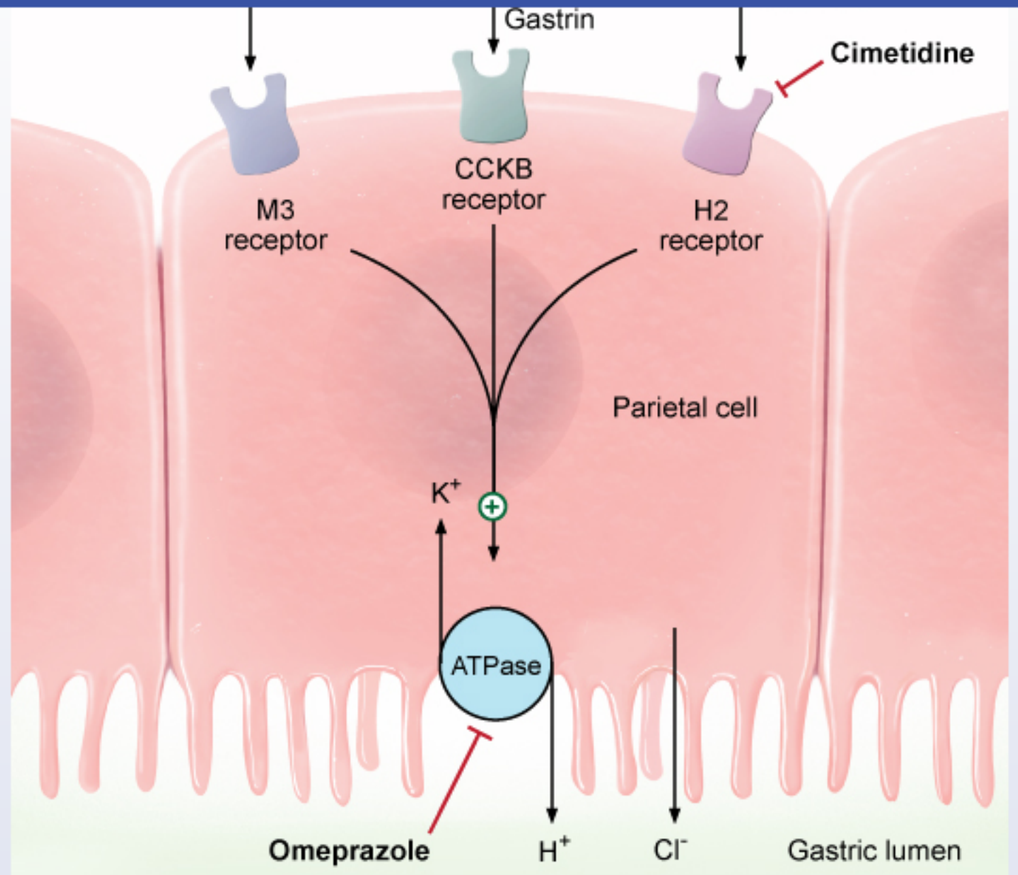

ACh = acetylcholine; **CCKB** = cholecystokinin B; **ECL** = enterochromaffin like; **GRP** = gastrin-releasing peptide; **M3** = muscarinic.
©UWorld

Gastric acid secretion by parietal cells in the fundus and body of the stomach is stimulated by:

1. **Histamine** binds H_2 receptors and increases intracellular cyclic AMP (cAMP) concentration.
2. **Acetylcholine** binds M_3 muscarinic receptors and leads to an increase in intracellular calcium.
3. **Gastrin** binds to the cholecystokinin B receptor and increases the intracellular calcium concentration. It also stimulates histamine synthesis and release by enterochromaffin-like cells in the stomach.

GRP = gastrin-releasing peptide; **M3** = muscarinic.
©UWorld

Gastric acid secretion by parietal cells in the fundus and body of the stomach is stimulated by:

1. **Histamine** binds H_2 receptors and increases intracellular cyclic AMP (cAMP) concentration.
2. **Acetylcholine** binds M_3 muscarinic receptors and leads to an increase in intracellular calcium.
3. **Gastrin** binds to the cholecystokinin B receptor and increases the intracellular calcium concentration. It also stimulates histamine synthesis and release by enterochromaffin-like cells in the stomach.

Intracellular calcium and cAMP activate protein kinases and lead to increased transport of H^+ by H^+/K^+ ATPase into the gastric lumen.

In **systemic mastocytosis**, clonal mast cell proliferation occurs in the bone marrow, skin, and other organs. Mast cell proliferation often is associated with mutations in the **KIT** receptor tyrosine kinase. These cells are characterized by prominent expression of mast cell tryptase. Excessive **histamine** release from degranulation of mast cells mediates many of the symptoms of the disease, such as syncope, flushing, hypotension, pruritus, and urticaria. In addition, histamine induces gastric acid secretion, which can lead to gastric ulceration. The excess acid also inactivates pancreatic and intestinal enzymes, causing diarrhea. Other gastrointestinal symptoms include nausea, vomiting, and abdominal cramps.

(Choices A, B, and F) Gastric mucosal atrophy often results from colonization with *Helicobacter pylori*. It can also be caused by autoimmune gastritis, which may lead to pernicious anemia due to loss of intrinsic factor from parietal cells. Symptoms of atrophic gastritis may include nausea, indigestion, and epigastric discomfort, but this patient's skin symptoms are more consistent with mastocytosis.

(Choice D) Gastric hypomotility (gastroparesis) occurs with diabetes mellitus, uremia, hypothyroidism, and other metabolic disorders. Gastroparesis causes constipation, early satiety, and food stasis with vomiting.

(Choice E) Pancreatic endocrine tumors may secrete gastrin (Zollinger-Ellison syndrome), insulin (hypoglycemia), glucagon (hyperglycemia, rash), somatostatin (diarrhea, cholelithiasis, hyperglycemia), or vasoactive intestinal peptide (watery diarrhea, hypokalemia, achlorhydria). These disorders would not be associated with excess mast cells in the skin.

Educational objective:
Systemic mastocytosis is characterized by the abnormal proliferation of mast cells and increased histamine release. Histamine causes hypersecretion of gastric acid by parietal cells in the stomach as well as a variety of other symptoms (eg, hypotension, flushing, pruritus).

Intracellular calcium and cAMP activate protein kinases and lead to increased transport of H^+ by H^+/K^+ ATPase into the gastric lumen.

In **systemic mastocytosis**, clonal mast cell proliferation occurs in the bone marrow, skin, and other organs. Mast cell proliferation often is associated with mutations in the **KIT** receptor tyrosine kinase. These cells are characterized by prominent expression of mast cell tryptase. Excessive **histamine** release from degranulation of mast cells mediates many of the symptoms of the disease, such as syncope, flushing, hypotension, pruritus, and urticaria. In addition, histamine induces gastric acid secretion, which can lead to gastric ulceration. The excess acid also inactivates pancreatic and intestinal enzymes, causing diarrhea. Other gastrointestinal symptoms include nausea, vomiting, and abdominal cramps.

(Choices A, B, and F) Gastric mucosal atrophy often results from colonization with *Helicobacter pylori*. It can also be caused by autoimmune gastritis, which may lead to pernicious anemia due to loss of intrinsic factor from parietal cells. Symptoms of atrophic gastritis may include nausea, indigestion, and epigastric discomfort, but this patient's skin symptoms are more consistent with mastocytosis.

(Choice D) Gastric hypomotility (gastroparesis) occurs with diabetes mellitus, uremia, hypothyroidism, and other metabolic disorders. Gastroparesis causes constipation, early satiety, and food stasis with vomiting.

(Choice E) Pancreatic endocrine tumors may secrete gastrin (Zollinger-Ellison syndrome), insulin (hypoglycemia), glucagon (hyperglycemia, rash), somatostatin (diarrhea, cholelithiasis, hyperglycemia), or vasoactive intestinal peptide (watery diarrhea, hypokalemia, achlorhydria). These disorders would not be associated with excess mast cells in the skin.

Educational objective:
Systemic mastocytosis is characterized by the abnormal proliferation of mast cells and increased histamine release. Histamine causes hypersecretion of gastric acid by parietal cells in the stomach as well as a variety of other symptoms (eg, hypotension, flushing, pruritus).

References

- Mastocytosis.

Pathophysiology	Gastrointestinal & Nutrition	Mastocytosis
Subject	System	Topic

Copyright © UWorld. All rights reserved.

A 53-year-old man comes to the physician due to weight loss, fatigue, and anorexia. He reports no dietary changes but has lost 6.8 kg (15 lb) in the past 2 months. Endoscopy shows an early invasive gastric cancer. The patient undergoes an uncomplicated total gastrectomy without any postoperative complications. The physician counsels the patient that he must receive lifelong administration of which of the following substances?

A. A water-soluble vitamin

B. Gastric enzymes

C. Hydrochloric acid

D. Hydrolyzed protein

E. Medium-chain triglycerides

Submit

1
2
3
4
5
6
7
8
9
10
11
12
13
14
15
16
17
18
19
20
21
22
23
24
25
26
27
28
29
30
31

A 53-year-old man comes to the physician due to weight loss, fatigue, and anorexia. He reports no dietary changes but has lost 6.8 kg (15 lb) in the past 2 months. Endoscopy shows an early invasive gastric cancer. The patient undergoes an uncomplicated total gastrectomy without any postoperative complications. The physician counsels the patient that he must receive lifelong administration of which of the following substances?

- A. A water-soluble vitamin (68%)
- B. Gastric enzymes (15%)
- C. Hydrochloric acid (4%)
- D. Hydrolyzed protein (9%)
- E. Medium-chain triglycerides (2%)

Omitted
Correct answer
A

68%
Answered correctly

02 secs
Time Spent

02/03/2020
Last Updated

Explanation

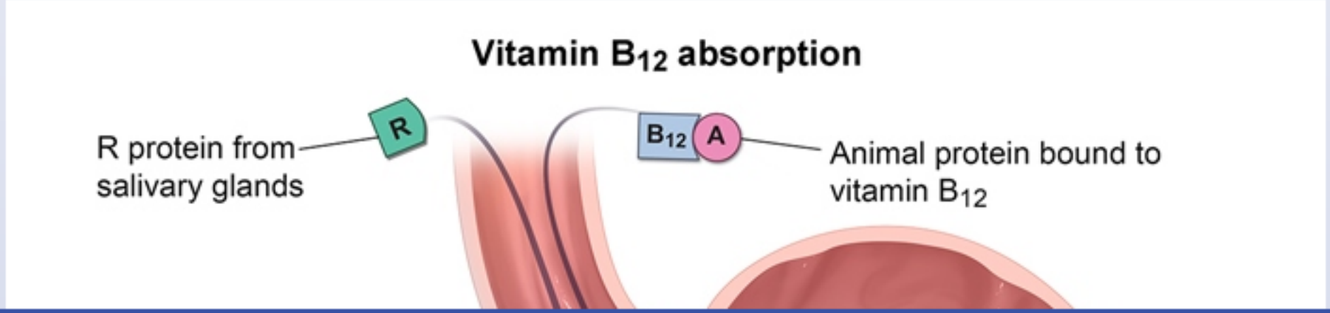

1
2
3
4
5
6
7
8
9
10
11
12
13
14
15
16
17
18
19
20
21
22
23
24
25
26
27
28
29
30
31

Vitamin B_{12} absorption

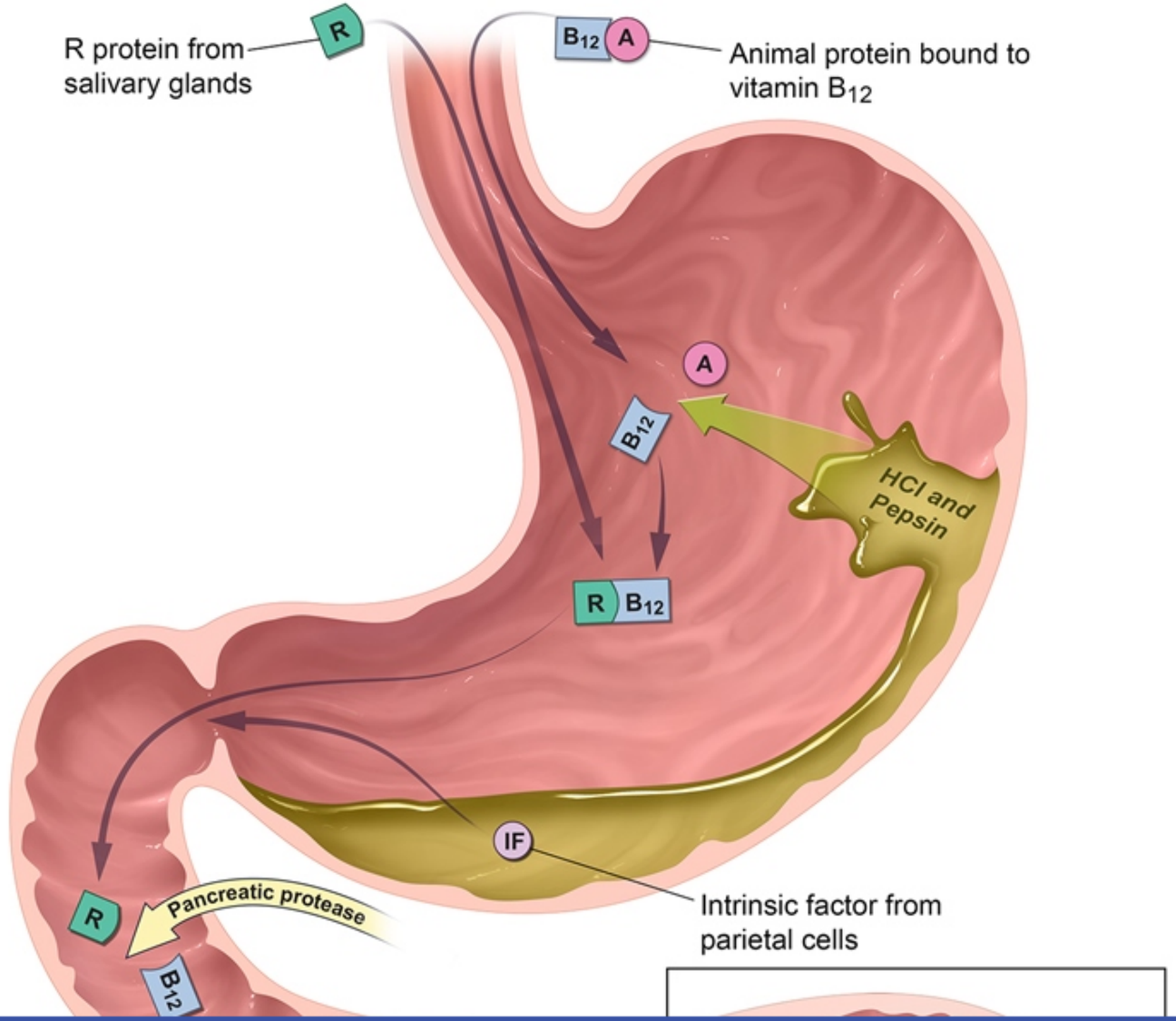

1
2
3
4
5
6
7
8
9
10
11
12
13
14
15
16
17
18
19
20
21
22
23
24
25
26
27
28
29
30
31

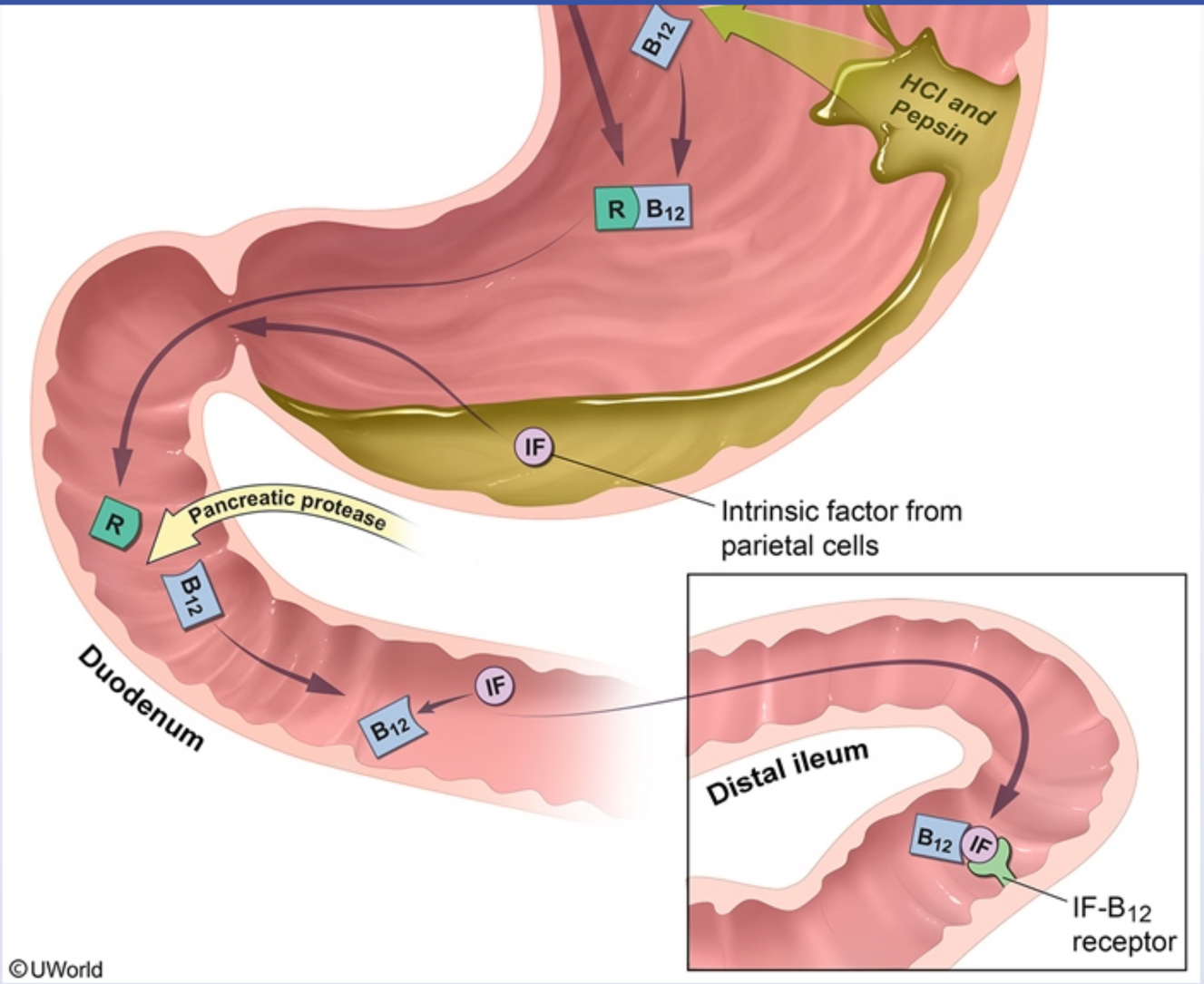

The stomach performs a number of important functions:

1. **Protein digestion** – Gastric **parietal cells** and **chief cells** produce hydrochloric acid (HCl) and pepsinogen, respectively. HCl helps to

©UWorld

The stomach performs a number of important functions:

1. **Protein digestion** – Gastric **parietal cells** and **chief cells** produce hydrochloric acid (HCl) and pepsinogen, respectively. HCl helps to denature dietary protein (improving proteolysis) and also converts pepsinogen to its active form, **pepsin**, which preferentially cleaves polypeptides at aromatic amino acid locations. Pancreatic and intestinal proteases further degrade dietary proteins into basic amino acids in the small intestine.

2. **Intrinsic factor (IF) secretion** – Parietal cells in the body and fundus of the stomach also secrete IF, a glycoprotein that normally binds to vitamin B_{12}. The **B_{12}-IF complex** is then absorbed by enterocytes in the **terminal ileum**. However, in patients who have undergone total gastrectomy, IF can no longer be produced and vitamin B_{12} cannot be effectively absorbed. Therefore, very high-dose oral or **parenteral vitamin B_{12}** becomes necessary.

3. **Gastric reservoir** – The stomach also serves as a reservoir for ingested food. This function is lost after total gastrectomy, and accelerated emptying of hyperosmolar food boluses into the small bowel results in **dumping syndrome** (characterized by colicky abdominal pain, nausea, and diarrhea). Avoidance of large meals and low dietary intake of simple sugars improves these symptoms.

(Choices B, C, and D) Pepsin and HCl are helpful, but not required, for protein digestion; patients can still digest protein after undergoing total gastrectomy due to the presence of pancreatic and intestinal proteases. It is not necessary to administer gastric enzymes, HCl, or hydrolyzed protein in these patients.

(Choice E) Medium-chain triglycerides can passively diffuse from the gastrointestinal lumen into enterocytes, but they are best absorbed after being degraded into monoglycerides and free fatty acids by lingual and pancreatic lipase. Supplementation is not necessary in total gastrectomy patients.

Educational objective:
Intrinsic factor (IF) is a glycoprotein that is normally secreted by parietal cells in the stomach and is necessary for the absorption of vitamin B_{12} in the ileum. Patients who have undergone a total gastrectomy require lifelong vitamin B_{12} supplementation due to inability to produce IF.

References

- Oral vitamin B12 replacement: an effective treatment for vitamin B12 deficiency after total gastrectomy in gastric cancer patients.

1
2
3
4
5
6
7
8
9
10
11
12
13
14
15
16
17
18
19
20
21
22
23
24
25
26
27
28
29
30
31

A 45-year-old woman diagnosed with Crohn disease 3 years ago comes to the office due to recurrent right upper quadrant abdominal pain. The pain is graded 5/10 in intensity, is characterized as dull, and occasionally radiates to the right shoulder. It typically occurs after eating fatty meals and is associated with nausea. The patient has no fever, vomiting, melena, or hematochezia. She currently takes infliximab for Crohn disease and atorvastatin for hyperlipidemia. Vital signs and abdominal examination are normal. Abdominal ultrasonography reveals multiple mobile calculi within the gallbladder. Which of the following processes is most likely responsible for the development of gallstones in this patient?

A. Gallbladder hypomobility

B. Increased bile acid wasting

C. Increased intestinal oxalate absorption

D. Medication side effect

E. Red blood cell destruction

Submit

1
2
3
4
5
6
7
8
9
10
11
12
13
14
15
16
17
18
19
20
21
22
23
24
25
26
27
28
29
30
31

A 45-year-old woman diagnosed with Crohn disease 3 years ago comes to the office due to recurrent right upper quadrant abdominal pain. The pain is graded 5/10 in intensity, is characterized as dull, and occasionally radiates to the right shoulder. It typically occurs after eating fatty meals and is associated with nausea. The patient has no fever, vomiting, melena, or hematochezia. She currently takes infliximab for Crohn disease and atorvastatin for hyperlipidemia. Vital signs and abdominal examination are normal. Abdominal ultrasonography reveals multiple mobile calculi within the gallbladder. Which of the following processes is most likely responsible for the development of gallstones in this patient?

A. Gallbladder hypomobility (18%)

✓ B. Increased bile acid wasting (45%)

C. Increased intestinal oxalate absorption (16%)

D. Medication side effect (18%)

E. Red blood cell destruction (1%)

Omitted
Correct answer
B

45%
Answered correctly

02 secs
Time Spent

02/29/2020
Last Updated

Explanation

This patient with Crohn disease most likely developed gallstones due to inflammation of the terminal ileum causing decreased bile acid reabsorption.

Bile acids are produced in the liver and excreted with bile into the duodenum. There, they **emulsify fat droplets** to form water-soluble micelles that allow pancreatic lipase to efficiently hydrolyze triglycerides into fatty acids and monoglycerides. In the jejunum, these micelles come in close

1
2
3
4
5
6
7
8
9
10
11
12
13
14
15
16
17
18
19
20
21
22
23
24
25
26
27
28
29
30
31

Pathogenesis of gallstones in Crohn disease

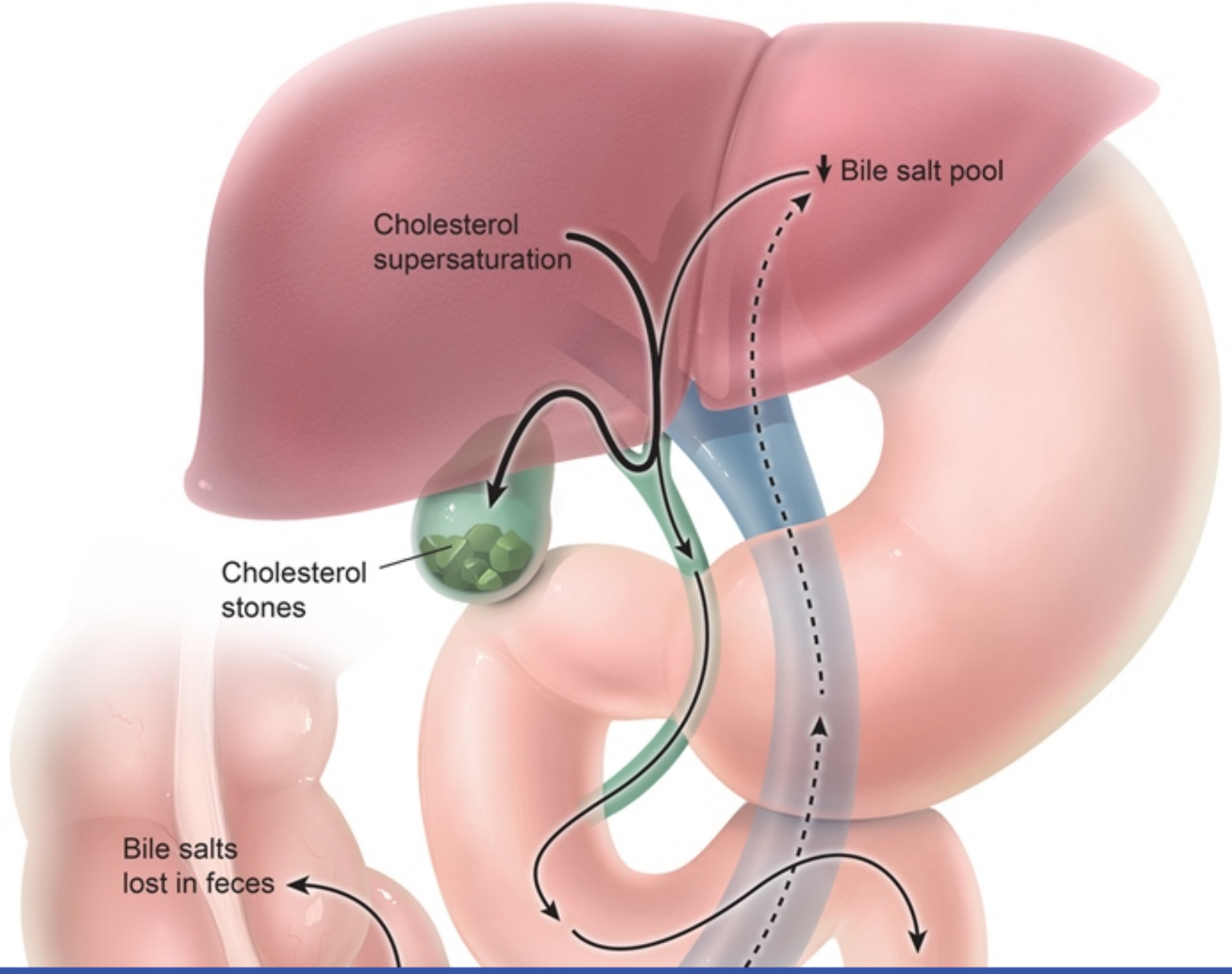

1
2
3
4
5
6
7
8
9
10
11
12
13
14
15
16
17
18
19
20
21
22
23
24
25
26
27
28
29
30
31

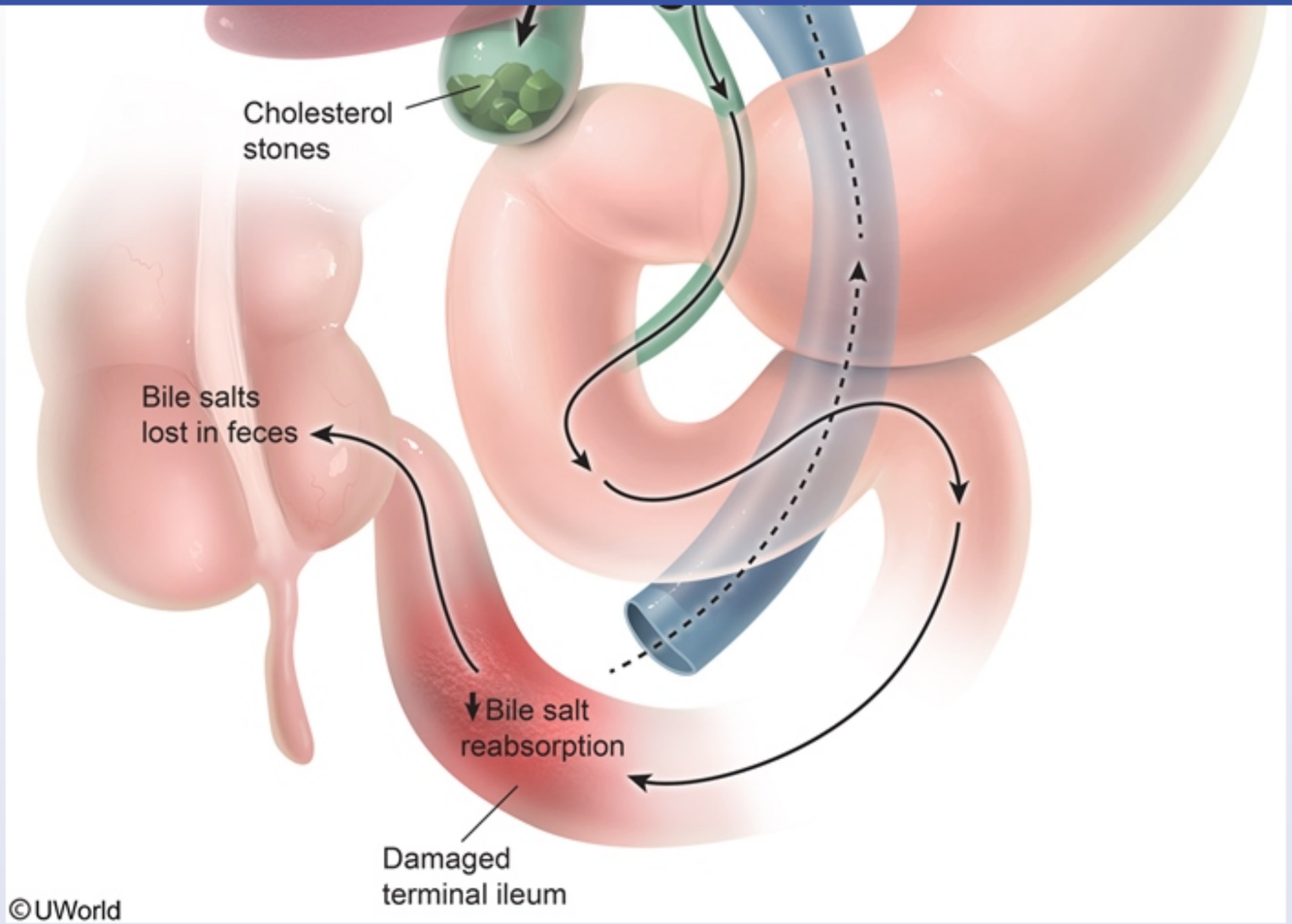

This patient with Crohn disease most likely developed gallstones due to inflammation of the terminal ileum causing decreased bile acid reabsorption.

Bile acids are produced in the liver and excreted with bile into the duodenum. There, they **emulsify fat droplets** to form water-soluble micelles that allow pancreatic lipase to efficiently hydrolyze triglycerides into fatty acids and monoglycerides. In the jejunum, these micelles come in close contact with the gut epithelium, which facilitates the passive absorption of fatty acids, monoglycerides, and cholesterol across the brush border

©UWorld

terminal ileum

This patient with Crohn disease most likely developed gallstones due to inflammation of the terminal ileum causing decreased bile acid reabsorption.

Bile acids are produced in the liver and excreted with bile into the duodenum. There, they **emulsify fat droplets** to form water-soluble micelles that allow pancreatic lipase to efficiently hydrolyze triglycerides into fatty acids and monoglycerides. In the jejunum, these micelles come in close contact with the gut epithelium, which facilitates the passive absorption of fatty acids, monoglycerides, and cholesterol across the brush border into enterocytes. However, bile acids are ionized molecules that cannot passively cross the intestinal wall. The bile acids eventually reach the **terminal ileum**, where specialized transport proteins allow them to be **reabsorbed**.

The terminal ileum is a typical location of activity in **Crohn disease**. When the mucosa of the terminal ileum is inflamed, **bile acids are lost in the feces**. As a result, a lesser amount of bile acid is present in the bile, so the ratio of cholesterol/bile acids increases. Supersaturation of the bile with cholesterol then leads to formation of **gallstones**.

(Choice A) Gallbladder hypomobility may contribute to cholesterol gallstone formation in patients with spinal cord injury or those receiving total parenteral nutrition; however, this is not observed with Crohn disease.

(Choice C) Increased intestinal oxalate absorption can contribute to calcium oxalate **kidney** stone formation in patients with Crohn disease (enteric oxaluria). However, this process is not responsible for the development of gallstones.

(Choice D) Statins inhibit the rate-limiting step of cholesterol synthesis (HMG-CoA reductase), which reduces the risk of gallstone formation. Infliximab is a tumor necrosis factor-alpha inhibitor used to treat severe or refractory Crohn disease; it is associated with an increased risk of serious infections.

(Choice E) Chronic hemolytic anemias are associated with the development of pigment gallstones due to the increased secretion of bilirubin into bile. Crohn disease can cause anemia due to nutrient deficiency (eg, vitamin B_{12}, iron) and chronic inflammation (eg, anemia of chronic disease), but it does not typically cause hemolysis.

Educational objective:
Patients with Crohn disease affecting the terminal ileum (most common site of involvement) are prone to developing gallstones. Decreased bile acid reabsorption by the inflamed terminal ileum promotes cholesterol supersaturation of the bile, resulting in gallstone formation.

1 2 3 4 5 6 7 8 9 10 11 12 13 14 15 16 17 18 19 20 21 22 23 24 25 26 27 28 29 30 31

feces. As a result, a lesser amount of bile acid is present in the bile, so the ratio of cholesterol/bile acids increases. Supersaturation of the bile with cholesterol then leads to formation of **gallstones**.

(Choice A) Gallbladder hypomobility may contribute to cholesterol gallstone formation in patients with spinal cord injury or those receiving total parenteral nutrition; however, this is not observed with Crohn disease.

(Choice C) Increased intestinal oxalate absorption can contribute to calcium oxalate **kidney** stone formation in patients with Crohn disease (enteric oxaluria). However, this process is not responsible for the development of gallstones.

(Choice D) Statins inhibit the rate-limiting step of cholesterol synthesis (HMG-CoA reductase), which reduces the risk of gallstone formation. Infliximab is a tumor necrosis factor-alpha inhibitor used to treat severe or refractory Crohn disease; it is associated with an increased risk of serious infections.

(Choice E) Chronic hemolytic anemias are associated with the development of pigment gallstones due to the increased secretion of bilirubin into bile. Crohn disease can cause anemia due to nutrient deficiency (eg, vitamin B_{12}, iron) and chronic inflammation (eg, anemia of chronic disease), but it does not typically cause hemolysis.

Educational objective:
Patients with Crohn disease affecting the terminal ileum (most common site of involvement) are prone to developing gallstones. Decreased bile acid reabsorption by the inflamed terminal ileum promotes cholesterol supersaturation of the bile, resulting in gallstone formation.

References

- Pathogenesis of gall stones in Crohn's disease: an alternative explanation.
- Gallbladder bile composition in patients with Crohn's disease.
- Enterohepatic cycling of bilirubin: a putative mechanism for pigment gallstone formation in ileal Crohn's disease.

Pathophysiology	Gastrointestinal & Nutrition	Gallstone disease
Subject	System	Topic

Copyright © UWorld. All rights reserved.

1
2
3
4
5
6
7
8
9
10
11
12
13
14
15
16
17
18
19
20
21
22
23
24
25
26
27
28
29
30
31

Biochemists identify a mutation affecting the trypsinogen molecule that disrupts a critical site on the protein involved in inhibiting the active trypsin moiety. This mutation prevents trypsin from being permanently inactivated by enzymatic cleavage. Patients with this mutation would most likely suffer from which of the following conditions?

A. Gastric cancer

B. Liver cirrhosis

C. Megaloblastic anemia

D. Pancreatitis

E. Peptic ulcer

Submit

Biochemists identify a mutation affecting the trypsinogen molecule that disrupts a critical site on the protein involved in inhibiting the active trypsin moiety. This mutation prevents trypsin from being permanently inactivated by enzymatic cleavage. Patients with this mutation would most likely suffer from which of the following conditions?

A. Gastric cancer (1%)
B. Liver cirrhosis (4%)
C. Megaloblastic anemia (4%)
✓ D. Pancreatitis (77%)
E. Peptic ulcer (11%)

Omitted
Correct answer
D

77%
Answered correctly

02 secs
Time Spent

06/26/2020
Last Updated

Explanation

Pancreatic enzymes (except amylase and lipase) are synthesized and secreted in inactive form to protect the pancreas from autodigestion. These proenzymes (zymogens) are then activated by trypsin in the duodenal lumen after trypsinogen is converted into its active form, **trypsin**, by the action of duodenal enterokinase. Trypsin can also activate other trypsinogen molecules; therefore, even small amounts of it can result in an **activation cascade**. Because of trypsin's central role in the activation of pancreatic digestive proenzymes, multiple protective mechanisms exist to limit the amount of trypsinogen that becomes prematurely activated:

- Serine peptidase inhibitor Kazal-type 1 (**SPINK1**) is secreted by pancreatic acinar cells and functions as a **trypsin inhibitor**. It impedes the activity of trypsinogen molecules that become prematurely activated within the pancreas.

Pancreatic enzymes (except amylase and lipase) are synthesized and secreted in inactive form to protect the pancreas from autodigestion. These proenzymes (zymogens) are then activated by trypsin in the duodenal lumen after trypsinogen is converted into its active form, **trypsin**, by the action of duodenal enterokinase. Trypsin can also activate other trypsinogen molecules; therefore, even small amounts of it can result in an **activation cascade**. Because of trypsin's central role in the activation of pancreatic digestive proenzymes, multiple protective mechanisms exist to limit the amount of trypsinogen that becomes prematurely activated:

- Serine peptidase inhibitor Kazal-type 1 (**SPINK1**) is secreted by pancreatic acinar cells and functions as a **trypsin inhibitor**. It impedes the activity of trypsinogen molecules that become prematurely activated within the pancreas.
- In addition to functioning as its own activator, trypsin can serve as its own inhibitor by cleaving active trypsin molecules at a second site, rendering them inactive.

Hereditary pancreatitis is a rare disorder that results from mutations involving the trypsinogen or *SPINK1* gene. The most common mutation leads to the production of **abnormal trypsin** that is not susceptible to **inactivating cleavage** by trypsin. Because a small amount of trypsinogen normally activates prematurely within the pancreatic acini and ducts, these protective mechanisms are critical for preventing recurrent attacks of acute pancreatitis.

(Choices A and E) Peptic ulcer disease and gastric adenocarcinoma are strongly associated with *Helicobacter pylori* infection.

(Choice B) Patients with mutations affecting the serum protease inhibitor, alpha-1-antitrypsin, can have emphysema and liver cirrhosis. However, there is no association between cirrhosis and trypsinogen gene mutations.

(Choice C) Megaloblastic anemia is due to deficiencies of vitamin B_{12} and folate. It is also associated with a number of drugs (eg, methotrexate, phenytoin) and certain inborn metabolic errors.

Educational objective:
Multiple inhibitory mechanisms exist to prevent premature activation of trypsinogen before it reaches the duodenal lumen, including cleavage inactivation of trypsin by trypsin itself and production of trypsin inhibitors (eg, SPINK1). Gene mutations that render trypsin insensitive to cleavage inactivation cause hereditary pancreatitis.

Pathophysiology Gastrointestinal & Nutrition Acute pancreatitis

Exhibit Display

Pancreatic enzyme activation

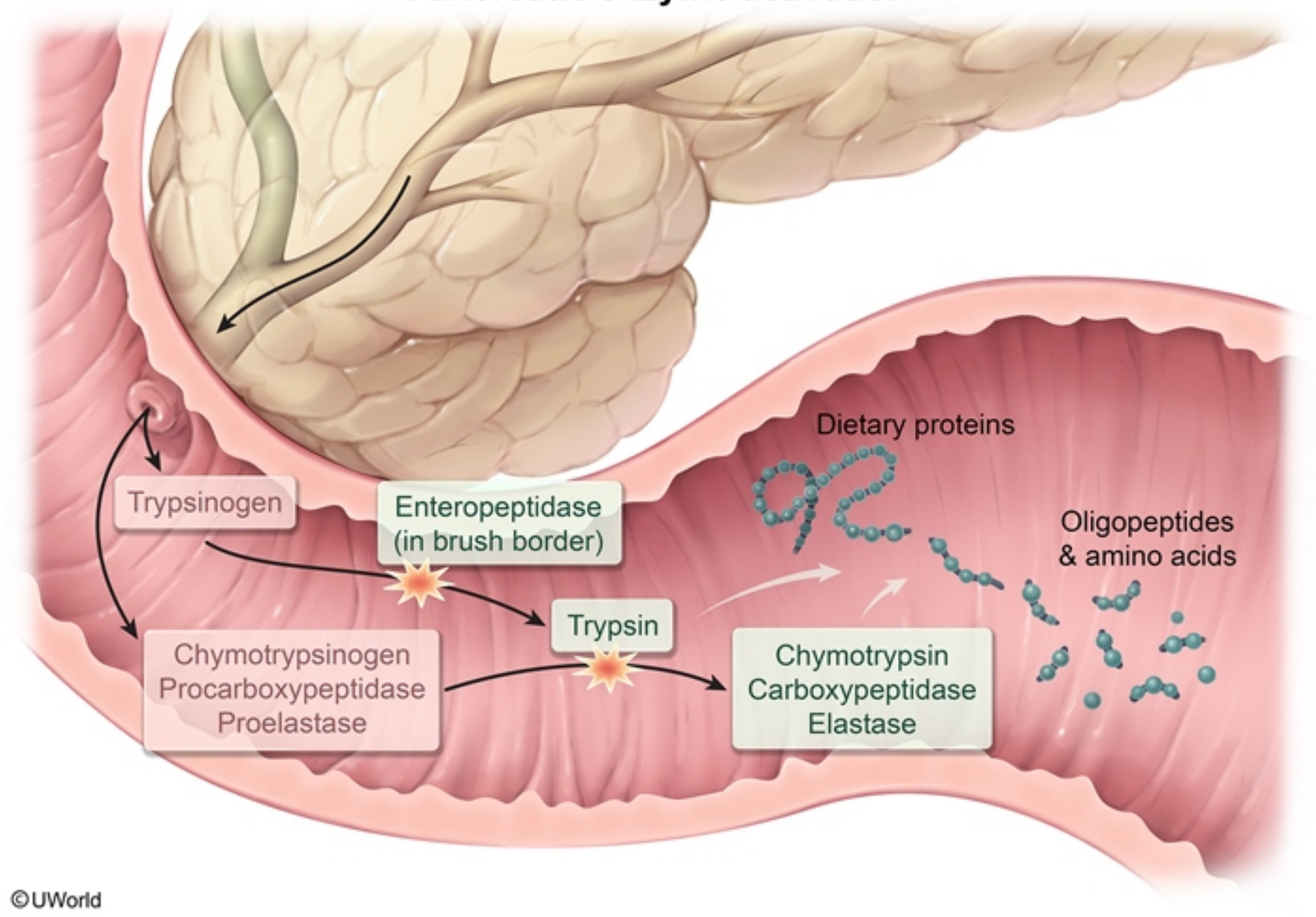

Zoom In | Zoom Out | Reset | Add To New Card | Existing Card

Pathophysiology | Gastrointestinal & Nutrition | Acute pancreatitis

action of duodenal enterokinase. Trypsin can also activate other trypsinogen molecules; therefore, even small amounts of it can result in an **activation cascade**. Because of trypsin's central role in the activation of pancreatic digestive proenzymes, multiple protective mechanisms exist to limit the amount of trypsinogen that becomes prematurely activated:

- Serine peptidase inhibitor Kazal-type 1 (**SPINK1**) is secreted by pancreatic acinar cells and functions as a **trypsin inhibitor**. It impedes the activity of trypsinogen molecules that become prematurely activated within the pancreas.
- In addition to functioning as its own activator, trypsin can serve as its own inhibitor by cleaving active trypsin molecules at a second site, rendering them inactive.

Hereditary pancreatitis is a rare disorder that results from mutations involving the trypsinogen or *SPINK1* gene. The most common mutation leads to the production of **abnormal trypsin** that is not susceptible to **inactivating cleavage** by trypsin. Because a small amount of trypsinogen normally activates prematurely within the pancreatic acini and ducts, these protective mechanisms are critical for preventing recurrent attacks of acute pancreatitis.

(Choices A and E) Peptic ulcer disease and gastric adenocarcinoma are strongly associated with *Helicobacter pylori* infection.

(Choice B) Patients with mutations affecting the serum protease inhibitor, alpha-1-antitrypsin, can have emphysema and liver cirrhosis. However, there is no association between cirrhosis and trypsinogen gene mutations.

(Choice C) Megaloblastic anemia is due to deficiencies of vitamin B_{12} and folate. It is also associated with a number of drugs (eg, methotrexate, phenytoin) and certain inborn metabolic errors.

Educational objective:
Multiple inhibitory mechanisms exist to prevent premature activation of trypsinogen before it reaches the duodenal lumen, including cleavage inactivation of trypsin by trypsin itself and production of trypsin inhibitors (eg, SPINK1). Gene mutations that render trypsin insensitive to cleavage inactivation cause hereditary pancreatitis.

Pathophysiology	Gastrointestinal & Nutrition	Acute pancreatitis
Subject	System	Topic

Copyright © UWorld. All rights reserved.

1
2
3
4
5
6
7
8
9
10
11
12
13
14
15
16
17
18
19
20
21
22
23
24
25
26
27
28
29
30
31

A 38-year-old Asian woman comes to the office as a new patient due to intermittent abdominal pain and bloating since childhood. The patient does not drink milk because she does not like the taste and adds, "Eating ice cream, cheese, or yogurt upsets my stomach sometimes." There is no associated weight loss, abnormal bleeding, or joint pain. Past medical history is otherwise unremarkable, though the patient has not seen a physician for many years. Vital signs and physical examination are normal. Laboratory studies show normal hemoglobin, iron, and vitamin D levels. The patient is referred for upper gastrointestinal endoscopy. Light microscopy of a biopsy sample of this patient's intestinal mucosa would most likely show which of the following?

A. Atrophy of the intestinal villi

B. Collections of neutrophils within crypt lumina

C. Distended macrophages in lamina propria

D. Infiltration of lamina propria with atypical lymphocytes

E. Inflammation with scattered noncaseating granulomas

F. Normal intestinal mucosa

Submit

A 38-year-old Asian woman comes to the office as a new patient due to intermittent abdominal pain and bloating since childhood. The patient does not drink milk because she does not like the taste and adds, "Eating ice cream, cheese, or yogurt upsets my stomach sometimes." There is no associated weight loss, abnormal bleeding, or joint pain. Past medical history is otherwise unremarkable, though the patient has not seen a physician for many years. Vital signs and physical examination are normal. Laboratory studies show normal hemoglobin, iron, and vitamin D levels. The patient is referred for upper gastrointestinal endoscopy. Light microscopy of a biopsy sample of this patient's intestinal mucosa would most likely show which of the following?

- A. Atrophy of the intestinal villi (11%)
- B. Collections of neutrophils within crypt lumina (1%)
- C. Distended macrophages in lamina propria (1%)
- D. Infiltration of lamina propria with atypical lymphocytes (1%)
- E. Inflammation with scattered noncaseating granulomas (0%)
- ✓ F. Normal intestinal mucosa (84%)

Omitted
Correct answer
F

84%
Answered correctly

02 secs
Time Spent

01/28/2020
Last Updated

Explanation

This patient, with gastrointestinal distress caused by consumption of lactose-containing dairy products, has typical features of lactase deficiency. Lactase deficiency results in incomplete hydrolysis of the disaccharide lactose into glucose and galactose. Undigested lactose in the bowel attracts excess water into the bowel lumen, leading to **osmotic diarrhea**. However, light and electron microscopic examinations of the bowel

This patient, with gastrointestinal distress caused by consumption of lactose-containing dairy products, has typical features of lactase deficiency. Lactase deficiency results in incomplete hydrolysis of the disaccharide lactose into glucose and galactose. Undigested lactose in the bowel attracts excess water into the bowel lumen, leading to **osmotic diarrhea**. However, light and electron microscopic examinations of the bowel mucosa in patients with primary lactase deficiency are normal.

Primary lactase deficiency can be classified as congenital or acquired. The congenital variant is a rare autosomal recessive condition. The acquired variant is more common and typically arises from decreased or ceased production of lactase by mid childhood (**lactase nonpersistence**). Acquired lactase deficiency is common in patients of Asian (up to 90%) or African ancestry and in Hispanics and Native Americans.

(Choices A and E) Secondary lactase deficiency is seen in disorders that cause injury to the gastrointestinal mucosa. Celiac disease is characterized by atrophy of the intestinal villi and is due to exposure to gluten-containing wheat products. Crohn disease causes noncaseating granulomas, and usually presents with abdominal pain and a variety of other gastrointestinal symptoms. Lactase deficiency due to these conditions is usually seen in association with other features of malabsorption (eg, iron deficiency, vitamin D deficiency).

(Choice B) Diffuse inflammatory infiltrates with neutrophilic microabscesses in the crypt lumina would be expected in patients with ulcerative colitis, which usually presents with intermittent bloody diarrhea and abdominal pain.

(Choice C) Distended macrophages in the intestinal lamina propria are a typical finding in Whipple disease, which characteristically presents with malabsorptive diarrhea, weight loss, and joint pain.

(Choice D) Infiltration of the intestinal lamina propria with atypical lymphocytes would be expected in patients with gastrointestinal MALT (mucosa-associated lymphoid tissue) lymphomas associated with chronic *Helicobacter pylori* infection of the stomach.

Educational objective:
The small bowel mucosa of patients with primary lactase deficiency is normal on histologic examination.

Pathophysiology	Gastrointestinal & Nutrition	Lactose intolerance
Subject	System	Topic

Copyright © UWorld. All rights reserved.

1
2
3
4
5
6
7
8
9
10
11
12
13
14
15
16
17
18
19
20
21
22
23
24
25
26
27
28
29
30
31

Exhibit Display

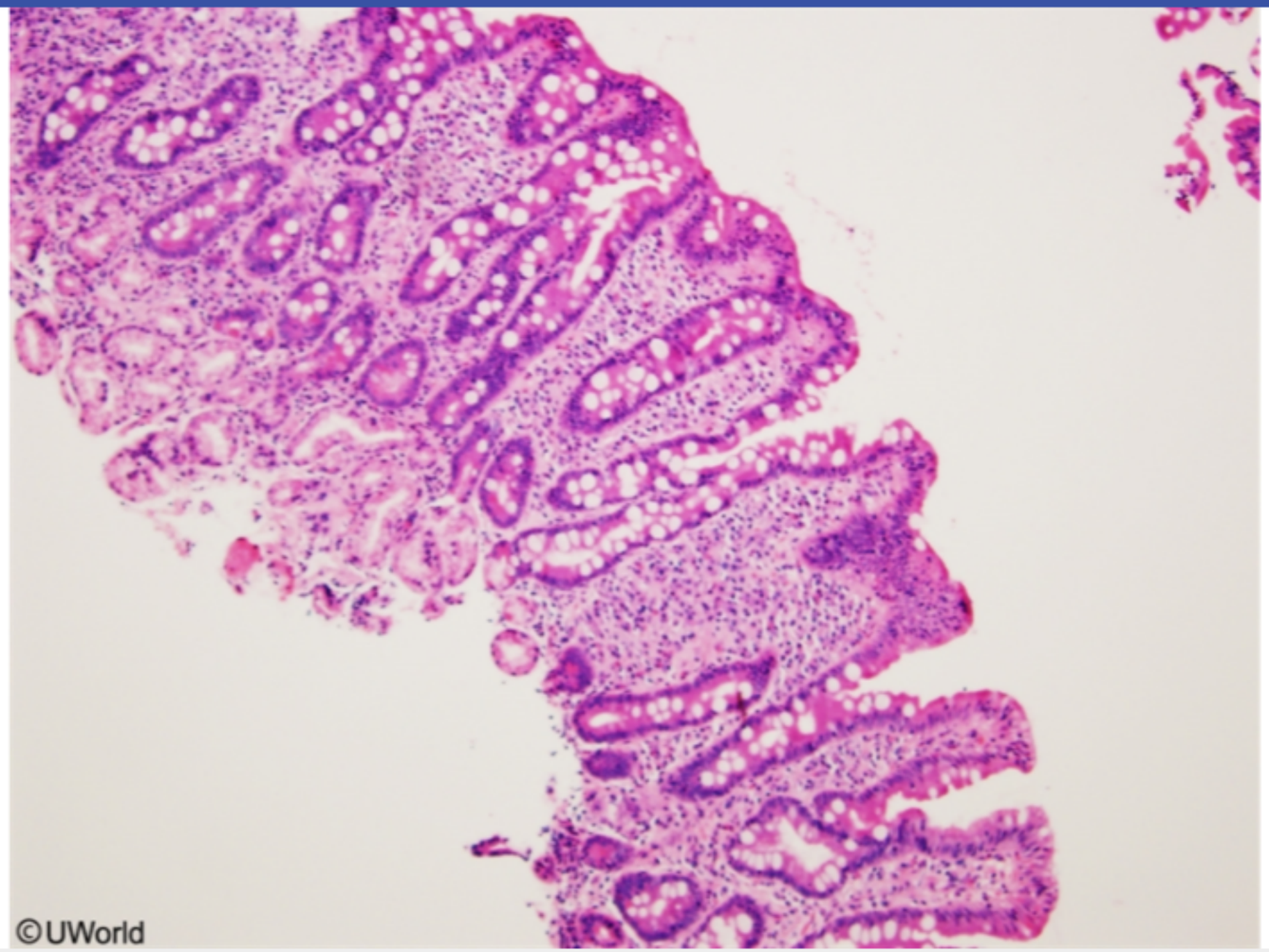

Zoom In
Zoom Out
Reset
Add To New Card | Existing Card

Copyright © UWorld. All rights reserved.

1
2
3
4
5
6
7
8
9
10
11
12
13
14
15
16
17
18
19
20
21
22
23
24
25
26
27
28
29
30
31

A 54-year-old man with a history of hepatitis C infection is brought to the emergency department by his wife after several episodes of vomiting bright red blood. He is admitted to the hospital and the appropriate treatment is initiated. During morning rounds the next day, the patient is disoriented and cannot identify the month or his current location. Physical examination shows significant abdominal distention and gynecomastia. Repetitive flicking motions of the hands are seen when the patient is asked to outstretch his arms and dorsiflex his wrists. Which of the following is most likely contributing to this patient's altered mental status?

A. Accumulation of blood urea nitrogen

B. Bacterial infection of the meninges

C. Decreased gamma-aminobutyric acid receptor stimulation

D. Increased absorption of nitrogenous substances by the gut

E. Occlusion of the middle cerebral artery

Submit

A 54-year-old man with a history of hepatitis C infection is brought to the emergency department by his wife after several episodes of vomiting bright red blood. He is admitted to the hospital and the appropriate treatment is initiated. During morning rounds the next day, the patient is disoriented and cannot identify the month or his current location. Physical examination shows significant abdominal distention and gynecomastia. Repetitive flicking motions of the hands are seen when the patient is asked to outstretch his arms and dorsiflex his wrists. Which of the following is most likely contributing to this patient's altered mental status?

- A. Accumulation of blood urea nitrogen (46%)
- B. Bacterial infection of the meninges (0%)
- C. Decreased gamma-aminobutyric acid receptor stimulation (8%)
- ✓ D. Increased absorption of nitrogenous substances by the gut (43%)
- E. Occlusion of the middle cerebral artery (0%)

Omitted
Correct answer
D

43%
Answered correctly

02 secs
Time Spent

04/05/2020
Last Updated

Explanation

Hepatic encephalopathy	
Precipitating factors	• Drugs (eg, sedatives, narcotics) • Hypovolemia (eg, diarrhea) • Electrolyte changes (eg, hypokalemia)

Hepatic encephalopathy	
Precipitating factors	• Drugs (eg, sedatives, narcotics) • Hypovolemia (eg, diarrhea) • Electrolyte changes (eg, hypokalemia) • ↑ Nitrogen load (eg, GI bleeding) • Infection (eg, pneumonia, UTI, SBP) • Portosystemic shunting (eg, TIPS)
Clinical presentation	• Sleep pattern changes • Altered mental status • Ataxia • Asterixis
Treatment	• Correct precipitating causes (eg, fluids, antibiotics) • ↓ Blood ammonia concentration (eg, lactulose, rifaximin)

GI = gastrointestinal; **SBP** = spontaneous bacterial peritonitis; **TIPS** = transjugular intrahepatic portosystemic shunt; **UTI** = urinary tract infection.

This patient with cirrhosis (hepatitis C infection, abdominal distention, gynecomastia) most likely developed **hepatic encephalopathy** due to his recent **gastrointestinal (GI) bleed**. Hepatic encephalopathy refers to a reversible decline in neurologic function that occurs due to failure of the liver to metabolize waste products such as ammonia. Ammonia is normally produced by the GI tract as a result of enterocytic catabolism of glutamine and colonic bacterial catabolism of dietary protein. GI bleeding causes **increased nitrogen delivery** to the gut in the form of hemoglobin, which is then converted into ammonia and absorbed into the bloodstream. The ammonia then enters the liver through the portal vein and is detoxified to urea.

In chronic liver failure, hepatocyte dysfunction and the shunting of blood through portosystemic collaterals impair the liver's detoxification ability. This leads to **accumulation of ammonia** and other neurotoxins in the circulation, causing altered amino acid transport across the blood-brain barrier, impaired neurotransmitter metabolism, and depressed cerebral glucose metabolism. These and other factors result in **increased inhibitory neurotransmission** (eg, γ-aminobutyric acid [GABA]) and **impaired excitatory neurotransmitter release** (eg, glutamate,

and is detoxified to urea.

In chronic liver failure, hepatocyte dysfunction and the shunting of blood through portosystemic collaterals impair the liver's detoxification ability. This leads to **accumulation of ammonia** and other neurotoxins in the circulation, causing altered amino acid transport across the blood-brain barrier, impaired neurotransmitter metabolism, and depressed cerebral glucose metabolism. These and other factors result in **increased inhibitory neurotransmission** (eg, γ-aminobutyric acid [GABA]) and **impaired excitatory neurotransmitter release** (eg, glutamate, catecholamines).

In patients with hepatic encephalopathy, lowering of blood ammonia levels is typically accomplished with oral administration of a disaccharide (eg, **lactulose**). Bacterial action on lactulose results in acidification of colonic contents, which then converts absorbable ammonia into nonabsorbable ammonium ions, trapping it in the stool and thereby increasing fecal nitrogen excretion.

(Choice A) Accumulation of blood urea nitrogen (BUN) is suggestive of renal failure, heart failure, or dehydration. In healthy patients, GI bleeding can also cause a rapid increase in BUN. However, this patient has cirrhosis, which is associated with decreased BUN because ammonia cannot be efficiently converted to urea by the failing liver.

(Choice B) Bacterial meningitis presents with altered mental status, fever, nuchal rigidity, headache, and photophobia. In addition, asterixis (flapping tremor) is specific for metabolic encephalopathies.

(Choice C) The altered mental status seen in hepatic encephalopathy is due to increased (not decreased) activity of the GABA neurotransmitter system. This enhanced activity is caused by increased GABA receptor affinity and alterations in neurosteroid synthesis rather than increased GABA production.

(Choice E) The middle cerebral artery is the largest cerebral artery and the one most commonly involved in cerebrovascular accidents. This patient's presentation is suggestive of hepatic encephalopathy rather than stroke.

Educational objective:
Hepatic encephalopathy is caused by increased levels of ammonia and other neurotoxins in the circulation that lead to increased inhibitory neurotransmission and impaired excitatory neurotransmitter release. Hepatic encephalopathy is frequently precipitated by a stressor (eg, gastrointestinal bleeding, infection) that increases blood ammonia levels.

References

- Ammonia, the GABA neurotransmitter system, and hepatic encephalopathy

1
2
3
4
5
6
7
8
9
10
11
12
13
14
15
16
17
18
19
20
21
22
23
24
25
26
27
28
29
30
31

lactulose). Bacterial action on lactulose results in acidification of colonic contents, which then converts absorbable ammonia into nonabsorbable ammonium ions, trapping it in the stool and thereby increasing fecal nitrogen excretion.

(Choice A) Accumulation of blood urea nitrogen (BUN) is suggestive of renal failure, heart failure, or dehydration. In healthy patients, GI bleeding can also cause a rapid increase in BUN. However, this patient has cirrhosis, which is associated with decreased BUN because ammonia cannot be efficiently converted to urea by the failing liver.

(Choice B) Bacterial meningitis presents with altered mental status, fever, nuchal rigidity, headache, and photophobia. In addition, asterixis (flapping tremor) is specific for metabolic encephalopathies.

(Choice C) The altered mental status seen in hepatic encephalopathy is due to increased (not decreased) activity of the GABA neurotransmitter system. This enhanced activity is caused by increased GABA receptor affinity and alterations in neurosteroid synthesis rather than increased GABA production.

(Choice E) The middle cerebral artery is the largest cerebral artery and the one most commonly involved in cerebrovascular accidents. This patient's presentation is suggestive of hepatic encephalopathy rather than stroke.

Educational objective:
Hepatic encephalopathy is caused by increased levels of ammonia and other neurotoxins in the circulation that lead to increased inhibitory neurotransmission and impaired excitatory neurotransmitter release. Hepatic encephalopathy is frequently precipitated by a stressor (eg, gastrointestinal bleeding, infection) that increases blood ammonia levels.

References

- Ammonia, the GABA neurotransmitter system, and hepatic encephalopathy
- Hepatic encephalopathy: a review of its pathophysiology and treatment

Pathophysiology	Gastrointestinal & Nutrition	Hepatic Encephalopathy
Subject	System	Topic

Copyright © UWorld. All rights reserved.

1
2
3
4
5
6
7
8
9
10
11
12
13
14
15
16
17
18
19
20
21
22
23
24
25
26
27
28
29
30
31

lactulose). Bacterial action on lactulose results in acidification of colonic contents, which then converts absorbable ammonia into nonabsorbable ammonium ions, trapping it in the stool and thereby increasing fecal nitrogen excretion.

(Choice A) Accumulation of blood urea nitrogen (BUN) is suggestive of renal failure, heart failure, or dehydration. In healthy patients, GI bleeding can also cause a rapid increase in BUN. However, this patient has cirrhosis, which is associated with decreased BUN because ammonia cannot be efficiently converted to urea by the failing liver.

(Choice B) Bacterial meningitis presents with altered mental status, fever, nuchal rigidity, headache, and photophobia. In addition, asterixis (flapping tremor) is specific for metabolic encephalopathies.

(Choice C) The altered mental status seen in hepatic encephalopathy is due to increased (not decreased) activity of the GABA neurotransmitter system. This enhanced activity is caused by increased GABA receptor affinity and alterations in neurosteroid synthesis rather than increased GABA production.

(Choice E) The middle cerebral artery is the largest cerebral artery and the one most commonly involved in cerebrovascular accidents. This patient's presentation is suggestive of hepatic encephalopathy rather than stroke.

Educational objective:
Hepatic encephalopathy is caused by increased levels of ammonia and other neurotoxins in the circulation that lead to increased inhibitory neurotransmission and impaired excitatory neurotransmitter release. Hepatic encephalopathy is frequently precipitated by a stressor (eg, gastrointestinal bleeding, infection) that increases blood ammonia levels.

References

- Ammonia, the GABA neurotransmitter system, and hepatic encephalopathy
- Hepatic encephalopathy: a review of its pathophysiology and treatment

Pathophysiology	Gastrointestinal & Nutrition	Hepatic Encephalopathy
Subject	System	Topic

Copyright © UWorld. All rights reserved.

1
2
3
4
5
6
7
8
9
10
11
12
13
14
15
16
17
18
19
20
21
22
23
24
25
26
27
28
29
30
31

A 4-week-old boy is brought to the office for a routine well-baby visit. The boy has been exclusively breastfeeding every 2-3 hours and is making 6 or 7 wet diapers a day. His urine has appeared dark yellow, and he has had a few pale-colored stools. His parents also noticed that his skin has appeared yellow for the past 2 weeks, but they were not concerned as they heard from friends that yellow skin is common with breastfeeding. The patient was born full term without complications by vaginal delivery to a primigravida. On physical examination, he is well-appearing with icteric sclerae and jaundice of the head and upper chest. Abdominal examination reveals a mildly enlarged and firm liver. Liver function results are as follows:

Total bilirubin	7.3 mg/dL
Direct bilirubin	5 mg/dL

Which of the following is the most likely mechanism for the patient's presentation?

A. Extrahepatic obstruction of bile ducts
B. Genetic mutation causing reduced glucuronidation
C. Impaired galactose metabolism
D. Increased enterohepatic circulation of bilirubin
E. Maternal antibody-mediated red blood cell destruction

Submit

A 4-week-old boy is brought to the office for a routine well-baby visit. The boy has been exclusively breastfeeding every 2-3 hours and is making 6 or 7 wet diapers a day. His urine has appeared dark yellow, and he has had a few pale-colored stools. His parents also noticed that his skin has appeared yellow for the past 2 weeks, but they were not concerned as they heard from friends that yellow skin is common with breastfeeding. The patient was born full term without complications by vaginal delivery to a primigravida. On physical examination, he is well-appearing with icteric sclerae and jaundice of the head and upper chest. Abdominal examination reveals a mildly enlarged and firm liver. Liver function results are as follows:

Total bilirubin	7.3 mg/dL
Direct bilirubin	5 mg/dL

Which of the following is the most likely mechanism for the patient's presentation?

- ✓ A. Extrahepatic obstruction of bile ducts (62%)
- B. Genetic mutation causing reduced glucuronidation (20%)
- C. Impaired galactose metabolism (3%)
- D. Increased enterohepatic circulation of bilirubin (9%)
- E. Maternal antibody-mediated red blood cell destruction (3%)

Omitted
Correct answer
A

62%
Answered correctly

02 secs
Time Spent

03/08/2020
Last Updated

Explanation

1
2
3
4
5
6
7
8
9
10
11
12
13
14
15
16
17
18
19
20
21
22
23
24
25
26
27
28
29
30
31

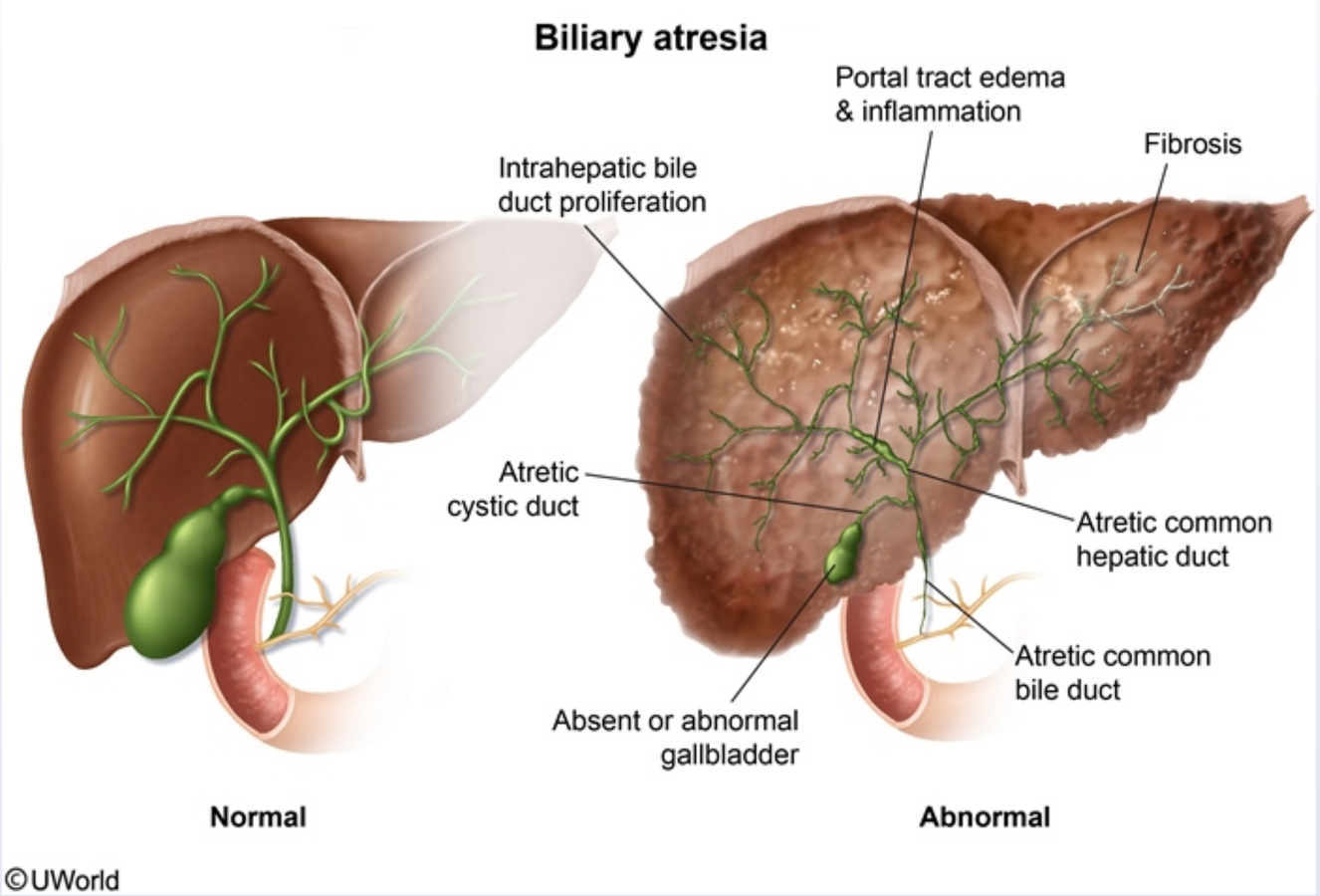

Biliary atresia is a progressive, complete or partial **obstruction** of **extrahepatic bile ducts**. The biliary tree is normal at birth and subsequently undergoes destruction that is thought to be immune-related or viral-induced. Infants may appear healthy at birth, but then present with **jaundice** within the first 2 months of life, along with **dark urine** and **acholic** (pale or clay-colored) **stools** due to excessive renal excretion of bilirubin and lack of intestinal bile, respectively. Physical examination may also reveal firm hepatomegaly due to inflammation. Laboratory findings, including **elevated direct bilirubin** and gamma-glutamyl transferase, are consistent with cholestasis.

1
2
3
4
5
6
7
8
9
10
11
12
13
14
15
16
17
18
19
20
21
22
23
24
25
26
27
28
29
30
31

Liver biopsy is usually diagnostic and reveals intrahepatic bile duct proliferation, portal tract edema, and fibrosis. Urgent surgical intervention is required, as lack of intervention can lead to death (due to cirrhosis) usually within 2 years.

(Choice B) Gilbert syndrome is an inherited, benign condition of reduced production of glucuronyl transferase, a hepatic enzyme responsible for glucuronidation (ie, conversion of bilirubin to its excretable form). Patients are usually asymptomatic except at times of stress (eg, fasting, illness) during which mild, indirect hyperbilirubinemia and jaundice are present.

(Choice C) Galactosemia (galactose-1-phosphate uridyl transferase [GALT] deficiency) is characterized by defective metabolism of galactose, a breakdown product of lactose that is then normally metabolized to glucose. Both direct and indirect bilirubin levels may be elevated. However, infants would present with vomiting, diarrhea, and lethargy during the first few days of life due to inability to digest breast milk or formula.

(Choice D) Breast milk jaundice causes an indirect hyperbilirubinemia that peaks at age 2 weeks. The pathogenesis likely involves an enzyme, beta-glucuronidase, in breast milk that deconjugates bilirubin. This causes increased absorption and, therefore, increased enterohepatic circulation of bilirubin. Urine and stool appearance are unaffected.

(Choice E) Hemolytic disease of the newborn can result from Rh incompatibility (eg, Rh-positive infant and Rh-negative mother) or ABO incompatibility (eg, A+ infant and O+ mother). Patients develop jaundice on the first day of life due to indirect hyperbilirubinemia, and a positive direct Coombs (antiglobulin) test confirms the presence of antibody-mediated hemolysis.

Educational objective:
Biliary atresia, or obstruction of extrahepatic bile ducts, presents with jaundice, dark urine, and acholic stools in the first 2 months of life due to conjugated hyperbilirubinemia. Biopsy reveals intrahepatic bile duct proliferation, portal tract edema, and fibrosis.

References

- Biliary atresia.
- Pathogenesis of biliary atresia: defining biology to understand clinical phenotypes.

Pathophysiology	Gastrointestinal & Nutrition	Biliary atresia
Subject	System	Topic

Copyright © UWorld. All rights reserved.

Liver biopsy is usually diagnostic and reveals intrahepatic bile duct proliferation, portal tract edema, and fibrosis. Urgent surgical intervention is

Exhibit Display

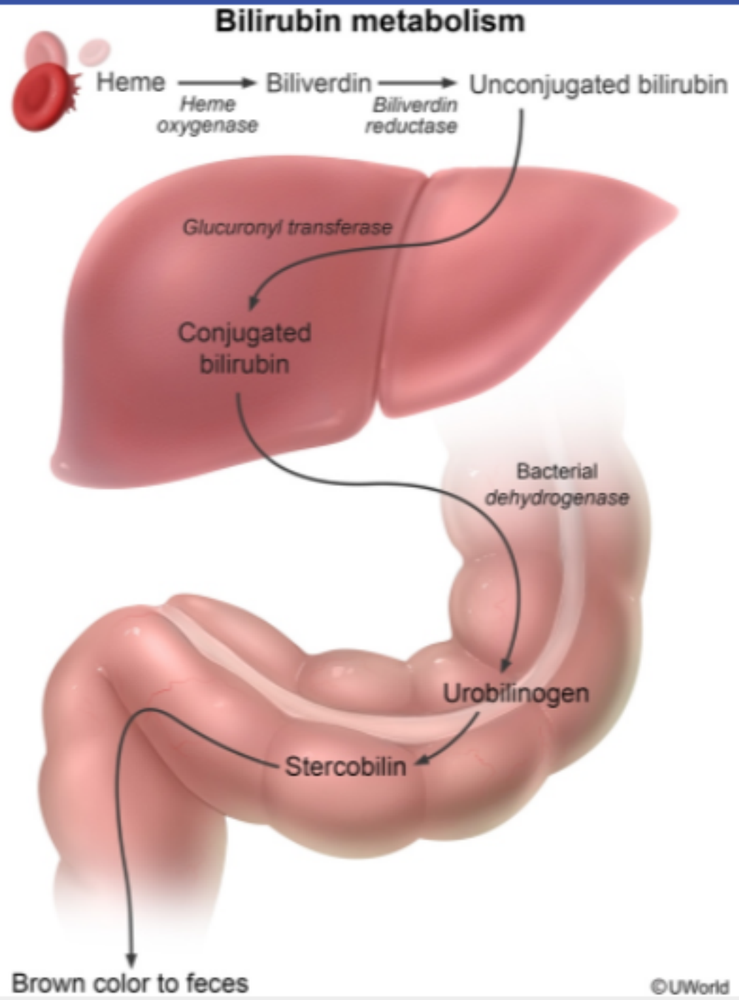

Zoom In | Zoom Out | Reset | Add To New Card | Existing Card

Copyright © UWorld. All rights reserved.

1
2
3
4
5
6
7
8
9
10
11
12
13
14
15
16
17
18
19
20
21
22
23
24
25
26
27
28
29
30
31

A 62-year-old woman comes to the office for diarrhea. She has had 4 or 5 watery, brown stools every day for the past 6 months. Although most episodes occur during the day, she wakes up at least once a night to defecate. There is no associated hematochezia, melena, vomiting, or unexpected weight loss. Medical history is significant for type 2 diabetes mellitus and hypertension. She takes lisinopril, insulin, and metformin. She has no recent travel or new medications. Family history is unremarkable. She does not drink alcohol. Temperature is 37.4 C (99.3 F), blood pressure is 125/80 mm Hg, and pulse is 80/min. The abdomen is nontender and nondistended. Complete blood count, serum chemistries, and stool studies are normal. Which of the following is the most likely cause of this patient's diarrhea?

A. Decreased bacterial growth in the colon

B. Disaccharidase deficiency

C. Disordered motility of the small bowel and colon

D. Exocrine pancreatic insufficiency

E. Transmural intestinal inflammation

Submit

A 62-year-old woman comes to the office for diarrhea. She has had 4 or 5 watery, brown stools every day for the past 6 months. Although most episodes occur during the day, she wakes up at least once a night to defecate. There is no associated hematochezia, melena, vomiting, or unexpected weight loss. Medical history is significant for type 2 diabetes mellitus and hypertension. She takes lisinopril, insulin, and metformin. She has no recent travel or new medications. Family history is unremarkable. She does not drink alcohol. Temperature is 37.4 C (99.3 F), blood pressure is 125/80 mm Hg, and pulse is 80/min. The abdomen is nontender and nondistended. Complete blood count, serum chemistries, and stool studies are normal. Which of the following is the most likely cause of this patient's diarrhea?

- A. Decreased bacterial growth in the colon (7%)
- B. Disaccharidase deficiency (14%)
- ✓ C. Disordered motility of the small bowel and colon (55%)
- D. Exocrine pancreatic insufficiency (15%)
- E. Transmural intestinal inflammation (6%)

Omitted
Correct answer
C

55%
Answered correctly

03 secs
Time Spent

06/25/2020
Last Updated

Explanation

Diabetic diarrhea	
Etiology	• Long-standing hyperglycemia damages the autonomic nervous system, resulting in: ◦ Altered intestinal motility

Diabetic diarrhea	
Etiology	• Long-standing hyperglycemia damages the autonomic nervous system, resulting in: ◦ Altered intestinal motility ◦ Increased intestinal secretions ◦ ± Fecal incontinence
Risk factors	• Poorly controlled diabetes mellitus • Vascular risk factors (eg, smoking, obesity, hyperlipidemia)
Manifestations	• Painless, watery diarrhea • Secretory-like (persists at night & while fasting) • Laboratory evaluation typically unremarkable

This patient with diabetes mellitus has several months of watery diarrhea that occurs both during the day and at night. In the setting of normal laboratory evaluation, this presentation suggests **diabetic diarrhea** due to **diabetic autonomic neuropathy** (DAN). Long-standing hyperglycemia results in the accumulation of cross-linked glycosylated serum proteins in the vasa nervorum, which causes inflammation and **damage to peripheral nerves**. Although this most commonly results in a distal, symmetric polyneuropathy of the feet, it can also result in damage to **sympathetic and parasympathetic nerves**, leading to autonomic dysfunction. Risk factors include poor glucose control and other vascular risk factors (eg, hypertension, obesity).

Loss of autonomic input to the gastrointestinal tract results in abnormal peristalsis, leading to **disordered small-bowel and colonic motility**, which can result in rapid intestinal transport. Furthermore, intestinal water and electrolyte secretion is increased. **Fecal incontinence** is particularly common in patients with long-standing diabetes, resulting from both a large volume of watery diarrhea and decreased anorectal sensation. Other common gastrointestinal manifestations of DAN include gastroparesis and gastroesophageal reflux.

Patients with diabetic diarrhea typically have painless, secretory-like diarrhea that **persists with fasting** (eg, nocturnal diarrhea). Laboratory evaluation, including fecal leukocytes and fecal occult blood testing, is usually unremarkable.

(Choice A) Although altered small-bowel motility related to DAN can predispose to small intestinal bacterial overgrowth, this occurs due to an

This patient with diabetes mellitus has several months of watery diarrhea that occurs both during the day and at night. In the setting of normal laboratory evaluation, this presentation suggests **diabetic diarrhea** due to **diabetic autonomic neuropathy** (DAN). Long-standing hyperglycemia results in the accumulation of cross-linked glycosylated serum proteins in the vasa nervorum, which causes inflammation and **damage to peripheral nerves**. Although this most commonly results in a distal, symmetric polyneuropathy of the feet, it can also result in damage to **sympathetic and parasympathetic nerves**, leading to autonomic dysfunction. Risk factors include poor glucose control and other vascular risk factors (eg, hypertension, obesity).

Loss of autonomic input to the gastrointestinal tract results in abnormal peristalsis, leading to **disordered small-bowel and colonic motility**, which can result in rapid intestinal transport. Furthermore, intestinal water and electrolyte secretion is increased. **Fecal incontinence** is particularly common in patients with long-standing diabetes, resulting from both a large volume of watery diarrhea and decreased anorectal sensation. Other common gastrointestinal manifestations of DAN include gastroparesis and gastroesophageal reflux.

Patients with diabetic diarrhea typically have painless, secretory-like diarrhea that **persists with fasting** (eg, nocturnal diarrhea). Laboratory evaluation, including fecal leukocytes and fecal occult blood testing, is usually unremarkable.

(Choice A) Although altered small-bowel motility related to DAN can predispose to small intestinal bacterial overgrowth, this occurs due to an increase in small bowel bacteria, not a decrease in colonic bacterial burden. It typically causes abdominal bloating, discomfort, and gas. Nocturnal diarrhea is unexpected.

(Choice B) Lactase deficiency can cause osmotic diarrhea after lactose ingestion, leading to postprandial loose stools and bloating. However, unless patients are eating during the night, nocturnal bowel movements would not occur.

(Choice D) Exocrine pancreatic insufficiency (EPI), which is common in chronic pancreatitis or after pancreatic resection, leads to bulky, foul-smelling stool (eg, steatorrhea). Although insulin resistance can mildly impact pancreatic secretions, EPI leading to steatorrhea is rare in diabetes.

(Choice E) Crohn disease, which causes transmural gastrointestinal inflammation, can cause watery diarrhea. However, abdominal pain, anemia, abnormal stool studies (eg, fecal occult blood, fecal calprotectin), and possibly fever are expected.

Educational objective:
Prolonged hyperglycemia in diabetes mellitus can injure the parasympathetic and sympathetic nervous system, resulting in diabetic autonomic neuropathy. This can lead to disordered small-bowel and colonic motility and increased intestinal secretions, resulting in secretory-like diarrhea (eg, fasting bowel movements).

vascular risk factors (eg, hypertension, obesity).

Loss of autonomic input to the gastrointestinal tract results in abnormal peristalsis, leading to **disordered small-bowel and colonic motility**, which can result in rapid intestinal transport. Furthermore, intestinal water and electrolyte secretion is increased. **Fecal incontinence** is particularly common in patients with long-standing diabetes, resulting from both a large volume of watery diarrhea and decreased anorectal sensation. Other common gastrointestinal manifestations of DAN include gastroparesis and gastroesophageal reflux.

Patients with diabetic diarrhea typically have painless, secretory-like diarrhea that **persists with fasting** (eg, nocturnal diarrhea). Laboratory evaluation, including fecal leukocytes and fecal occult blood testing, is usually unremarkable.

(Choice A) Although altered small-bowel motility related to DAN can predispose to small intestinal bacterial overgrowth, this occurs due to an increase in small bowel bacteria, not a decrease in colonic bacterial burden. It typically causes abdominal bloating, discomfort, and gas. Nocturnal diarrhea is unexpected.

(Choice B) Lactase deficiency can cause osmotic diarrhea after lactose ingestion, leading to postprandial loose stools and bloating. However, unless patients are eating during the night, nocturnal bowel movements would not occur.

(Choice D) Exocrine pancreatic insufficiency (EPI), which is common in chronic pancreatitis or after pancreatic resection, leads to bulky, foul-smelling stool (eg, steatorrhea). Although insulin resistance can mildly impact pancreatic secretions, EPI leading to steatorrhea is rare in diabetes.

(Choice E) Crohn disease, which causes transmural gastrointestinal inflammation, can cause watery diarrhea. However, abdominal pain, anemia, abnormal stool studies (eg, fecal occult blood, fecal calprotectin), and possibly fever are expected.

Educational objective:
Prolonged hyperglycemia in diabetes mellitus can injure the parasympathetic and sympathetic nervous system, resulting in diabetic autonomic neuropathy. This can lead to disordered small-bowel and colonic motility and increased intestinal secretions, resulting in secretory-like diarrhea (eg, fasting bowel movements).

Pathophysiology	Gastrointestinal & Nutrition	Diabetic neuropathy
Subject	System	Topic

Copyright © UWorld. All rights reserved.

1
2
3
4
5
6
7
8
9
10
11
12
13
14
15
16
17
18
19
20
21
22
23
24
25
26
27
28
29
30
31

A 34-year-old man is evaluated in the clinic due to easy bruising. The patient says that even minor trauma causes a bruise and that he sometimes has spontaneous bruising over his legs. He has also been experiencing generalized fatigue, poor appetite, and dull pain and stiffness in his lower back and joints at night. The patient has a history of Crohn disease that required a partial bowel resection a year ago. Three months ago, he was treated with oral antibiotics for a perianal fistula. His mother died of colon cancer when she was 56. Physical examination shows several large ecchymoses on his lower extremities. Which of the following is the most likely diagnosis?

A. Autoimmune hepatitis

B. Bile acid malabsorption

C. Factor VIII deficiency

D. Immune thrombocytopenic purpura

E. Leukocytoclastic vasculitis

Submit

A 34-year-old man is evaluated in the clinic due to easy bruising. The patient says that even minor trauma causes a bruise and that he sometimes has spontaneous bruising over his legs. He has also been experiencing generalized fatigue, poor appetite, and dull pain and stiffness in his lower back and joints at night. The patient has a history of Crohn disease that required a partial bowel resection a year ago. Three months ago, he was treated with oral antibiotics for a perianal fistula. His mother died of colon cancer when she was 56. Physical examination shows several large ecchymoses on his lower extremities. Which of the following is the most likely diagnosis?

- A. Autoimmune hepatitis (7%)
- ✓ B. Bile acid malabsorption (30%)
- C. Factor VIII deficiency (13%)
- D. Immune thrombocytopenic purpura (38%)
- E. Leukocytoclastic vasculitis (8%)

Omitted
Correct answer
B

30%
Answered correctly

02 secs
Time Spent

05/21/2020
Last Updated

Explanation

Crohn disease typically presents with prolonged diarrhea and abdominal pain. Transmural inflammation of the bowel wall may result in the formation of fistulas, abscesses, and fibrotic strictures. Extraintestinal manifestations can include ankylosing spondylitis and peripheral arthritis, which often manifest with low back pain and joint stiffness that is worse at night. Constitutional symptoms (eg, low-grade fever, fatigue), malabsorption, and weight loss are also common.

The **terminal ileum** is frequently involved in Crohn disease. Bile acids, which are necessary for the absorption of fat and other nutrients, are

Crohn disease typically presents with prolonged diarrhea and abdominal pain. Transmural inflammation of the bowel wall may result in the formation of fistulas, abscesses, and fibrotic strictures. Extraintestinal manifestations can include ankylosing spondylitis and peripheral arthritis, which often manifest with low back pain and joint stiffness that is worse at night. Constitutional symptoms (eg, low-grade fever, fatigue), malabsorption, and weight loss are also common.

The **terminal ileum** is frequently involved in Crohn disease. Bile acids, which are necessary for the absorption of fat and other nutrients, are normally reabsorbed in the terminal ileum, recycled in the liver, and then reused in the absorptive process. When the terminal ileum is inflamed or resected, bile acids are lost with feces. **Loss of bile acids** causes **fat malabsorption**, which may lead to deficiencies in fat-soluble vitamins (A, D, E, K).

Vitamin K is a cofactor for several carboxylase enzymes that are necessary for coagulation factor II, VII, IX, and X activation. Coagulation disorders such as **vitamin K deficiency** typically result in easy bruising, large hematoma formation in deep tissues and joints (eg, hemarthrosis) after minor trauma, and prolonged bleeding after surgery.

(Choice A) Autoimmune hepatitis is more common in women than in men and is more often associated with ulcerative colitis than Crohn disease. Patients may be asymptomatic or present with signs of liver dysfunction (eg, jaundice, hepatosplenomegaly, ascites), including easy bruising and gastrointestinal bleeding due to coagulopathy.

(Choice C) Factor VIII deficiency (hemophilia A) is an X-linked recessive coagulation disorder that can manifest as early as birth. Typical features include easy bruising, hemarthrosis, and prolonged bleeding after surgery (eg, tooth extraction).

(Choice D) Immune thrombocytopenic purpura is characterized by autoimmune destruction of platelets and is often associated with viral infections. Platelet abnormalities typically cause superficial microhemorrhages such as petechiae and mucosal bleeding (eg, epistaxis, gingival bleeding).

(Choice E) Leukocytoclastic vasculitis can be associated with antibiotic use (eg, penicillins, cephalosporins) or viral hepatitis infection; however, patients usually develop nonblanching petechiae or palpable purpura without significant bleeding.

Educational objective:
Crohn disease with ileal resection or extensive ileal involvement can cause bile acid malabsorption, which may lead to impaired absorption of fat-soluble vitamins (A, D, E, K). Vitamin K deficiency can result in impaired coagulation with easy bruising, large hematoma formation in deep tissues and joints (eg, hemarthrosis) after minor trauma, and prolonged bleeding after surgery.

Crohn disease typically presents with prolonged diarrhea and abdominal pain. Transmural inflammation of the bowel wall may result in the

Exhibit Display

Bile acid metabolism

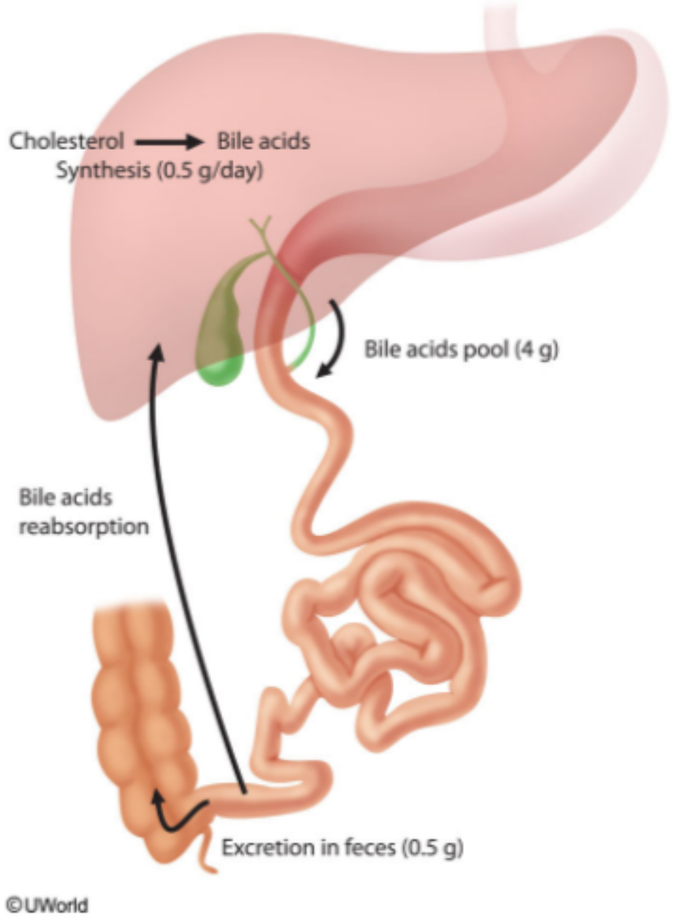

Zoom In | Zoom Out | Reset | Add To New Card | Existing Card

tissues and joints (eg, hemarthrosis) after minor trauma, and prolonged bleeding after surgery.

A 35-year-old woman comes to the office with malaise and generalized weakness. Her other medical problems include type 1 diabetes mellitus and hypothyroidism for which she takes insulin and levothyroxine. She eats a balanced, diabetic diet and exercises 5 times per week. Physical examination shows mild conjunctival pallor.

Laboratory results are as follows:

Hemoglobin	10 g/dL
Hematocrit	30%
Mean corpuscular volume	118 fL

Further evaluation shows a very low vitamin B_{12} level and a normal folate level. Which of the following sets of physiologic alterations is most likely to be present in this patient?

A. Elevated gastrin, high gastric pH, and decreased parietal cell mass
B. Elevated gastrin, high gastric pH, and increased parietal cell mass
C. Elevated gastrin, low gastric pH, and increased parietal cell mass
D. Low gastrin, high gastric pH, and increased parietal cell mass
E. Low gastrin, low gastric pH, and decreased parietal cell mass

Submit

A 35-year-old woman comes to the office with malaise and generalized weakness. Her other medical problems include type 1 diabetes mellitus and hypothyroidism for which she takes insulin and levothyroxine. She eats a balanced, diabetic diet and exercises 5 times per week. Physical examination shows mild conjunctival pallor.

Laboratory results are as follows:

Hemoglobin	10 g/dL
Hematocrit	30%
Mean corpuscular volume	118 fL

Further evaluation shows a very low vitamin B_{12} level and a normal folate level. Which of the following sets of physiologic alterations is most likely to be present in this patient?

- ✓ A. Elevated gastrin, high gastric pH, and decreased parietal cell mass (55%)
- B. Elevated gastrin, high gastric pH, and increased parietal cell mass (4%)
- C. Elevated gastrin, low gastric pH, and increased parietal cell mass (14%)
- D. Low gastrin, high gastric pH, and increased parietal cell mass (5%)
- E. Low gastrin, low gastric pH, and decreased parietal cell mass (19%)

Omitted
Correct answer
A

55%
Answered correctly

02 secs
Time Spent

01/16/2020
Last Updated

Explanation

1
2
3
4
5
6
7
8
9
10
11
12
13
14
15
16
17
18
19
20
21
22
23
24
25
26
27
28
29
30
31

Pathogenesis of autoimmune gastritis

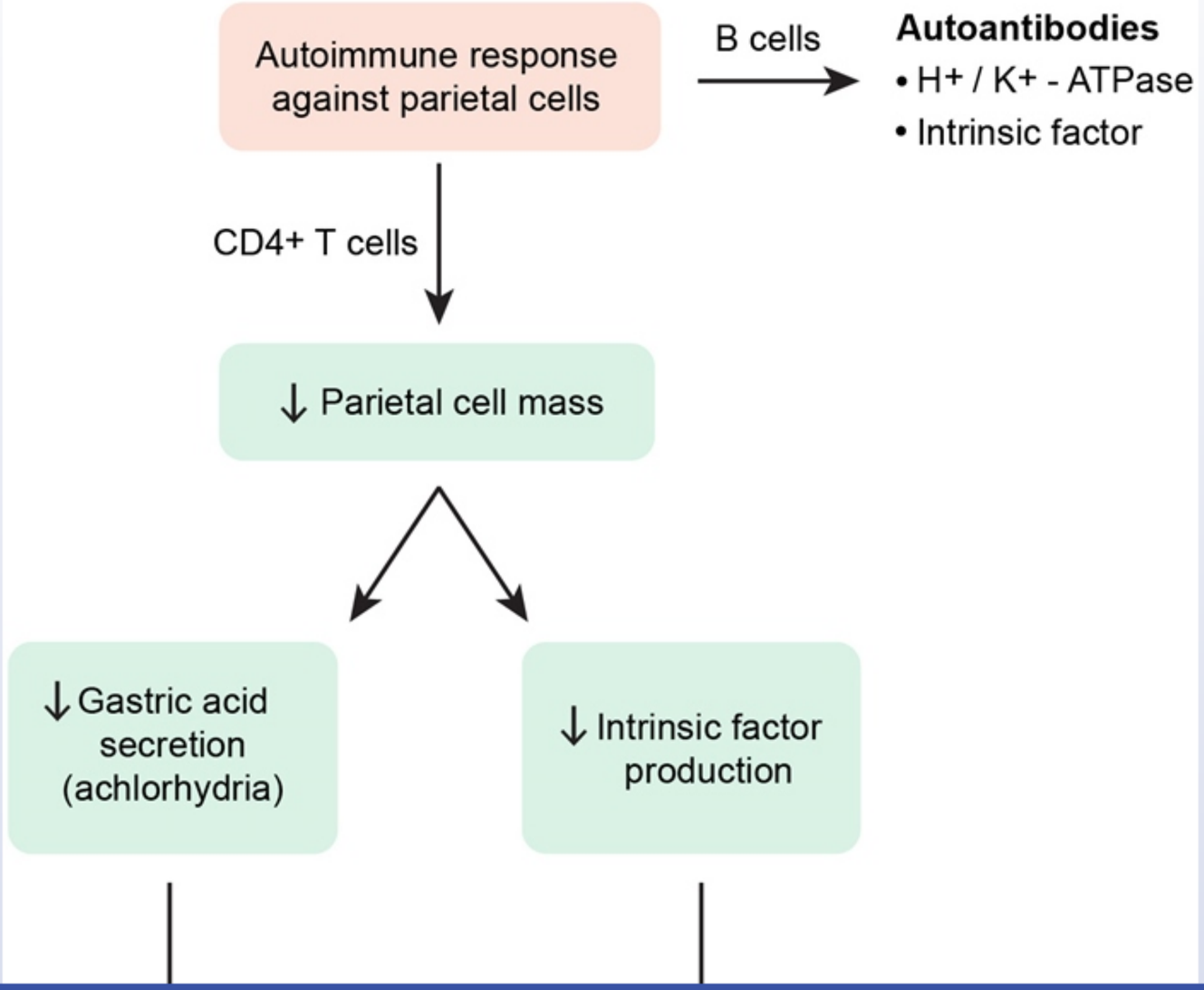

1
2
3
4
5
6
7
8
9
10
11
12
13
14
15
16
17
18
19
20
21
22
23
24
25
26
27
28
29
30
31

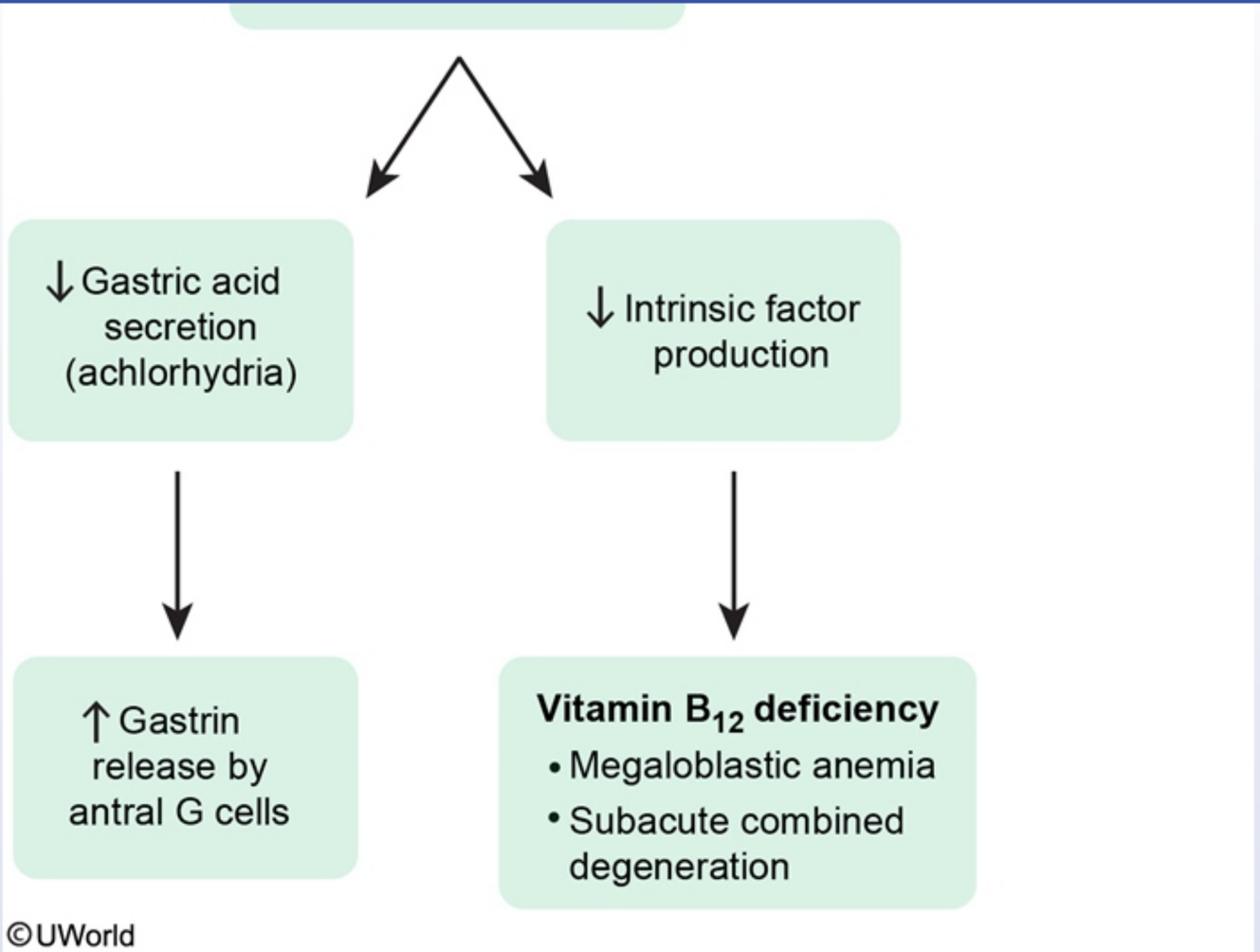

This patient's **vitamin B_{12} (cobalamin) deficiency** in the setting of **preexisting autoimmune disease** (eg, type 1 diabetes mellitus, Hashimoto thyroiditis) is suggestive of **pernicious anemia**. This condition occurs as a result of a CD4+ cell-mediated immune response against parietal cells found in the body and fundus of the stomach (autoantibodies against parietal cell components are also produced and are useful for diagnosis but not significantly involved in the pathogenesis). Progressive destruction of oxyntic (acid-producing) mucosa leads to **loss of parietal cell mass**,

found in the body and fundus of the stomach (autoantibodies against parietal cell components are also produced and are useful for diagnosis but not significantly involved in the pathogenesis). Progressive destruction of oxyntic (acid-producing) mucosa leads to **loss of parietal cell mass**, causing the following effects:

- Decreased intrinsic factor secretion impairs absorption of dietary vitamin B_{12} by the terminal ileum, resulting in vitamin B_{12} deficiency and the development of **megaloblastic anemia**.
- Decreased secretion of hydrochloric acid (achlorhydria) causes an **elevated intraluminal pH** that **stimulates gastrin secretion** by gastric G cells.

(Choice B) Proton pump inhibitors result in elevated intraluminal pH, causing upregulation of gastrin secretion. Prolonged use may result in secondary hypertrophy and hyperplasia of parietal cells.

(Choice C) Gastrinomas are gastrin-secreting tumors commonly located in the pancreas and duodenum. Excess gastrin production leads to parietal cell hypertrophy and hydrochloric acid hypersecretion.

(Choices D and E) In patients with pernicious anemia, autoimmune destruction of parietal cells results in excess gastrin production (not decreased production). This increases the risk of neuroendocrine (carcinoid) tumors.

Educational objective:
Pernicious anemia is an autoimmune disease characterized by CD4+ cell-mediated destruction of parietal cells. As parietal cells are destroyed, their ability to secrete hydrochloric acid decreases, resulting in an elevated intraluminal pH that leads to upregulation of gastrin secretion. Patients also develop vitamin B_{12} deficiency as a result of decreased intrinsic factor secretion.

References

- Diagnosis and management of pernicious anemia.

Pathophysiology	Gastrointestinal & Nutrition	Vitamin b12 deficiency
Subject	System	Topic

Copyright © UWorld. All rights reserved.

1
2
3
4
5
6
7
8
9
10
11
12
13
14
15
16
17
18
19
20
21
22
23
24
25
26
27
28
29
30
31

Exhibit Display

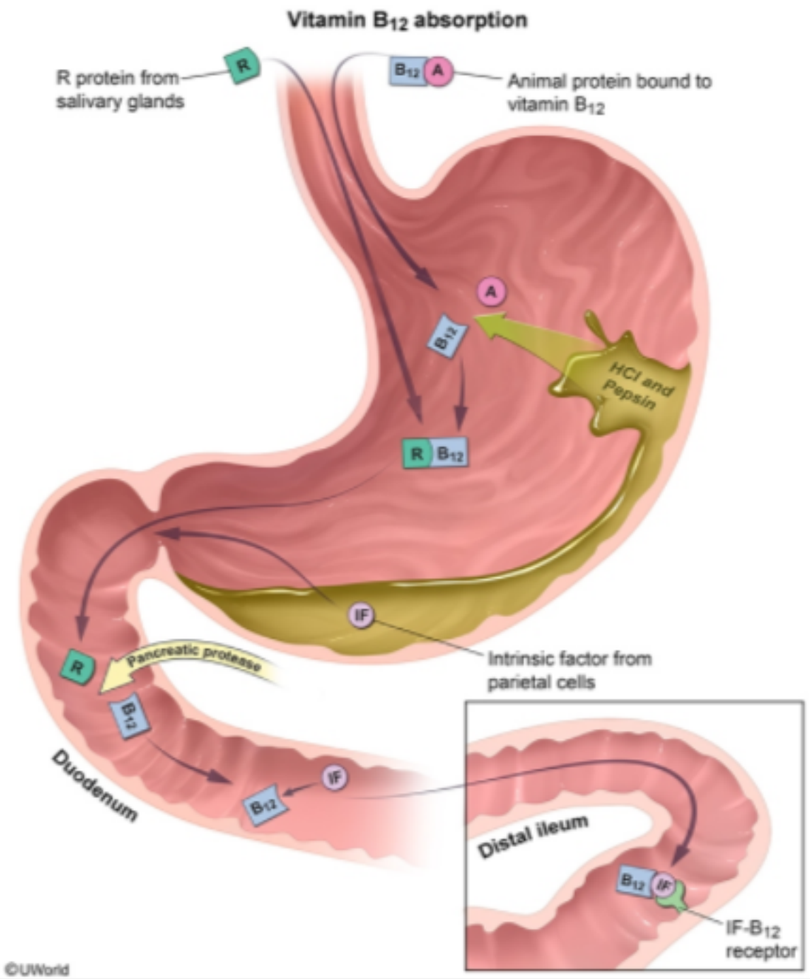

Zoom In | Zoom Out | Reset | Add To New Card | Existing Card

(Choices D and E) In patients with pernicious anemia, autoimmune destruction of parietal cells results in excess gastrin production (not

1
2
3
4
5
6
7
8
9
10
11
12
13
14
15
16
17
18
19
20
21
22
23
24
25
26
27
28
29
30
31

A 52-year-old woman is evaluated for a 6-month history of progressive fatigue and generalized pruritus. She has had no significant prior medical conditions or surgery and takes no medications. The patient does not use tobacco, alcohol, or illicit drugs. Her sister has Sjögren syndrome. Physical examination shows skin excoriations and mild hepatomegaly. Laboratory results are as follows.

Alkaline phosphatase	480 U/L
Aspartate aminotransferase (SGOT)	37 U/L
Alanine aminotransferase (SGPT)	49 U/L
Antimitochondrial antibody	positive

The pathogenesis of this patient's disease process most closely resembles that of which of the following conditions?

A. Acetaminophen toxicity
B. Alcoholic hepatitis
C. Budd-Chiari syndrome
D. Graft versus host disease
E. Hemochromatosis
F. Reye syndrome

Submit

A 52-year-old woman is evaluated for a 6-month history of progressive fatigue and generalized pruritus. She has had no significant prior medical conditions or surgery and takes no medications. The patient does not use tobacco, alcohol, or illicit drugs. Her sister has Sjögren syndrome. Physical examination shows skin excoriations and mild hepatomegaly. Laboratory results are as follows.

Alkaline phosphatase	480 U/L
Aspartate aminotransferase (SGOT)	37 U/L
Alanine aminotransferase (SGPT)	49 U/L
Antimitochondrial antibody	positive

The pathogenesis of this patient's disease process most closely resembles that of which of the following conditions?

- A. Acetaminophen toxicity (2%)
- B. Alcoholic hepatitis (6%)
- C. Budd-Chiari syndrome (14%)
- ✓ D. Graft versus host disease (59%)
- E. Hemochromatosis (9%)
- F. Reye syndrome (7%)

Omitted
Correct answer
D

59%
Answered correctly

02 secs
Time Spent

04/24/2020
Last Updated

1
2
3
4
5
6
7
8
9
10
11
12
13
14
15
16
17
18
19
20
21
22
23
24
25
26
27
28
29
30
31

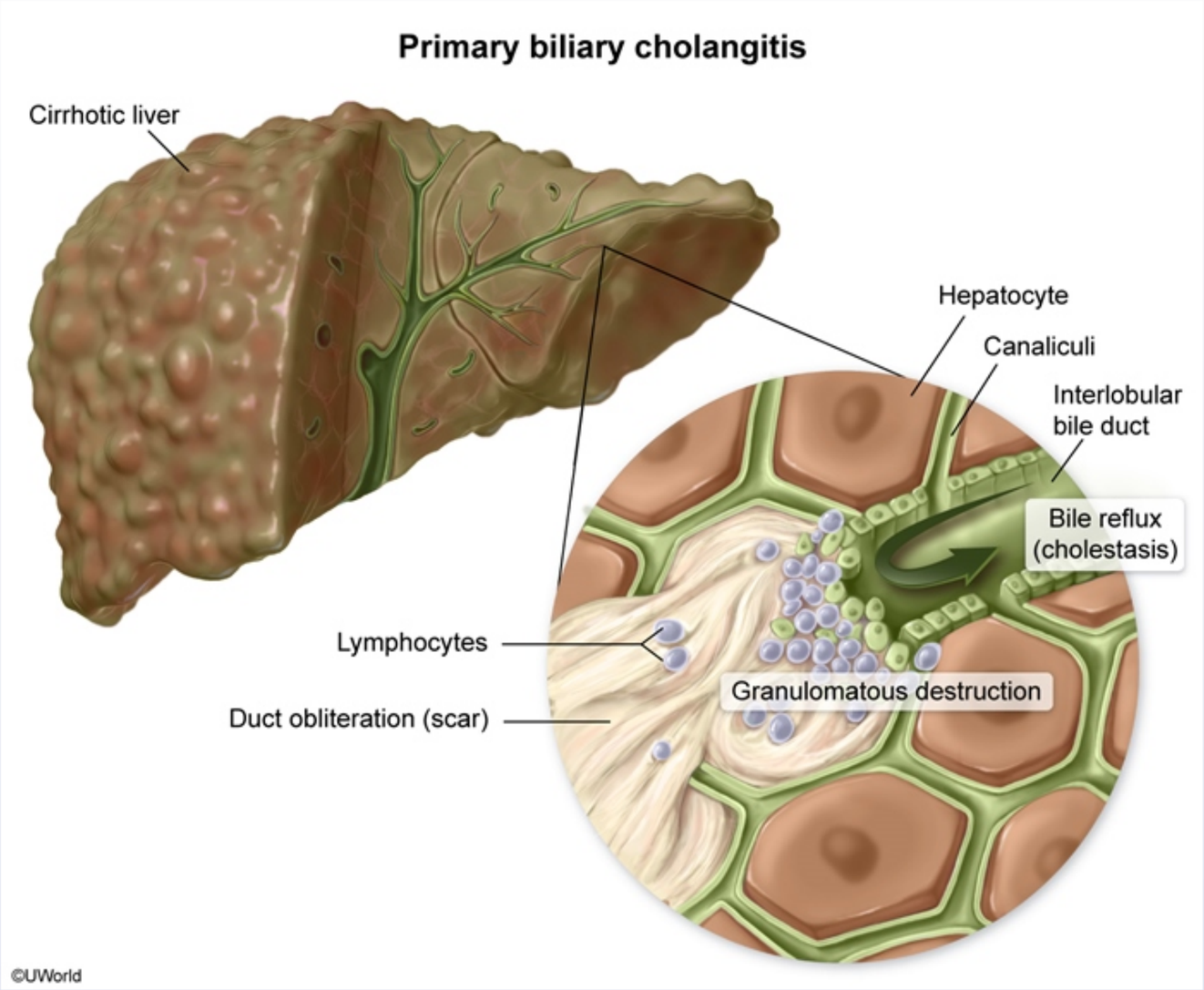

Primary biliary cholangitis (PBC, formerly primary biliary cirrhosis) is a chronic **autoimmune liver disease** characterized by destruction of small and midsized intrahepatic bile ducts with resulting cholestasis. It is most common in middle-aged women and is frequently associated with other

©UWorld

Primary biliary cholangitis (PBC, formerly primary biliary cirrhosis) is a chronic **autoimmune liver disease** characterized by destruction of small and midsized intrahepatic bile ducts with resulting cholestasis. It is most common in middle-aged women and is frequently associated with other autoimmune disorders (eg, Sjögren syndrome, rheumatoid arthritis). Clinical features include fatigue, itching, and hepatomegaly. Serum alkaline phosphatase is elevated, and **antimitochondrial antibody** titers are positive in most cases. Biopsy findings in PBC typically show patchy **lymphocytic inflammation**, leading to granulomatous **destruction of intrahepatic bile ducts** (ie, florid duct lesion), with necrosis and micronodular regeneration of periportal tissues.

Of the diseases listed, only **graft versus host disease** (GVHD) causes similar **immune-mediated** destruction of intrahepatic bile ducts. GVHD occurs in immunocompromised patients following transplant of allogeneic bone marrow or other lymphocyte-rich tissues (eg, nonirradiated blood). Donor T-cells migrate into host tissues, where they recognize host major histocompatibility complex antigens as foreign. Liver involvement is often heralded by a rise in alkaline phosphatase and characterized histologically by **lymphocytic infiltration** and **destruction of small intrahepatic bile ducts**, highlighting the **immunologic etiology** of both diseases.

(Choice A) Serious acetaminophen overdose causes direct hepatocellular toxicity resulting in liver failure with centrilobular necrosis that can extend to include entire lobules.

(Choice B) Alcoholic hepatitis (due to toxicity from chronic ethanol ingestion) is characterized by hepatocellular swelling and necrosis, steatosis, Mallory bodies, neutrophilic infiltration, and fibrosis.

(Choice C) Budd-Chiari syndrome is due to occlusion of the hepatic veins with a resulting increase in intrahepatic pressure. Gross findings include hepatomegaly with a tense capsule and reddish-purple parenchyma. Typical microscopic findings include severe centrilobular congestion and necrosis.

(Choice E) Hemochromatosis is due to abnormal iron absorption and results in deposition of hemosiderin in the liver. Biopsy is characterized by visible iron within hepatocytes.

(Choice F) Reye syndrome occurs in children with underlying inborn errors in metabolism; acute viral illness (often with concomitant aspirin use) promotes mitochondrial injury and subsequent alterations in metabolism that result in encephalopathy and hepatic dysfunction. Biopsy demonstrates panlobular microvesicular steatosis.

Educational objective:

heralded by a rise in alkaline phosphatase and characterized histologically by **lymphocytic infiltration** and **destruction of small intrahepatic**

Exhibit Display

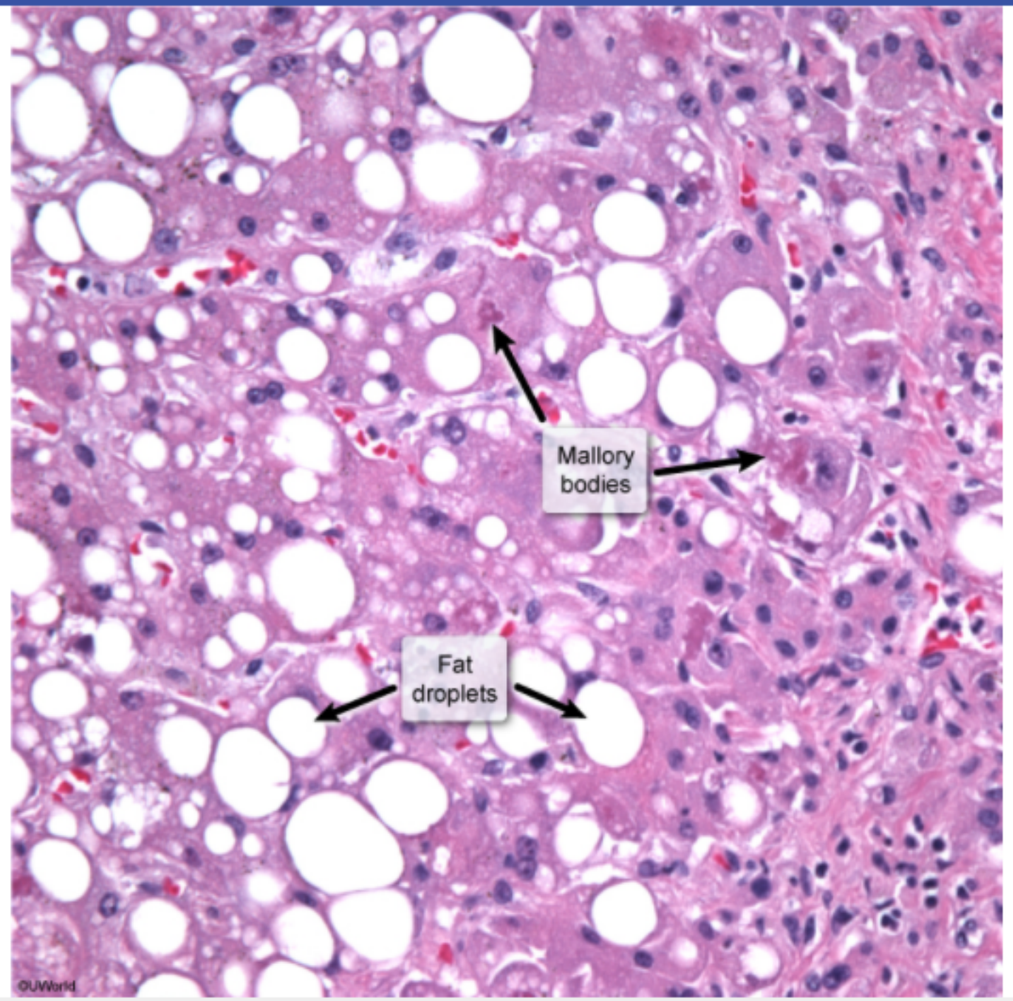

Zoom In | Zoom Out | Reset | Add To New Card | Existing Card

heralded by a rise in alkaline phosphatase and characterized histologically by **lymphocytic infiltration** and **destruction of small intrahepatic**

Exhibit Display

Hereditary hemochromatosis

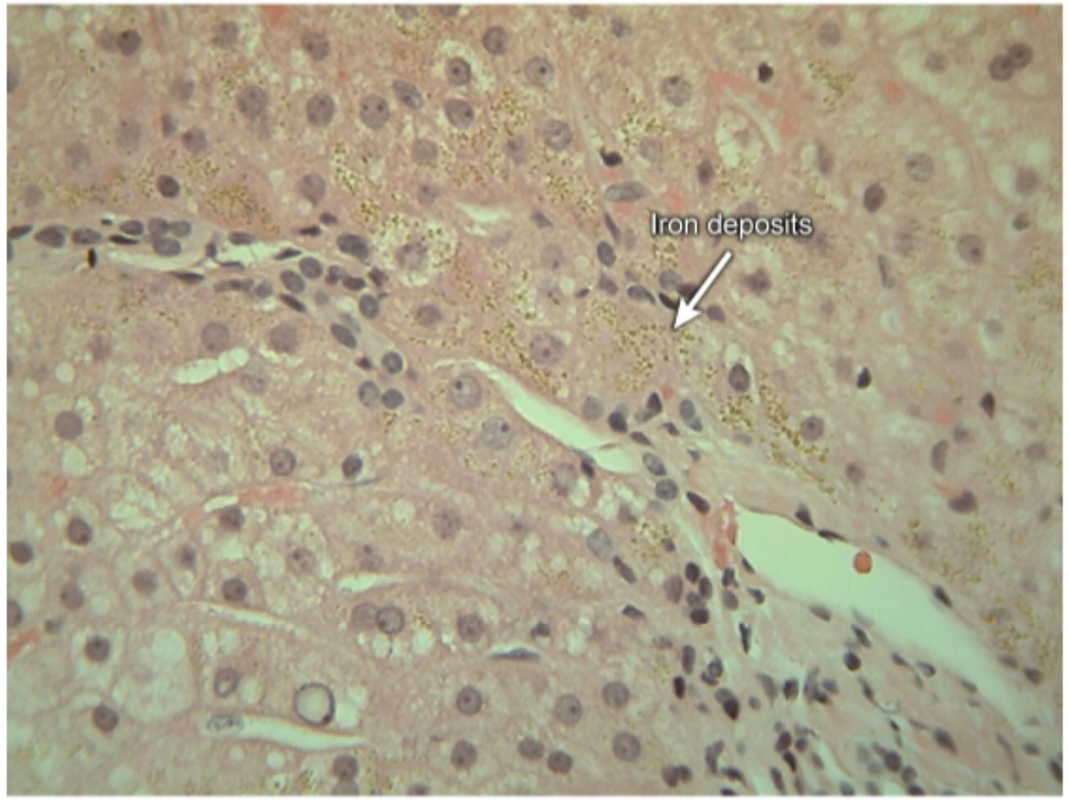

©UWorld

Zoom In | Zoom Out | Reset | Add To New Card | Existing Card

1
2
3
4
5
6
7
8
9
10
11
12
13
14
15
16
17
18
19
20
21
22
23
24
25
26
27
28
29
30
31

A 32-year-old male with anorexia and fatigue is found to have persistently elevated serum alanine aminotransferase (ALT) and aspartate aminotransferase (AST) levels. He is also positive for HBsAg. Which of the following best describes the mechanism of liver injury in this patient?

A. Direct viral cytotoxic effect with hepatocyte necrosis

B. Antibody response to viral antigens on the cell surface with antibody-mediated cell damage

C. Circulating viral antigen-antibody complexes with small vessel deposition and immunologic vessel injury

D. Antigen mimicry with generation of self-antigen recognizing CD4+ T lymphocytes that damage hepatocytes

E. CD8+ T lymphocyte response to viral antigens on the cell surface resulting in hepatocyte damage

Submit

A 32-year-old male with anorexia and fatigue is found to have persistently elevated serum alanine aminotransferase (ALT) and aspartate aminotransferase (AST) levels. He is also positive for HBsAg. Which of the following best describes the mechanism of liver injury in this patient?

- A. Direct viral cytotoxic effect with hepatocyte necrosis (26%)
- B. Antibody response to viral antigens on the cell surface with antibody-mediated cell damage (12%)
- C. Circulating viral antigen-antibody complexes with small vessel deposition and immunologic vessel injury (3%)
- D. Antigen mimicry with generation of self-antigen recognizing CD4+ T lymphocytes that damage hepatocytes (4%)
- ✓ E. CD8+ T lymphocyte response to viral antigens on the cell surface resulting in hepatocyte damage (53%)

Omitted
Correct answer
E

53%
Answered correctly

02 secs
Time Spent

02/03/2020
Last Updated

Explanation

Hepatitis B virus infection progresses through two phases: the proliferative phase and the integrative phase.

In the proliferative phase, the entire virion and all related antigens of the episomal HBV DNA are present. On the hepatocyte cell surface, viral HBsAg and HBcAg are expressed in conjunction with the major histocompatibility complex (MHC) class I molecules. This expression serves to activate the cytotoxic CD8+ T lymphocytes, which respond by destroying the infected hepatocytes. Note that the virion itself does not have a cytopathic effect.

In the integrative phase, the HBV DNA is incorporated into the host genome of those hepatocytes that survived the immune response. Infectivity ceases and liver damage tapers off when the antiviral antibodies appear and viral replication stops. The risk of hepatocellular carcinoma, however, remains elevated because of the HBV DNA that has been integrated into the host genome.

Hepatitis B virus infection progresses through two phases: the proliferative phase and the integrative phase.

In the proliferative phase, the entire virion and all related antigens of the episomal HBV DNA are present. On the hepatocyte cell surface, viral HBsAg and HBcAg are expressed in conjunction with the major histocompatibility complex (MHC) class I molecules. This expression serves to activate the cytotoxic CD8+ T lymphocytes, which respond by destroying the infected hepatocytes. Note that the virion itself does not have a cytopathic effect.

In the integrative phase, the HBV DNA is incorporated into the host genome of those hepatocytes that survived the immune response. Infectivity ceases and liver damage tapers off when the antiviral antibodies appear and viral replication stops. The risk of hepatocellular carcinoma, however, remains elevated because of the HBV DNA that has been integrated into the host genome.

(Choice A) Hepatitis B virus has no direct cytotoxic effect.

(Choice B) Host antibody HBsAb neutralizes HBV infectivity by binding to the viral surface antigen HBsAg and preventing the antigen from interacting with hepatocyte receptors. Note that this neutralization occurs before the virus enters the hepatocyte, and therefore would not be associated with hepatocellular damage.

(Choice C) Antigen-antibody complexes cause some of the early symptoms of hepatitis B virus infection (eg, arthralgias, arthritis, and urticaria) as well as some of the chronic complications (eg, immune complex glomerulonephritis, cryoglobulinemia, vasculitis). These complexes are not responsible for hepatocellular damage, however.

(Choice D) The pathogenesis of autoimmune hepatitis (not hepatitis B infection) involves antigen mimicry with generation of self-antigen recognizing CD4+ T lymphocytes that damage hepatocytes.

Educational Objective:
Hepatitis B virus does not have a cytotoxic effect itself; however, the presence of viral HBsAg and HBcAg on the cell surface stimulate the host's cytotoxic CD8+ T lymphocytes to destroy infected hepatocytes.

Pathophysiology	Gastrointestinal & Nutrition	Hepatitis b
Subject	System	Topic

Copyright © UWorld. All rights reserved.

1
2
3
4
5
6
7
8
9
10
11
12
13
14
15
16
17
18
19
20
21
22
23
24
25
26
27
28
29
30
31

A 26-year-old woman comes to the office due to recurrent nausea and vomiting for the past several months. The patient experiences nausea and epigastric discomfort after meals and often feels full after eating only a small portion of food. On several occasions, she has had emesis containing particles of food that she ate several hours earlier. The patient has a 15-year history of type 1 diabetes mellitus complicated by diabetic nephropathy. Her medications include a basal-bolus insulin regimen and lisinopril. She does not use tobacco, alcohol, or illicit drugs. Vital signs are within normal limits. The abdomen is soft and nontender with no organomegaly. Bowel sounds are normal. Testing of stool for occult blood is negative. An upper gastrointestinal endoscopy is unremarkable. Which of the following mechanisms is most likely responsible for this patient's current symptoms?

A. Decreased activity of vagus motor nucleus
B. Disruption of lower esophageal sphincter
C. Dysfunction of gastric enteric neurons
D. Excessive production of cholecystokinin
E. Hypertrophy of pyloric smooth muscles

Submit

A 26-year-old woman comes to the office due to recurrent nausea and vomiting for the past several months. The patient experiences nausea and epigastric discomfort after meals and often feels full after eating only a small portion of food. On several occasions, she has had emesis containing particles of food that she ate several hours earlier. The patient has a 15-year history of type 1 diabetes mellitus complicated by diabetic nephropathy. Her medications include a basal-bolus insulin regimen and lisinopril. She does not use tobacco, alcohol, or illicit drugs. Vital signs are within normal limits. The abdomen is soft and nontender with no organomegaly. Bowel sounds are normal. Testing of stool for occult blood is negative. An upper gastrointestinal endoscopy is unremarkable. Which of the following mechanisms is most likely responsible for this patient's current symptoms?

- A. Decreased activity of vagus motor nucleus (15%)
- B. Disruption of lower esophageal sphincter (11%)
- ✓ C. Dysfunction of gastric enteric neurons (63%)
- D. Excessive production of cholecystokinin (3%)
- E. Hypertrophy of pyloric smooth muscles (6%)

Omitted
Correct answer
C

63%
Answered correctly

02 secs
Time Spent

03/21/2020
Last Updated

Explanation

Diabetic gastroparesis	
	• Autonomic neuropathy

Diabetic gastroparesis	
Pathogenesis	• Autonomic neuropathy • Destruction of enteric neurons • Failure of relaxation in fundus & uncoordinated peristalsis
Risk factors	• Long-standing diabetes (especially type 1) • Chronic poor control • Labile blood glucose
Clinical presentation	• Postprandial bloating & vomiting • Early satiety • Impaired nutrition & weight loss
Diagnosis	• Nuclear gastric emptying study: delayed transit into duodenum
Treatment	• Promotility drugs: metoclopramide, erythromycin

This patient with diabetes has postprandial nausea, vomiting, early satiety, and regurgitation of undigested food particles, which is suggestive of **diabetic gastroparesis**. Gastroparesis is a type of **autonomic neuropathy** involving the gastrointestinal tract and is characterized by delayed gastric emptying not due to an obstruction.

Normal postprandial gastric activity is a multistep process that occurs in response to food ingestion. After food passes down the esophagus, vagally stimulated enteric neurons release nitric oxide to induce relaxation of the fundus of the stomach and accommodate the incoming food bolus. Specialized gastric pacemaker cells (interstitial cells of Cajal) initiate pacesetter potentials (slow waves), which generate circumferential contractions of the gastric smooth muscle (peristalsis). Peristalsis facilitates food mixing and propulsion toward the pylorus.

Chronic hyperglycemia in patients with diabetes can result in **destruction of the enteric neurons**. Loss of nitric oxide–containing neurons results in impaired fundal relaxation, and loss of the interstitial cells of Cajal results in uncoordinated smooth muscle contractions and ineffective peristalsis, both of which **delay gastric emptying**.

(Choice A) Chronic hyperglycemia can cause vagus nerve denervation with axonal damage, which can contribute to diabetic gastroparesis

1
2
3
4
5
6
7
8
9
10
11
12
13
14
15
16
17
18
19
20
21
22
23
24
25
26
27
28
29
30
31

Normal postprandial gastric activity is a multistep process that occurs in response to food ingestion. After food passes down the esophagus, vagally stimulated enteric neurons release nitric oxide to induce relaxation of the fundus of the stomach and accommodate the incoming food bolus. Specialized gastric pacemaker cells (interstitial cells of Cajal) initiate pacesetter potentials (slow waves), which generate circumferential contractions of the gastric smooth muscle (peristalsis). Peristalsis facilitates food mixing and propulsion toward the pylorus.

Chronic hyperglycemia in patients with diabetes can result in **destruction of the enteric neurons**. Loss of nitric oxide–containing neurons results in impaired fundal relaxation, and loss of the interstitial cells of Cajal results in uncoordinated smooth muscle contractions and ineffective peristalsis, both of which **delay gastric emptying**.

(Choice A) Chronic hyperglycemia can cause vagus nerve denervation with axonal damage, which can contribute to diabetic gastroparesis. However, the vagal motor nucleus is located in the brainstem and is typically unaffected by diabetes.

(Choice B) Disruption of the lower esophageal sphincter can cause symptoms of acid reflux. Although severe gastroesophageal reflux can cause regurgitation, a history of heartburn or epigastric pain would be expected. In addition, upper endoscopy typically shows evidence of esophagitis (eg, mucosal erythema, exudates).

(Choice D) Cholecystokinin is secreted in response to fat- or protein-rich meals and slows gastric emptying to improve digestion of these nutrients. Cholecystokinin secretion may actually be reduced in diabetes and is not thought to be a major cause of diabetic gastroparesis.

(Choice E) Hypertrophy of pyloric smooth muscles is seen in congenital pyloric stenosis, which causes projective vomiting and is typically diagnosed in infancy. The smooth muscle cells typically remain normal in diabetic gastroparesis.

Educational objective:
Diabetic gastroparesis results from the destruction of enteric neurons due to chronic hyperglycemia, leading to impaired relaxation and disordered and ineffective peristalsis. This causes delayed gastric emptying, which presents as postprandial fullness, regurgitation of undigested food, nausea, and vomiting.

References

- Diabetic gastroparesis.

Pathophysiology | Gastrointestinal & Nutrition | Gastroparesis

1
2
3
4
5
6
7
8
9
10
11
12
13
14
15
16
17
18
19
20
21
22
23
24
25
26
27
28
29
30
31

A 39-year-old man comes to the clinic with a month-long history of fever, fatigue, joint pain, and an urticarial skin rash. He did not seek attention immediately as he hoped his symptoms would resolve. The patient is generally improving but is still very easily fatigued. Past medical history is unremarkable and the patient takes no regular medications, although he has not seen a physician since early childhood. He is not married and has a history of multiple heterosexual partners. The patient recently stopped smoking, drinks alcohol socially and does not use illicit drugs. Physical examination is notable for a moderately enlarged and tender liver. No jaundice is seen. Laboratory studies show significant elevations in serum alanine aminotransferase (ALT) and aspartate aminotransferase (AST). Which of the following is the most likely diagnosis in this patient?

A. Acute hepatitis B
B. Acute hepatitis C
C. Gilbert syndrome
D. Hemochromatosis
E. Hepatic steatosis
F. Wilson disease

Submit

1
2
3
4
5
6
7
8
9
10
11
12
13
14
15
16
17
18
19
20
21
22
23
24
25
26
27
28
29
30
31

A 39-year-old man comes to the clinic with a month-long history of fever, fatigue, joint pain, and an urticarial skin rash. He did not seek attention immediately as he hoped his symptoms would resolve. The patient is generally improving but is still very easily fatigued. Past medical history is unremarkable and the patient takes no regular medications, although he has not seen a physician since early childhood. He is not married and has a history of multiple heterosexual partners. The patient recently stopped smoking, drinks alcohol socially and does not use illicit drugs. Physical examination is notable for a moderately enlarged and tender liver. No jaundice is seen. Laboratory studies show significant elevations in serum alanine aminotransferase (ALT) and aspartate aminotransferase (AST). Which of the following is the most likely diagnosis in this patient?

- ✓ A. Acute hepatitis B (70%)
- B. Acute hepatitis C (13%)
- C. Gilbert syndrome (2%)
- D. Hemochromatosis (7%)
- E. Hepatic steatosis (4%)
- F. Wilson disease (2%)

Omitted
Correct answer
A

70%
Answered correctly

01 sec
Time Spent

02/09/2020
Last Updated

Explanation

This patient has features of **acute hepatitis B** (HBV), including systemic, skin, and joint symptoms; hepatomegaly; and elevated transaminase levels. Hepatitis B is a DNA virus with an incubation period of 30-180 days. Transmission can occur sexually, parenterally, or vertically. Onset is dominated by nonspecific symptoms, although patients may develop a **serum sickness-like** syndrome with joint pain, lymphadenopathy, and a

This patient has features of **acute hepatitis B** (HBV), including systemic, skin, and joint symptoms; hepatomegaly; and elevated transaminase levels. Hepatitis B is a DNA virus with an incubation period of 30-180 days. Transmission can occur sexually, parenterally, or vertically. Onset is dominated by nonspecific symptoms, although patients may develop a **serum sickness-like** syndrome with joint pain, lymphadenopathy, and a pruritic urticarial vasculitis rash. Right upper quadrant pain can also be present.

Acute HBV is characterized by significant elevations in **aspartate aminotransferase and alanine aminotransferase**, often >10 times the upper limit of normal. Most patients will have nonicteric hepatitis, but icteric hepatitis with jaundice and elevated bilirubin is also common. Impaired hepatic synthetic function, as indicated by a prolonged prothrombin time, confers a poor prognosis. The most important early marker of acute infection is **hepatitis B surface antigen** (HBsAg), which may be detectable prior to symptoms or changes in transaminase levels. IgM anti-hepatitis B core (anti-HBc) may also be positive. **Hepatitis B e antigen** (HBeAg) and HBV DNA counts correlate with **infectivity**.

(Choice B) Acute hepatitis C is typically asymptomatic; dermatologic manifestations (eg, cryoglobulinemia) are seen in chronic infection. This patient is unlikely to have hepatitis C as he does not use intravenous drugs and sexual transmission is rare.

(Choice C) Gilbert syndrome is a common disorder characterized by mild unconjugated hyperbilirubinemia. Patients are almost always asymptomatic.

(Choice D) Hemochromatosis is due to abnormal iron absorption resulting in iron overload. Chronic manifestations include cirrhosis, hyperpigmentation, and diabetes mellitus ("bronze diabetes").

(Choice E) Hepatic steatosis is characterized by excessive deposition of lipids in the liver and is usually caused by chronic alcohol abuse or obesity (and insulin resistance). Steatosis may lead to cirrhosis, but it does not cause acute symptoms.

(Choice F) Wilson disease presents with acute or chronic hepatitis in patients age <30. Neurologic manifestations (eg, cognitive or motor deficits) are frequent. Kayser-Fleischer rings (green or golden corneal deposits) are a common incidental finding.

Educational objective:
Acute hepatitis B infection can cause a serum sickness-like syndrome with joint pain, lymphadenopathy, and a pruritic urticarial rash. Other features may include right upper quadrant pain, hepatomegaly, and elevated hepatic transaminase levels.

References

- Cutaneous manifestations of viral hepatitis.

1
2
3
4
5
6
7
8
9
10
11
12
13
14
15
16
17
18
19
20
21
22
23
24
25
26
27
28
29
30
31

limit of normal. Most patients will have nonicteric hepatitis, but icteric hepatitis with jaundice and elevated bilirubin is also common. Impaired hepatic synthetic function, as indicated by a prolonged prothrombin time, confers a poor prognosis. The most important early marker of acute infection is **hepatitis B surface antigen** (HBsAg), which may be detectable prior to symptoms or changes in transaminase levels. IgM anti-hepatitis B core (anti-HBc) may also be positive. **Hepatitis B e antigen** (HBeAg) and HBV DNA counts correlate with **infectivity**.

(Choice B) Acute hepatitis C is typically asymptomatic; dermatologic manifestations (eg, cryoglobulinemia) are seen in chronic infection. This patient is unlikely to have hepatitis C as he does not use intravenous drugs and sexual transmission is rare.

(Choice C) Gilbert syndrome is a common disorder characterized by mild unconjugated hyperbilirubinemia. Patients are almost always asymptomatic.

(Choice D) Hemochromatosis is due to abnormal iron absorption resulting in iron overload. Chronic manifestations include cirrhosis, hyperpigmentation, and diabetes mellitus ("bronze diabetes").

(Choice E) Hepatic steatosis is characterized by excessive deposition of lipids in the liver and is usually caused by chronic alcohol abuse or obesity (and insulin resistance). Steatosis may lead to cirrhosis, but it does not cause acute symptoms.

(Choice F) Wilson disease presents with acute or chronic hepatitis in patients age <30. Neurologic manifestations (eg, cognitive or motor deficits) are frequent. Kayser-Fleischer rings (green or golden corneal deposits) are a common incidental finding.

Educational objective:
Acute hepatitis B infection can cause a serum sickness-like syndrome with joint pain, lymphadenopathy, and a pruritic urticarial rash. Other features may include right upper quadrant pain, hepatomegaly, and elevated hepatic transaminase levels.

References

- Cutaneous manifestations of viral hepatitis.

Pathophysiology	Gastrointestinal & Nutrition	Hepatitis b
Subject	System	Topic

Copyright © UWorld. All rights reserved.

limit of normal. Most patients will have nonicteric hepatitis, but icteric hepatitis with jaundice and elevated bilirubin is also common. Impaired

Exhibit Display

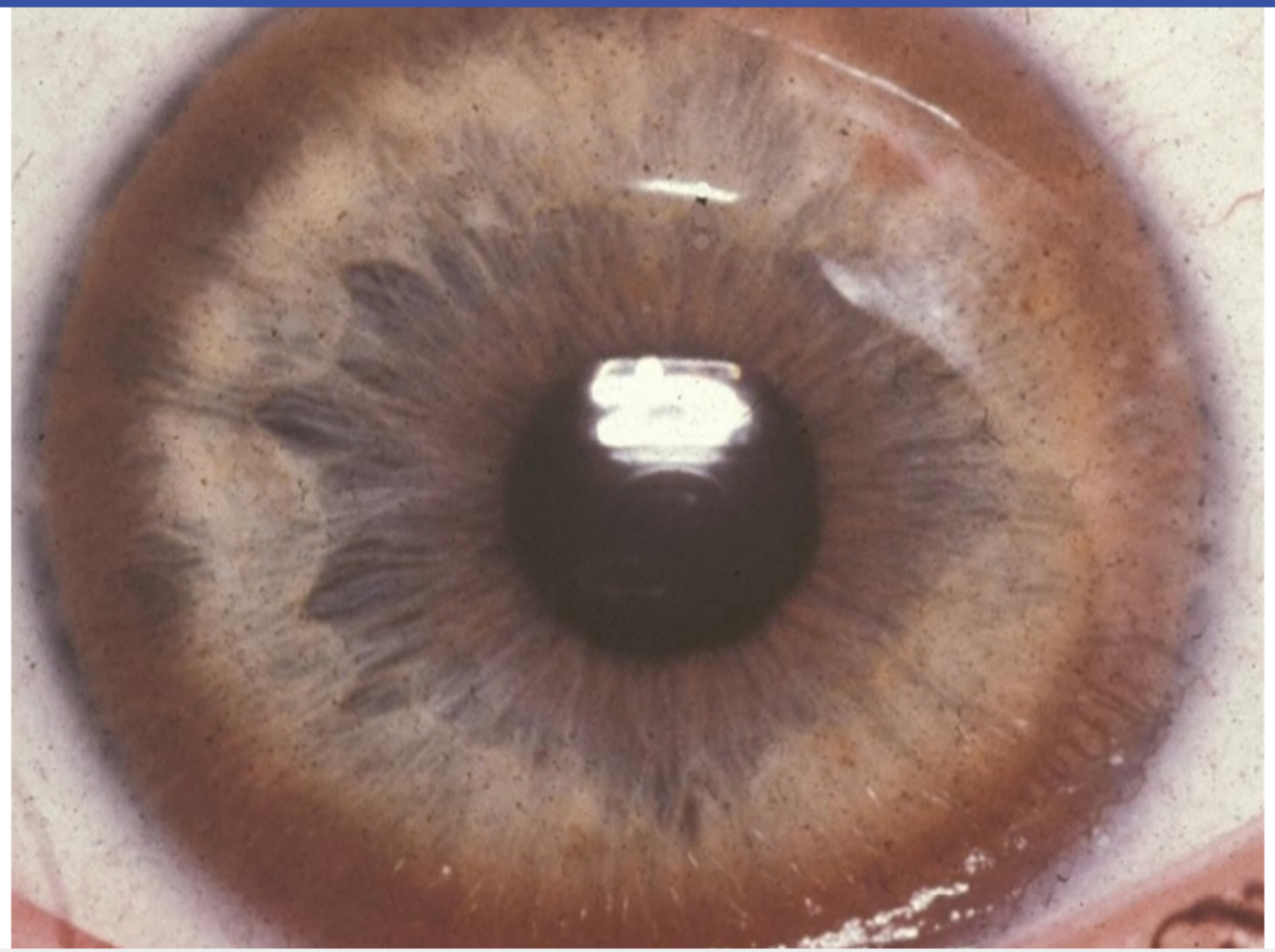

Zoom In | Zoom Out | Reset | Add To New Card | Existing Card

1
2
3
4
5
6
7
8
9
10
11
12
13
14
15
16
17
18
19
20
21
22
23
24
25
26
27
28
29
30
31

1
2
3
4
5
6
7
8
9
10
11
12
13
14
15
16
17
18
19
20
21
22
23
24
25
26
27
28
29
30
31

A 15-month-old boy is brought to the office by his parents for poor weight gain. The parents have also noticed frequent, large, foul-smelling stools. He was admitted to the hospital for a prolonged bout of bacterial pneumonia 6 months ago. Both parents are healthy and have no similar symptoms. The child was born at term at home. He is at the 20th percentile for length and 3rd percentile for weight. Vital signs are normal. On examination, the child appears thin and has a nontender, nondistended abdomen. Which of the following is most likely present in this patient?

A. Decreased fecal calcium content

B. Decreased fecal elastase

C. Increased fecal calprotectin

D. Increased fecal chymotrypsin

E. Increased pancreatic bicarbonate secretion

Submit

A 15-month-old boy is brought to the office by his parents for poor weight gain. The parents have also noticed frequent, large, foul-smelling stools. He was admitted to the hospital for a prolonged bout of bacterial pneumonia 6 months ago. Both parents are healthy and have no similar symptoms. The child was born at term at home. He is at the 20th percentile for length and 3rd percentile for weight. Vital signs are normal. On examination, the child appears thin and has a nontender, nondistended abdomen. Which of the following is most likely present in this patient?

- A. Decreased fecal calcium content (4%)
- ✓ B. Decreased fecal elastase (67%)
- C. Increased fecal calprotectin (4%)
- D. Increased fecal chymotrypsin (14%)
- E. Increased pancreatic bicarbonate secretion (9%)

Omitted
Correct answer
B

67%
Answered correctly

02 secs
Time Spent

06/10/2020
Last Updated

Explanation

Features of cystic fibrosis	
Pathogenesis	• Autosomal recessive mutation (ΔF508) impairs CFTR function • Decreased water content causes thick, viscous mucus: ◦ Chronic airway obstruction

Features of cystic fibrosis	

Pathogenesis	• Autosomal recessive mutation (ΔF508) impairs CFTR function
	• Decreased water content causes thick, viscous mucus:
	  ◦ Chronic airway obstruction
	  ◦ Gastrointestinal malabsorption

Clinical manifestations	• Chronic, productive cough • Recurrent sinopulmonary infections (especially *Staphylococcus aureus* & *Pseudomonas aeruginosa*) • Pancreatic insufficiency • Male infertility (bilateral absence of vas deferens)
Diagnosis	• Elevated sweat chloride levels • Nasal potential difference measurements • Genetic testing for *CFTR* mutations
CFTR = cystic fibrosis transmembrane conductance regulator.	

This patient with failure to thrive, steatorrhea, and a hospitalization for pneumonia most likely has **cystic fibrosis** (CF). CF is an autosomal recessive disorder in which a defective chloride channel causes the accumulation of thick, dehydrated secretions in multiple organs.

In the **pancreas**, viscous mucus obstructs small ducts and acini, preventing **digestive enzymes** from reaching the intestinal lumen and leading to progressive pancreatic inflammation and fibrosis. This ultimately causes **pancreatic insufficiency**, which may be present at birth in patients with CF and typically progresses throughout childhood. Signs of fat and protein malabsorption due to pancreatic insufficiency include **steatorrhea** (bulky, foul-smelling stools), **failure to thrive**, and fat-soluble vitamin deficiencies (A, D, E, and K).

Elastase is a pro-enzyme (ie, zymogen) produced by pancreatic acinar cells and activated by trypsin within the duodenal lumen. Because elastase production and secretion are decreased in patients with pancreatic insufficiency, fecal elastase levels are also decreased; the presence of

This patient with failure to thrive, steatorrhea, and a hospitalization for pneumonia most likely has **cystic fibrosis** (CF). CF is an autosomal recessive disorder in which a defective chloride channel causes the accumulation of thick, dehydrated secretions in multiple organs.

In the **pancreas**, viscous mucus obstructs small ducts and acini, preventing **digestive enzymes** from reaching the intestinal lumen and leading to progressive pancreatic inflammation and fibrosis. This ultimately causes **pancreatic insufficiency**, which may be present at birth in patients with CF and typically progresses throughout childhood. Signs of fat and protein malabsorption due to pancreatic insufficiency include **steatorrhea** (bulky, foul-smelling stools), **failure to thrive**, and fat-soluble vitamin deficiencies (A, D, E, and K).

Elastase is a pro-enzyme (ie, zymogen) produced by pancreatic acinar cells and activated by trypsin within the duodenal lumen. Because elastase production and secretion are decreased in patients with pancreatic insufficiency, fecal elastase levels are also decreased; the presence of **low fecal elastase** is an accurate and noninvasive method for diagnosing pancreatic insufficiency of any cause (eg, CF, chronic pancreatitis).

(Choice A) Dietary absorption of calcium is decreased in CF in part due to vitamin D deficiency, which leads to both hypocalcemia and increased calcium fecal concentration.

(Choice C) Calprotectin is a protein derived from neutrophils that is released into the stool of patients with inflammatory diarrhea (eg, ulcerative colitis, Crohn disease). Fecal calprotectin levels are not increased in CF.

(Choice D) Like elastase, chymotrypsin is a pancreatic digestive enzyme whose fecal concentration would be decreased (not increased) in patients with pancreatic insufficiency.

(Choice E) Bicarbonate is produced and secreted by the pancreas to neutralize gastric acid and raise duodenal pH. Because patients with pancreatic insufficiency have less bicarbonate secretion, duodenal pH will decrease. The low pH can inactivate digestive enzymes produced by the stomach and intestine, further impairing nutrient absorption.

Educational objective:
Pancreatic insufficiency is common in cystic fibrosis because thick, viscous secretions in the pancreas block digestive enzymes, leading to malabsorption (eg, steatorrhea, failure to thrive). The presence of low fecal elastase is an accurate and noninvasive method for diagnosing pancreatic insufficiency.

References

- Pancreatic pathophysiology in cystic fibrosis.

This patient with failure to thrive, steatorrhea, and a hospitalization for pneumonia most likely has **cystic fibrosis** (CF). CF is an autosomal

Exhibit Display

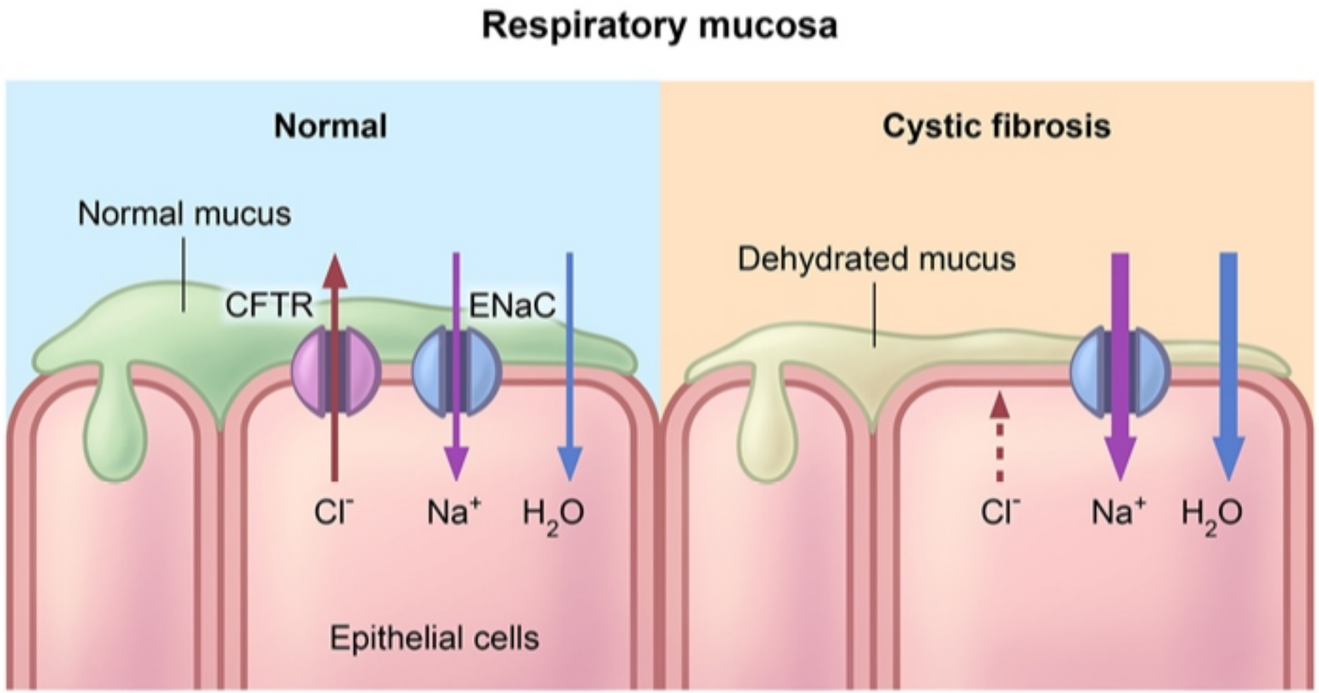

CFTR = cystic fibrosis transmembrane conductance regulator; **ENaC** = epithelial sodium channel.

©UWorld

Zoom In Zoom Out Reset Add To Flash Card

This patient with failure to thrive, steatorrhea, and a hospitalization for pneumonia most likely has **cystic fibrosis** (CF). CF is an autosomal

Exhibit Display

Cystic fibrosis features

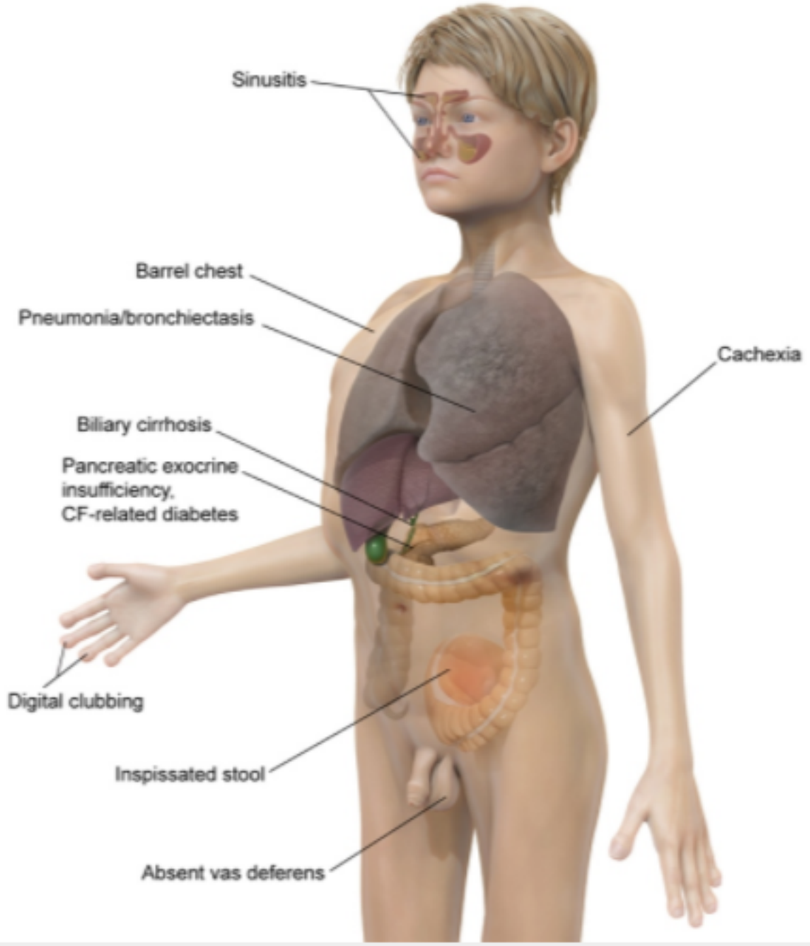

Zoom In Zoom Out Reset Add To Flash Card

This patient with failure to thrive, steatorrhea, and a hospitalization for pneumonia most likely has **cystic fibrosis** (CF). CF is an autosomal

Exhibit Display

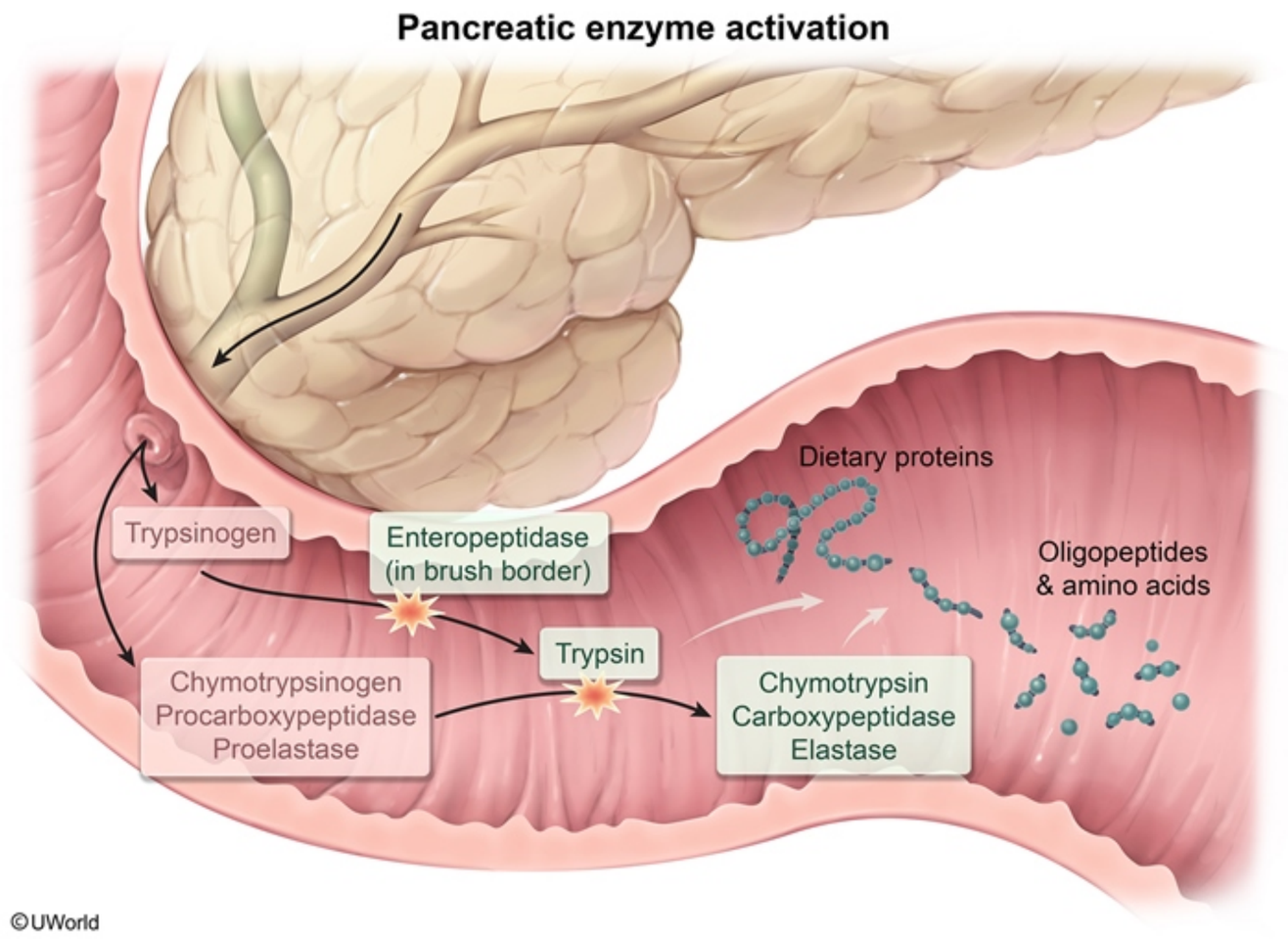

Zoom In Zoom Out Reset Add To Flash Card

1
2
3
4
5
6
7
8
9
10
11
12
13
14
15
16
17
18
19
20
21
22
23
24
25
26
27
28
29
30
31

A 32-year-old woman comes to the clinic due to 6 weeks of bloating and nonbloody diarrhea. She describes having multiple watery bowel movements a day without visible blood. She underwent gastric bypass surgery for morbid obesity 3 years ago. The patient has no other medical conditions. She is a lifelong nonsmoker and does not drink alcohol. Her vital signs are within normal limits. Physical examination is unremarkable. A jejunal aspirate shows bacterial count of $>10^5$ organisms/mL, consistent with small intestinal bacterial overgrowth. Which of the following serum substance levels is most likely to be increased in this patient?

A. Cobalamin

B. Folate

C. Iron

D. Vitamin D_2

E. Zinc

Submit

1
2
3
4
5
6
7
8
9
10
11
12
13
14
15
16
17
18
19
20
21
22
23
24
25
26
27
28
29
30
31

A 32-year-old woman comes to the clinic due to 6 weeks of bloating and nonbloody diarrhea. She describes having multiple watery bowel movements a day without visible blood. She underwent gastric bypass surgery for morbid obesity 3 years ago. The patient has no other medical conditions. She is a lifelong nonsmoker and does not drink alcohol. Her vital signs are within normal limits. Physical examination is unremarkable. A jejunal aspirate shows bacterial count of $>10^5$ organisms/mL, consistent with small intestinal bacterial overgrowth. Which of the following serum substance levels is most likely to be increased in this patient?

A. Cobalamin (15%)
✓ B. Folate (32%)
C. Iron (18%)
D. Vitamin D_2 (18%)
E. Zinc (14%)

Omitted
Correct answer
B

32%
Answered correctly

02 secs
Time Spent

01/22/2020
Last Updated

Explanation

1
2
3
4
5
6
7
8
9
10
11
12
13
14
15
16
17
18
19
20
21
22
23
24
25
26
27
28
29
30
31

Roux-en-Y gastric bypass

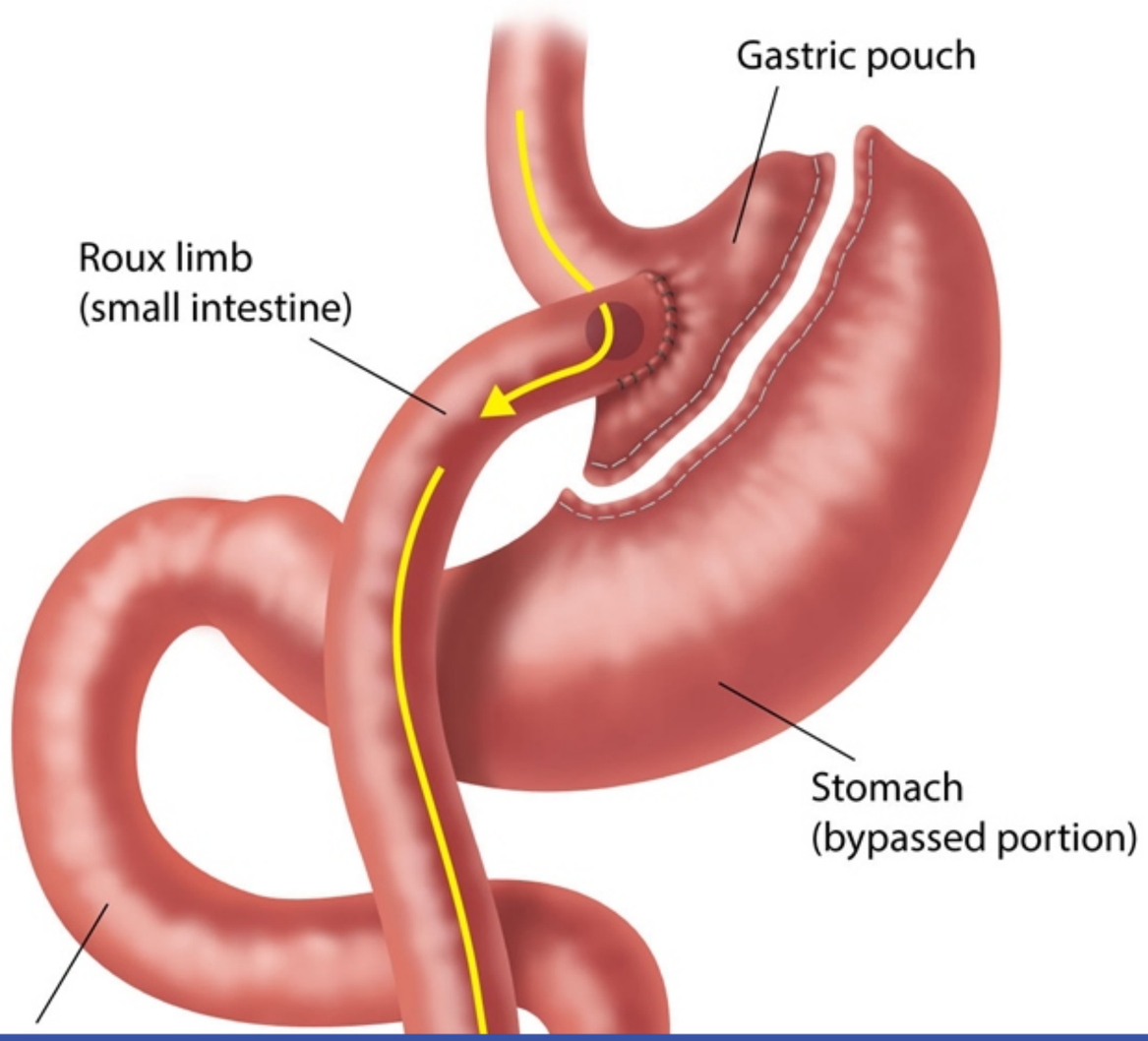

1
2
3
4
5
6
7
8
9
10
11
12
13
14
15
16
17
18
19
20
21
22
23
24
25
26
27
28
29
30
31

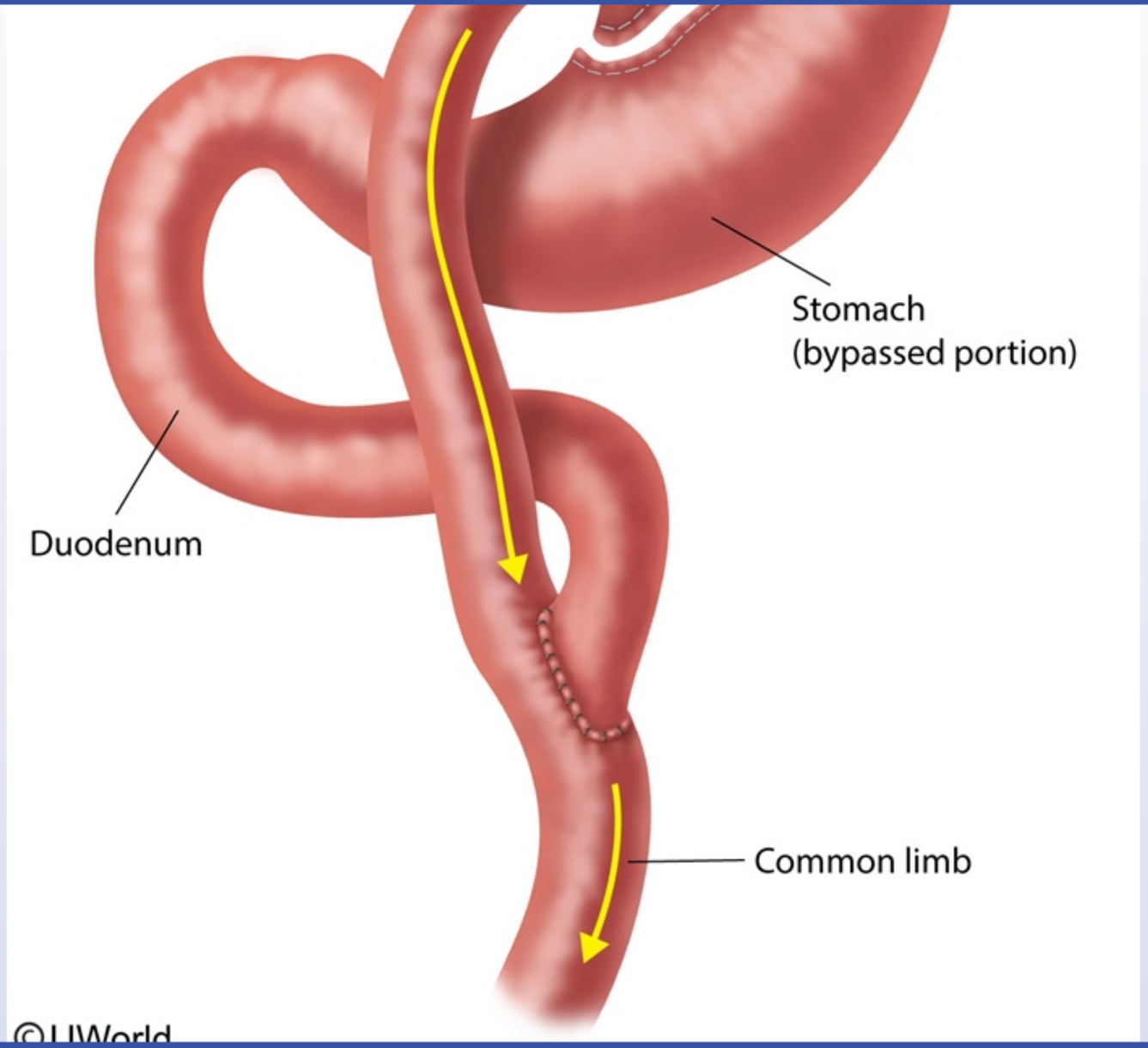

The normal small intestine is colonized with facultative anaerobes, lactobacilli, enterococci, and gram-positive aerobes. **Enteric bacteria** can **produce** vitamins (eg, **vitamin K, folate**), inhibit proliferation of surrounding pathogenic bacteria, and digest unabsorbed dietary sugars and convert them to fatty acids.

A Roux-en-Y gastric bypass surgery typically creates a small gastric pouch, which is removed from the remainder of the stomach and attached to the jejunum via a gastrojejunal anastomosis. The larger bypassed portion of the stomach and duodenum are reattached to the jejunum distally. This results in a closed-ended gastroduodenal limb, in which bacteria can proliferate and ferment any food that may be diverted into this segment. **Small intestinal bacterial overgrowth** (SIBO) is characterized by overproduction of vitamin K and folate, associated with nausea, bloating, abdominal discomfort, and malabsorption.

(Choice A) SIBO typically causes cobalamin (vitamin B_{12}) deficiency due to decreased intestinal absorption of both free and intrinsic factor-bound vitamin B_{12}. In addition, the bacteria can compete by utilizing the vitamin B_{12}.

(Choice C) SIBO can cause iron deficiency due to decreased intestinal absorption, possibly through intestinal mucosal injury from bacterial toxins, unconjugated bile acids, or short-chain fatty acids.

(Choice D) SIBO typically causes malabsorption of fat-soluble vitamins, including A, D, and E. However, vitamin K is usually normal or slightly increased due to increased bacterial synthesis.

(Choice E) In SIBO, zinc deficiency is typically due to small intestinal malabsorption. SIBO patients with diarrhea can also have increased zinc loss.

Educational objective:
Gastric bypass surgery can cause small intestinal bacterial overgrowth (SIBO) due to excessive bacterial proliferation in the blind-ended gastroduodenal segment. SIBO results in deficiency of most vitamins (B_{12}, A, D, and E) and iron, but increased production of folic acid and vitamin K.

References

- Review article: small intestinal bacterial overgrowth--prevalence, clinical features, current and developing diagnostic tests, and treatment.

Pathophysiology Gastrointestinal & Nutrition Small intestinal bacterial overgrowth

1
2
3
4
5
6
7
8
9
10
11
12
13
14
15
16
17
18
19
20
21
22
23
24
25
26
27
28
29
30
31

A 38-year-old man comes to the emergency department with severe abdominal pain and vomiting. The pain radiates to his back and improves by bending forward. Physical examination shows tenderness over the epigastrium and decreased bowel sounds. The patient is admitted to the hospital and treated with intravenous fluids and pain medication, but his condition fails to improve. An abdominal CT scan reveals diffuse pancreatic enlargement with areas of necrosis. The inappropriate activation of which of the following most likely initiated this patient's condition?

A. Amylase
B. Chymotrypsinogen
C. Lipase
D. Proelastase
E. Prophospholipase
F. Trypsinogen

Submit

1
2
3
4
5
6
7
8
9
10
11
12
13
14
15
16
17
18
19
20
21
22
23
24
25
26
27
28
29
30
31

A 38-year-old man comes to the emergency department with severe abdominal pain and vomiting. The pain radiates to his back and improves by bending forward. Physical examination shows tenderness over the epigastrium and decreased bowel sounds. The patient is admitted to the hospital and treated with intravenous fluids and pain medication, but his condition fails to improve. An abdominal CT scan reveals diffuse pancreatic enlargement with areas of necrosis. The inappropriate activation of which of the following most likely initiated this patient's condition?

A. Amylase (3%)
B. Chymotrypsinogen (3%)
C. Lipase (12%)
D. Proelastase (1%)
E. Prophospholipase (0%)
✓ F. Trypsinogen (78%)

Omitted
Correct answer
F

78%
Answered correctly

02 secs
Time Spent

06/30/2020
Last Updated

Explanation

Pathogenesis of acute pancreatitis

Ductal obstruction
- Ampullary obstruction

Direct parenchymal injury
- Alcohol

1
2
3
4
5
6
7
8
9
10
11
12
13
14
15
16
17
18
19
20
21
22
23
24
25
26
27
28
29
30
31

Pathogenesis of acute pancreatitis

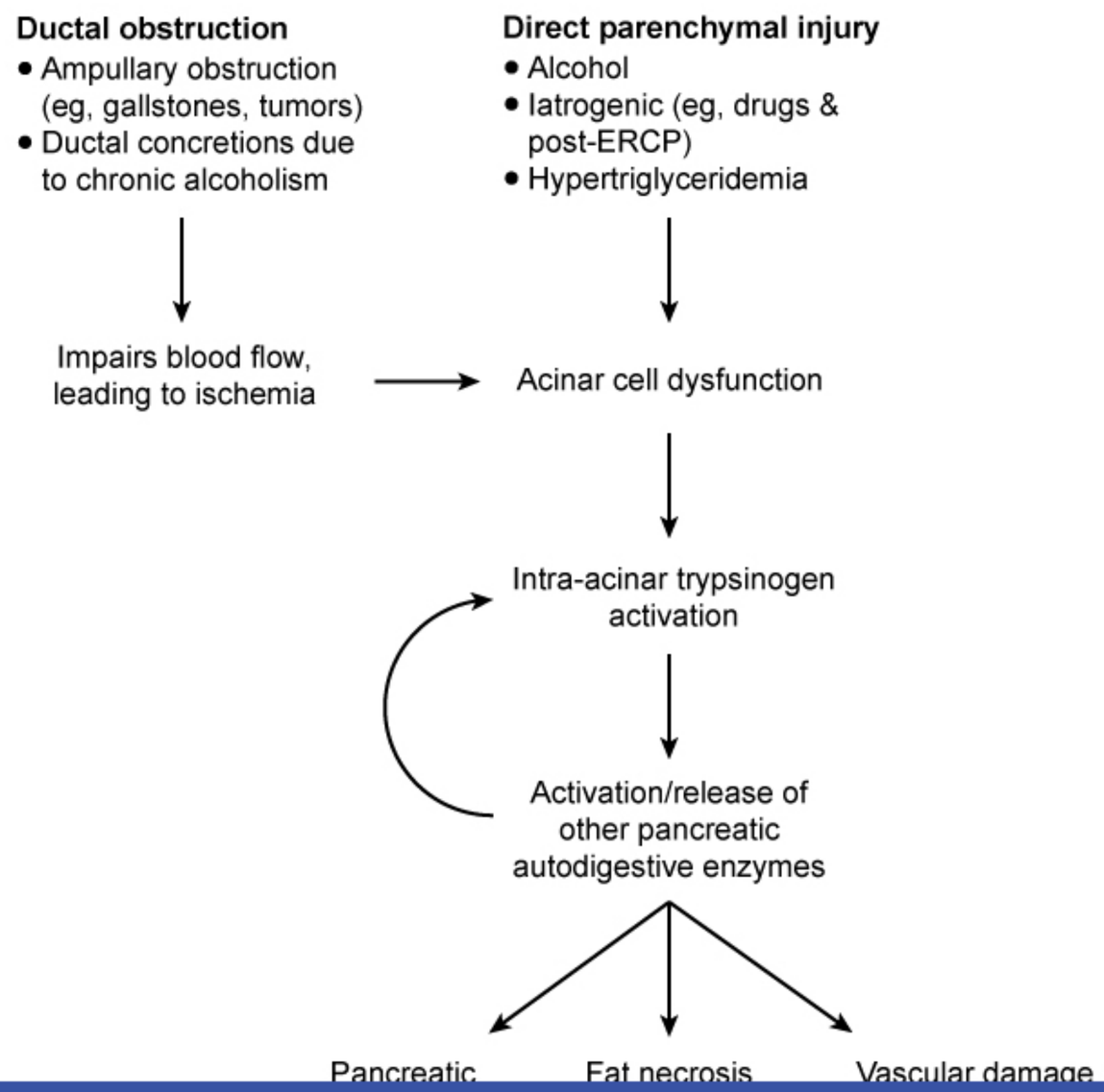

1
2
3
4
5
6
7
8
9
10
11
12
13
14
15
16
17
18
19
20
21
22
23
24
25
26
27
28
29
30
31

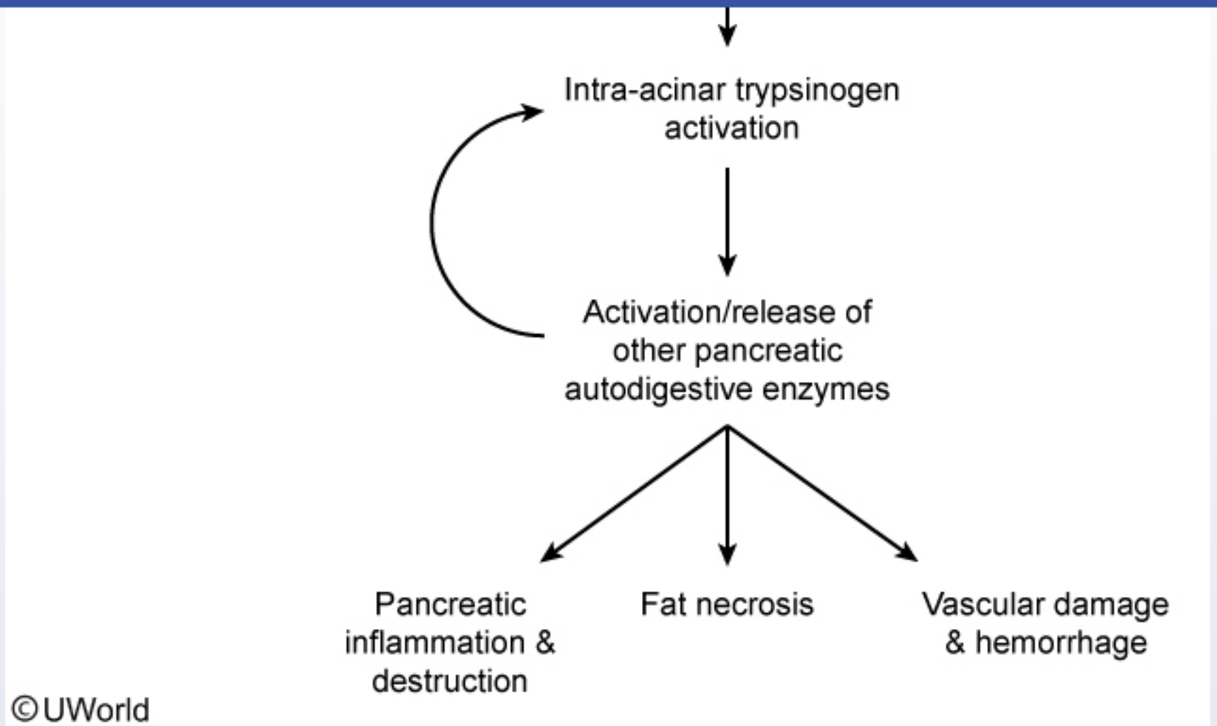

Most pancreatic enzymes are synthesized by pancreatic acinar cells as inactive enzyme precursors called zymogens. Zymogen granules are secreted from the apical surface of acinar cells into the lumen. After traversing the pancreatic duct system, they drain through the ampulla of Vater into the descending part of the duodenum. The enzyme enterokinase (secreted from intestinal mucosa) cleaves trypsinogen into trypsin, its active form. Once a small quantity of trypsin is produced, it activates other zymogens, including chymotrypsin, elastase, and carboxypeptidase, through proteolytic cleavage. Trypsin can also cleave trypsinogen to produce more trypsin, accelerating pancreatic enzyme activation in the duodenum.

The pathogenesis of **acute pancreatitis** begins with either a toxic or an ischemic injury to the acinar cells that leads to **premature activation of trypsin** inside the pancreatic acini. Trypsin then activates the other proteolytic enzymes and starts a self-sustaining cycle of pancreatic inflammation and autodigestion with further release of digestive enzymes. In severe cases, this process can result in **necrotizing pancreatitis**, which is characterized by gross areas of parenchymal necrosis with a high propensity for secondary bacterial infection.

(Choice A) Amylase hydrolyzes starch to produce maltose (a glucose-glucose disaccharide) and trisaccharide maltotriose and limit dextrins. It

©UWorld

Most pancreatic enzymes are synthesized by pancreatic acinar cells as inactive enzyme precursors called zymogens. Zymogen granules are secreted from the apical surface of acinar cells into the lumen. After traversing the pancreatic duct system, they drain through the ampulla of Vater into the descending part of the duodenum. The enzyme enterokinase (secreted from intestinal mucosa) cleaves trypsinogen into trypsin, its active form. Once a small quantity of trypsin is produced, it activates other zymogens, including chymotrypsin, elastase, and carboxypeptidase, through proteolytic cleavage. Trypsin can also cleave trypsinogen to produce more trypsin, accelerating pancreatic enzyme activation in the duodenum.

The pathogenesis of **acute pancreatitis** begins with either a toxic or an ischemic injury to the acinar cells that leads to **premature activation of trypsin** inside the pancreatic acini. Trypsin then activates the other proteolytic enzymes and starts a self-sustaining cycle of pancreatic inflammation and autodigestion with further release of digestive enzymes. In severe cases, this process can result in **necrotizing pancreatitis**, which is characterized by gross areas of parenchymal necrosis with a high propensity for secondary bacterial infection.

(Choice A) Amylase hydrolyzes starch to produce maltose (a glucose-glucose disaccharide) and trisaccharide maltotriose and limit dextrins. It does not require activation by trypsin.

(Choices B, D, and E) Chymotrypsin, phospholipase A2 (which can damage cell membranes), and elastase are secreted by the pancreas as inactive precursors (chymotrypsinogen, prophospholipase A2, and proelastase) that are subsequently activated by trypsin.

(Choice C) Lipase hydrolyzes triglycerides into fatty acids and glycerol. It does not require activation by trypsin (although its activity is increased by colipase, which is activated by trypsin). Release of lipase during acute pancreatitis causes the formation of characteristic calcium soap deposits (fat necrosis).

Educational objective:
Pancreatic zymogens are normally converted into their active form by trypsin in the duodenal lumen. Premature cleavage of trypsinogen to trypsin within the pancreas leads to uncontrolled activation of these zymogens, causing pancreatic autodigestion and acute pancreatitis.

Pathophysiology	Gastrointestinal & Nutrition	Acute pancreatitis
Subject	System	Topic

Copyright © UWorld. All rights reserved.

©UWorld

Exhibit Display

Pancreatic enzyme activation

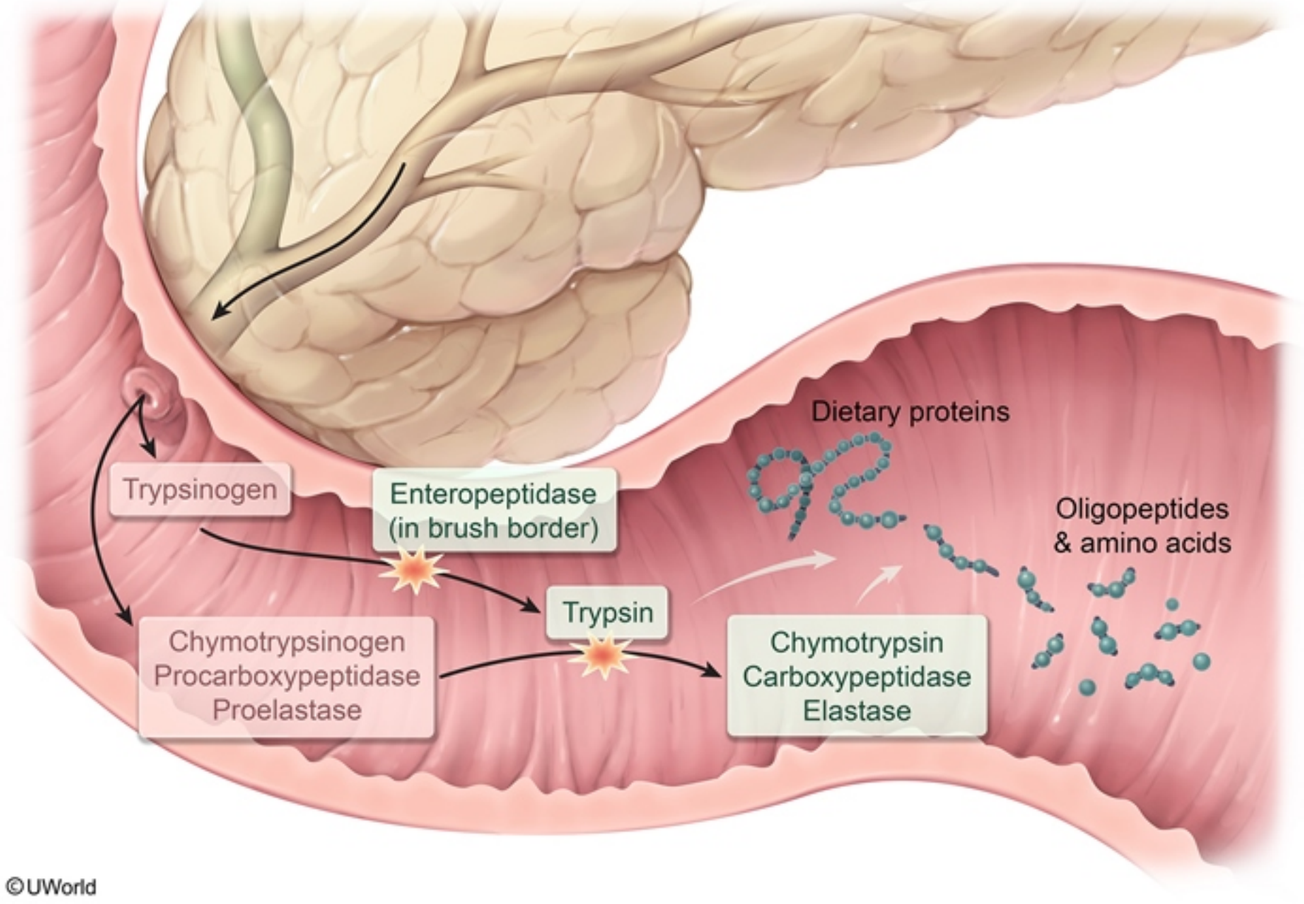

©UWorld

Zoom In | Zoom Out | Reset | Add To New Card | Existing Card

1
2
3
4
5
6
7
8
9
10
11
12
13
14
15
16
17
18
19
20
21
22
23
24
25
26
27
28
29
30
31

A 43-year-old woman comes to the office with a 1-month history of dull abdominal pain that occurs mainly after eating. The pain is localized to the right upper quadrant and is especially severe after fatty meals. Physical examination is unremarkable. Ultrasound of the abdomen reveals several mobile echogenic foci within the gallbladder lumen. Which of the following sets of conditions is most likely present within this patient's gallbladder?

	Cholesterol	Bile acids	Phosphatidylcholine
A.	↓	↑	↑
B.	↓	↑	↓
C.	↓	↓	↑
D.	↑	↓	↓
E.	↑	↑	↓
F.	↑	↓	↑

Submit

1
2
3
4
5
6
7
8
9
10
11
12
13
14
15
16
17
18
19
20
21
22
23
24
25
26
27
28
29
30
31

A 43-year-old woman comes to the office with a 1-month history of dull abdominal pain that occurs mainly after eating. The pain is localized to the right upper quadrant and is especially severe after fatty meals. Physical examination is unremarkable. Ultrasound of the abdomen reveals several mobile echogenic foci within the gallbladder lumen. Which of the following sets of conditions is most likely present within this patient's gallbladder?

	Cholesterol	Bile acids	Phosphatidylcholine
A.	↓ (2%)	↑	↑
B.	↓ (2%)	↑	↓
C.	↓ (1%)	↓	↑
✓ D.	↑ (51%)	↓	↓
E.	↑ (20%)	↑	↓
F.	↑ (22%)	↓	↑

Omitted
Correct answer
D

51%
Answered correctly

02 secs
Time Spent

06/30/2020
Last Updated

1
2
3
4
5
6
7
8
9
10
11
12
13
14
15
16
17
18
19
20
21
22
23
24
25
26
27
28
29
30
31

Pathogenesis of cholesterol gallstones

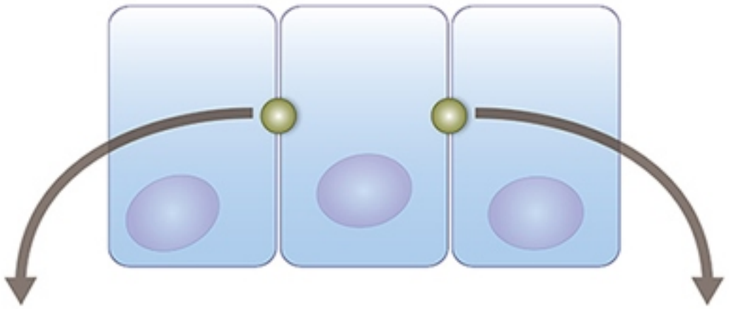

Normal levels of cholesterol, bile salts, and phosphatidylcholine

↓

Biliary micelles and vesicles remain unsaturated with cholesterol

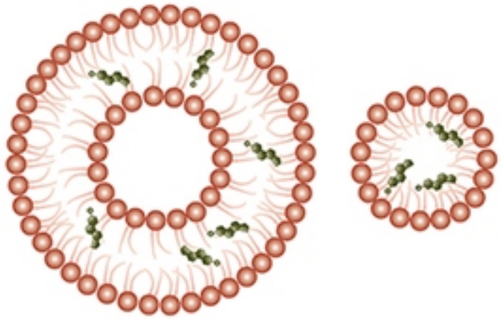

↑ Cholesterol
↓ Bile acids
↓ Phosphatidylcholine

↓

Bile becomes supersaturated with cholesterol

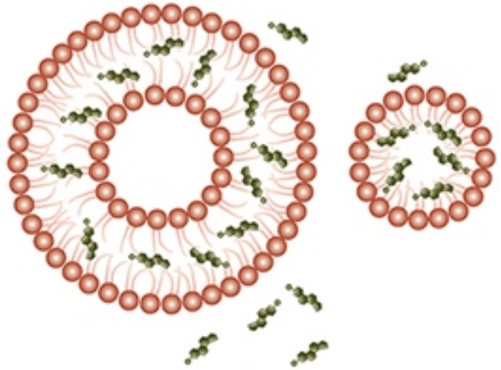

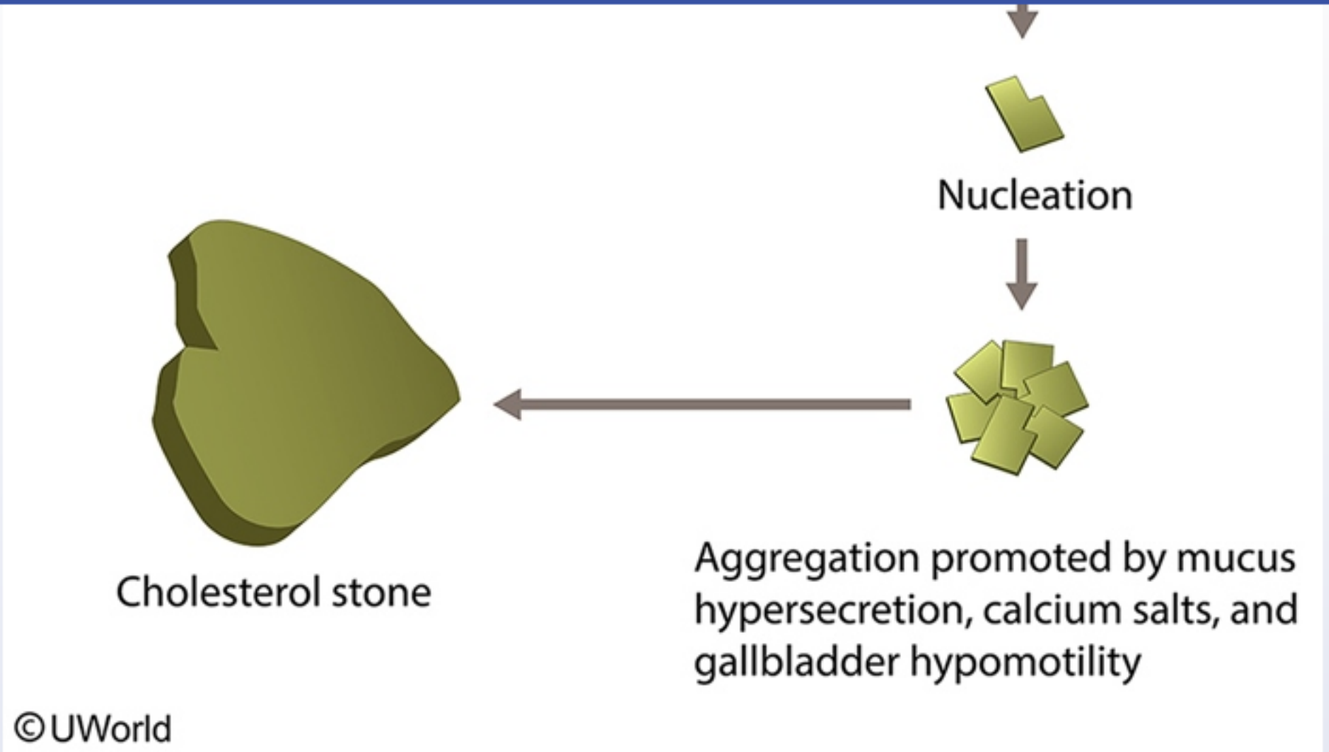

Removal of excess cholesterol from the body occurs via 2 mechanisms: excretion of **free cholesterol** into bile and conversion of cholesterol into **bile acids**.

In the liver, free cholesterol is converted into cholic and chenodeoxycholic acids through a series of chemical reactions beginning with cholesterol 7α-hydroxylase (rate-limiting step in bile acid synthesis). These bile acids are then conjugated to either glycine or taurine (improving solubility and emulsifying ability) to create the bile salts that are actively secreted into the bile canaliculi. As **water-insoluble cholesterol** is secreted in bile, it is rendered soluble in small amounts by the detergent action of these amphipathic (eg, hydrophobic and hydrophilic) bile salts and phosphatidylcholine (a phospholipid). When there is more cholesterol than can be made soluble, it **precipitates into crystals** that eventually grow and merge to form **gallstones**. Gallbladder hypomotility further promotes cholesterol nucleation and gallstone formation.

(Choices A, B, C, E, and F) These represent lower cholesterol concentrations related to total bile salt and phosphatidylcholine levels. Such

1
2
3
4
5
6
7
8
9
10
11
12
13
14
15
16
17
18
19
20
21
22
23
24
25
26
27
28
29
30
31

Cholesterol stone

hypersecretion, calcium salts, and gallbladder hypomotility

©UWorld

Removal of excess cholesterol from the body occurs via 2 mechanisms: excretion of **free cholesterol** into bile and conversion of cholesterol into **bile acids**.

In the liver, free cholesterol is converted into cholic and chenodeoxycholic acids through a series of chemical reactions beginning with cholesterol 7α-hydroxylase (rate-limiting step in bile acid synthesis). These bile acids are then conjugated to either glycine or taurine (improving solubility and emulsifying ability) to create the bile salts that are actively secreted into the bile canaliculi. As **water-insoluble cholesterol** is secreted in bile, it is rendered soluble in small amounts by the detergent action of these amphipathic (eg, hydrophobic and hydrophilic) bile salts and phosphatidylcholine (a phospholipid). When there is more cholesterol than can be made soluble, it **precipitates into crystals** that eventually grow and merge to form **gallstones**. Gallbladder hypomotility further promotes cholesterol nucleation and gallstone formation.

(Choices A, B, C, E, and F) These represent lower cholesterol concentrations related to total bile salt and phosphatidylcholine levels. Such conditions would decrease the likelihood of gallstone formation.

Educational objective:
Elevated cholesterol concentrations increase the likelihood of cholesterol precipitation and gallstone formation. High levels of bile salts and phosphatidylcholine increase cholesterol solubility and decrease the risk of gallstones.

References

- Pathogenesis of gallstones
- Pathogenesis of gallstones.

Pathophysiology	Gastrointestinal & Nutrition	Gallstone disease
Subject	System	Topic

Copyright © UWorld. All rights reserved.

1
2
3
4
5
6
7
8
9
10
11
12
13
14
15
16
17
18
19
20
21
22
23
24
25
26
27
28
29
30
31

A 50-year-old woman comes to the emergency department with severe upper abdominal pain. The pain started suddenly and is sharp and colicky. She has also vomited several times throughout the day, including once while in the emergency department. The patient describes several prior episodes of similar abdominal pain that resolved spontaneously without treatment. Her other medical problems include complicated appendicitis when she was 22 years old. Her temperature is 37.8 C (100 F) and pulse is 112/min. Abdominal examination shows cessation of inspiration with deep palpation of the right upper quadrant. Laboratory assessment shows a serum bilirubin of 0.8 mg/dL and a serum alkaline phosphatase of 100 U/L. Initial imaging studies are equivocal. Which of the following diagnostic test results would be most specific for acute cholecystitis?

A. Distended duodenum on upper gastrointestinal series

B. Echogenic structures inside the gallbladder on abdominal ultrasound

C. Failed gallbladder visualization on radionuclide biliary scan

D. Increased serum aspartate and alanine aminotransferase levels

E. Opacities in the right subcostal area on abdominal x-ray

Submit

1
2
3
4
5
6
7
8
9
10
11
12
13
14
15
16
17
18
19
20
21
22
23
24
25
26
27
28
29
30
31

A 50-year-old woman comes to the emergency department with severe upper abdominal pain. The pain started suddenly and is sharp and colicky. She has also vomited several times throughout the day, including once while in the emergency department. The patient describes several prior episodes of similar abdominal pain that resolved spontaneously without treatment. Her other medical problems include complicated appendicitis when she was 22 years old. Her temperature is 37.8 C (100 F) and pulse is 112/min. Abdominal examination shows cessation of inspiration with deep palpation of the right upper quadrant. Laboratory assessment shows a serum bilirubin of 0.8 mg/dL and a serum alkaline phosphatase of 100 U/L. Initial imaging studies are equivocal. Which of the following diagnostic test results would be most specific for acute cholecystitis?

A. Distended duodenum on upper gastrointestinal series (2%)

B. Echogenic structures inside the gallbladder on abdominal ultrasound (53%)

✓ C. Failed gallbladder visualization on radionuclide biliary scan (33%)

D. Increased serum aspartate and alanine aminotransferase levels (3%)

E. Opacities in the right subcostal area on abdominal x-ray (7%)

Omitted
Correct answer
C

33%
Answered correctly

02 secs
Time Spent

03/21/2020
Last Updated

Explanation

Acute cholecystitis is caused by gallstone obstruction of the **cystic duct** in more than 90% of cases. Ingestion of fatty foods then stimulates contraction of the gallbladder against the impacted stone, resulting in severe colicky pain. Mechanical disruption of the gallbladder mucosa and release of inflammatory mediators (eg, lysolecithin, prostaglandins) cause the obstructed gallbladder to become inflamed and edematous. As

1
2
3
4
5
6
7
8
9
10
11
12
13
14
15
16
17
18
19
20
21
22
23
24
25
26
27
28
29
30
31

Acute cholecystitis is caused by gallstone obstruction of the **cystic duct** in more than 90% of cases. Ingestion of fatty foods then stimulates contraction of the gallbladder against the impacted stone, resulting in severe colicky pain. Mechanical disruption of the gallbladder mucosa and release of inflammatory mediators (eg, lysolecithin, prostaglandins) cause the obstructed gallbladder to become inflamed and edematous. As blood supply to the distended organ becomes compromised, secondary bacterial infection frequently develops. Potential complications include gangrene and perforation, with subsequent formation of a pericholecystic abscess or generalized peritonitis.

Ultrasonography is the **preferred** initial imaging test for the diagnosis of acute cholecystitis; however, nuclear medicine hepatobiliary scanning (ie, cholescintigraphy) can be an alternate means when ultrasonography is **inconclusive**. During a hepatobiliary scan, a radiotracer is administered intravenously and is preferentially taken up by hepatocytes and excreted into bile. Images of the tracer as it moves through the hepatobiliary system and intestine are then obtained for up to several hours after injection.

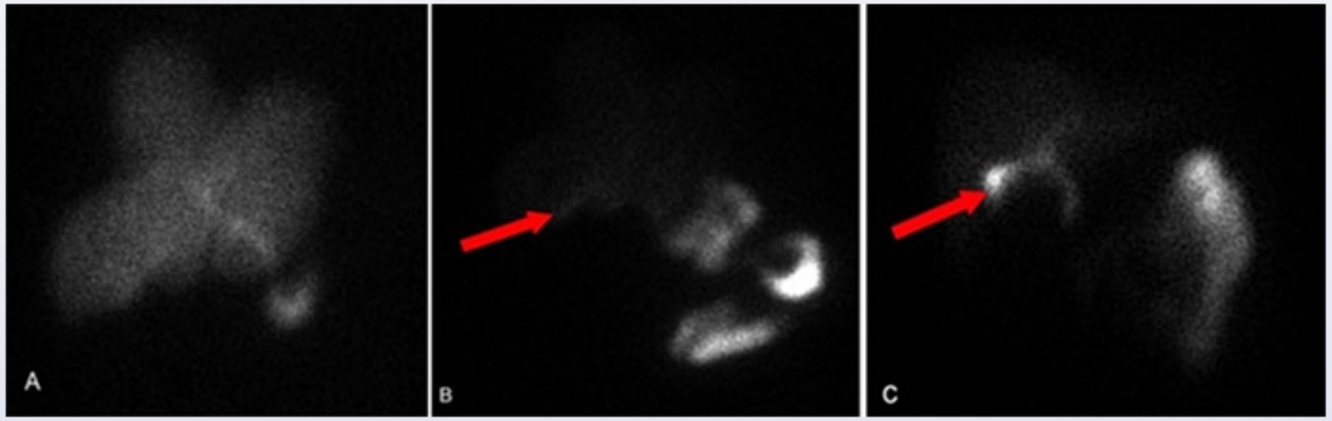

In patients with a patent cystic duct, the gallbladder will be seen as the radiotracer accumulates and concentrates within (image C). In acute or chronic cholecystitis, the radiotracer will be taken up by the liver with progressive excretion into the common bile duct and proximal small bowel, but the **gallbladder will not be visualized** due to the obstruction (image A and B).

(Choice A) Distended duodenum on an upper gastrointestinal series would be suggestive of small-bowel obstruction (as seen with gallstone ileus).

(Choice B) The presence of echogenic structures within the gallbladder on ultrasound can be suggestive of acute cholecystitis in the setting of fever and abdominal pain, but it is not diagnostic. Cholelithiasis can also cause more benign biliary colic, or be an incidental asymptomatic finding

In patients with a patent cystic duct, the gallbladder will be seen as the radiotracer accumulates and concentrates within (image C). In acute or chronic cholecystitis, the radiotracer will be taken up by the liver with progressive excretion into the common bile duct and proximal small bowel, but the **gallbladder will not be visualized** due to the obstruction (image A and B).

(Choice A) Distended duodenum on an upper gastrointestinal series would be suggestive of small-bowel obstruction (as seen with gallstone ileus).

(Choice B) The presence of echogenic structures within the gallbladder on ultrasound can be suggestive of acute cholecystitis in the setting of fever and abdominal pain, but it is not diagnostic. Cholelithiasis can also cause more benign biliary colic, or be an incidental asymptomatic finding in the setting of other abdominal pathology. Ultrasound findings more specific for acute cholecystitis include gallbladder wall thickening, pericholecystic fluid, and a positive sonographic Murphy sign.

(Choice D) Mild increases in serum aspartate and alanine aminotransferase levels can occur in acute cholecystitis, but they are nonspecific and do not aid the diagnosis.

(Choice E) Most patients have insufficient calcium in their gallstones to be visualized on an abdominal x-ray.

Educational objective:
Acute cholecystitis is most often caused by gallstones obstructing the cystic duct. The diagnosis can be made by identifying signs of gallbladder inflammation (eg, wall thickening, pericholecystic fluid) on ultrasonography. When ultrasound is inconclusive, nuclear medicine hepatobiliary scanning (ie, cholescintigraphy) can be used to assess cystic duct patency and make the diagnosis.

References

- A systematic review and meta-analysis of diagnostic performance of imaging in acute cholecystitis.
- Abdominal ultrasound versus hepato-imino diacetic acid scan in diagnosing acute cholecystitis – what is the real benefit?

Pathophysiology	Gastrointestinal & Nutrition	Cholecystitis
Subject	System	Topic

Copyright © UWorld. All rights reserved.

1
2
3
4
5
6
7
8
9
10
11
12
13
14
15
16
17
18
19
20
21
22
23
24
25
26
27
28
29
30
31

A 63-year-old man comes to the office due to intermittent rectal bleeding. The bleeding worsens with defecation and is associated with itchiness. Ten years ago, he had a kidney transplant for diabetic nephropathy and reports compliance with posttransplant immunosuppression medications. Vital signs are normal. Physical examination reveals a 2-cm ulcerated mass extending from the anal verge into the rectum. Biopsy shows large, eosinophilic squamous epithelial cells arranged in islands; cells have hyperchromatic, irregular nuclei, and scant cytoplasm. Significant keratinization is present. Which of the following factors is most likely responsible for the development of this patient's anal lesion?

A. *BRAF* mutation

B. Human herpesvirus 8

C. Human papillomavirus

D. Mismatch repair gene mutation

E. Poxvirus

F. *Treponema pallidum*

Submit

1
2
3
4
5
6
7
8
9
10
11
12
13
14
15
16
17
18
19
20
21
22
23
24
25
26
27
28
29
30
31

A 63-year-old man comes to the office due to intermittent rectal bleeding. The bleeding worsens with defecation and is associated with itchiness. Ten years ago, he had a kidney transplant for diabetic nephropathy and reports compliance with posttransplant immunosuppression medications. Vital signs are normal. Physical examination reveals a 2-cm ulcerated mass extending from the anal verge into the rectum. Biopsy shows large, eosinophilic squamous epithelial cells arranged in islands; cells have hyperchromatic, irregular nuclei, and scant cytoplasm. Significant keratinization is present. Which of the following factors is most likely responsible for the development of this patient's anal lesion?

- A. *BRAF* mutation (5%)
- B. Human herpesvirus 8 (6%)
- ✓ C. Human papillomavirus (82%)
- D. Mismatch repair gene mutation (4%)
- E. Poxvirus (0%)
- F. *Treponema pallidum* (0%)

Omitted
Correct answer
C

82%
Answered correctly

02 secs
Time Spent

05/07/2020
Last Updated

Explanation

Anal squamous cell carcinoma	
	• Human papillomavirus (types 16 & 18) • Receptive anal intercourse

Anal squamous cell carcinoma	
Risk factors	• Human papillomavirus (types 16 & 18) • Receptive anal intercourse • Immunocompromised state (eg, HIV, organ transplant) • Female sex • Smoking
Manifestations	• Rectal bleeding/pain, pruritus, mass sensation • Ulcerated or nodular anal mass
Histology	• Islands of large, eosinophilic, hyperchromatic squamous cells with scant cytoplasm & nuclear atypia • Prominent keratinization &/or keratin pearls

This patient with a history of chronic immunosuppression has perianal bleeding and an ulcerated anal mass. In association with the classic histologic findings, this presentation suggests **anal squamous cell carcinoma** (SCC). Most patients have **rectal bleeding**, pain, or pruritus, and examination demonstrates an **ulcerated** or a nodular, exophytic anal lesion. On histology, SCCs are characterized by **large, eosinophilic, hyperchromatic squamous cells** with scant cytoplasm arranged in islands. Nuclear atypia and prominent **keratinization** and/or keratin pearls are usually observed.

Anal SCC, as well as multiple other anogenital (eg, cervical, penile, vaginal) and oropharyngeal SCCs, is strongly associated with **human papillomavirus** (HPV). HPV is a nonenveloped, double-stranded DNA virus that infects cutaneous and mucosal tissues. HPV types 16 and 18 are particularly associated with the development of malignancies. Immunocompromised states (eg, HIV, **organ transplant**) increase susceptibility to HPV infection and malignant transformation. Other risk factors include smoking, receptive anal intercourse, and female sex.

(Choice A) *BRAF* is a protoonocogene, and mutations are associated with multiple malignancies (eg, melanoma, colon cancer, papillary thyroid cancer) but are not typically associated with anal SCC.

(Choice B) Human herpesvirus 8 causes Kaposi sarcoma, an angiogenic tumor that typically occurs in patients with severe immunosuppression (usually AIDS) but can occur in organ transplant recipients. However, it typically involves the extremities, face, or genitalia and results in painless

(Choice A) *BRAF* is a protoonocogene, and mutations are associated with multiple malignancies (eg, melanoma, colon cancer, papillary thyroid cancer) but are not typically associated with anal SCC.

(Choice B) Human herpesvirus 8 causes Kaposi sarcoma, an angiogenic tumor that typically occurs in patients with severe immunosuppression (usually AIDS) but can occur in organ transplant recipients. However, it typically involves the extremities, face, or genitalia and results in painless purple or brown lesions. Histologic evaluation demonstrates whorls of spindle cells and neovascularization.

(Choice D) Mutations of DNA mismatch repair genes are associated with hereditary nonpolyposis colon cancer (ie, Lynch syndrome), an autosomal dominant disease that results in colonic, endometrial, and ovarian cancer. It is not associated with anal SCC.

(Choice E) Poxvirus causes molluscum contagiosum, which is characterized by umbilicated, flesh-colored papules with histologic findings of epidermal hyperplasia and eosinophilic, intracytoplasmic viral inclusions. Although immunocompromised patients are at increased risk of larger lesions, molluscum contagiosum is not associated with malignant transformation.

(Choice F) Primary syphilis (caused by *Treponema pallidum*) can result in a painless, ulcerated anogenital lesion (eg, chancre); however, bleeding is atypical, and dark-field microscopy is used to reveal the presence of spirochetes.

Educational objective:
Anal squamous cell carcinoma is strongly associated with human papillomavirus and typically presents with rectal bleeding, pruritus, and/or pain; examination demonstrates an ulcerated or nodular, exophytic anal lesion. Histology reveals large, eosinophilic, hyperchromatic squamous cells arranged in islands with nuclear atypia and prominent keratinization.

References

- Pathology of anal cancer.
- Recent advances in the management of anal cancer.

Pathophysiology	Gastrointestinal & Nutrition	Anal cancer
Subject	System	Topic

Copyright © UWorld. All rights reserved.

1
2
3
4
5
6
7
8
9
10
11
12
13
14
15
16
17
18
19
20
21
22
23
24
25
26
27
28
29
30
31

A 15-year-old girl is hospitalized due to confusion and hematemesis for 2 days. Medical history is notable for depression over the past year. Temperature is 37.2 C (99 F), blood pressure is 86/56 mm Hg, pulse is 112/min, and respirations are 20/min; BMI is 23 kg/m^2. She is oriented to person but disoriented to time and place. The patient quickly deteriorates and dies during hospitalization. Autopsy examination reveals a nodular liver, esophageal varices, splenomegaly, and atrophy of the basal ganglia with increased copper content. The most likely cause of this patient's condition is an abnormality in which of the following physiologic processes?

A. Biliary excretion

B. Immunoglobulin production

C. Intestinal absorption

D. Lipid metabolism

E. Renal tubular reabsorption

Submit

1
2
3
4
5
6
7
8
9
10
11
12
13
14
15
16
17
18
19
20
21
22
23
24
25
26
27
28
29
30
31

A 15-year-old girl is hospitalized due to confusion and hematemesis for 2 days. Medical history is notable for depression over the past year. Temperature is 37.2 C (99 F), blood pressure is 86/56 mm Hg, pulse is 112/min, and respirations are 20/min; BMI is 23 kg/m^2. She is oriented to person but disoriented to time and place. The patient quickly deteriorates and dies during hospitalization. Autopsy examination reveals a nodular liver, esophageal varices, splenomegaly, and atrophy of the basal ganglia with increased copper content. The most likely cause of this patient's condition is an abnormality in which of the following physiologic processes?

- A. Biliary excretion (57%)
- B. Immunoglobulin production (1%)
- C. Intestinal absorption (33%)
- D. Lipid metabolism (3%)
- E. Renal tubular reabsorption (3%)

Omitted
Correct answer
A

57%
Answered correctly

02 secs
Time Spent

06/29/2020
Last Updated

Explanation

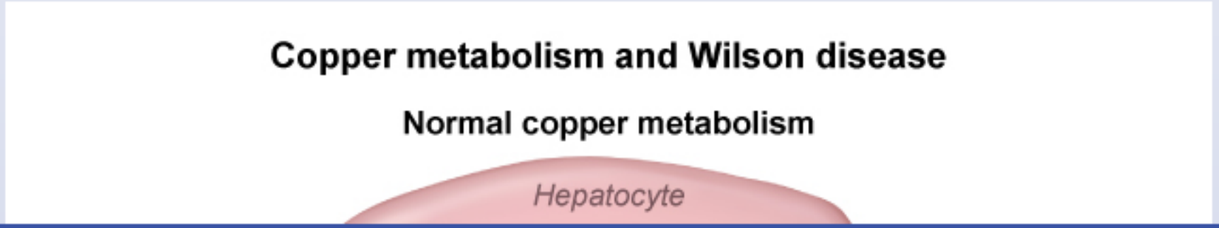

1
2
3
4
5
6
7
8
9
10
11
12
13
14
15
16
17
18
19
20
21
22
23
24
25
26
27
28
29
30
31

Copper metabolism and Wilson disease

Normal copper metabolism

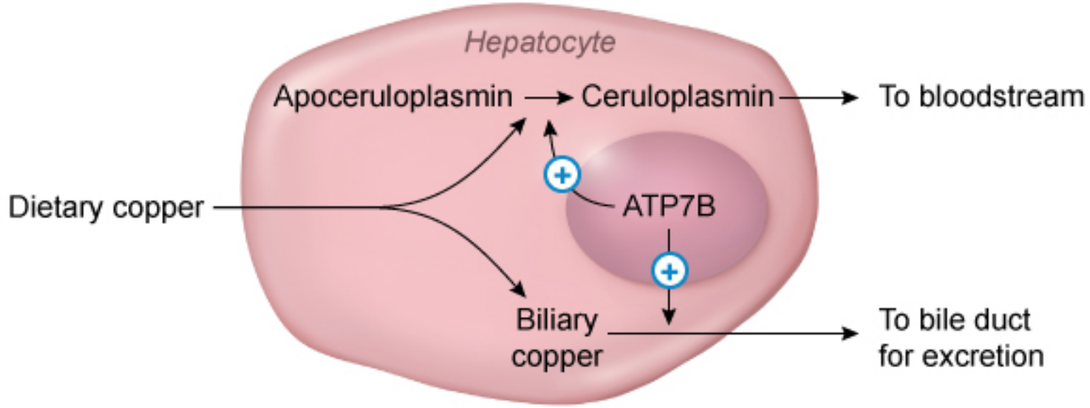

Impaired copper metabolism in Wilson disease

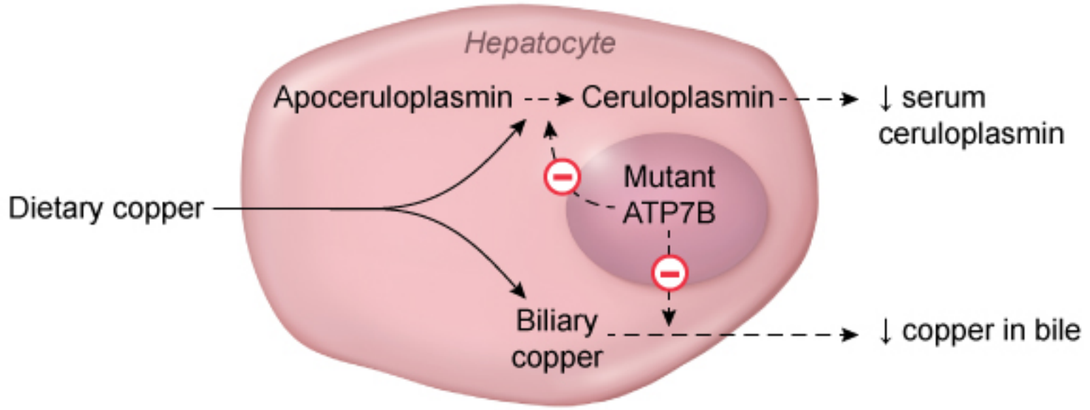

↑ hepatocellular copper
↓
Oxidative stress, necrosis & apoptosis

1
2
3
4
5
6
7
8
9
10
11
12
13
14
15
16
17
18
19
20
21
22
23
24
25
26
27
28
29
30
31

Impaired copper metabolism in Wilson disease

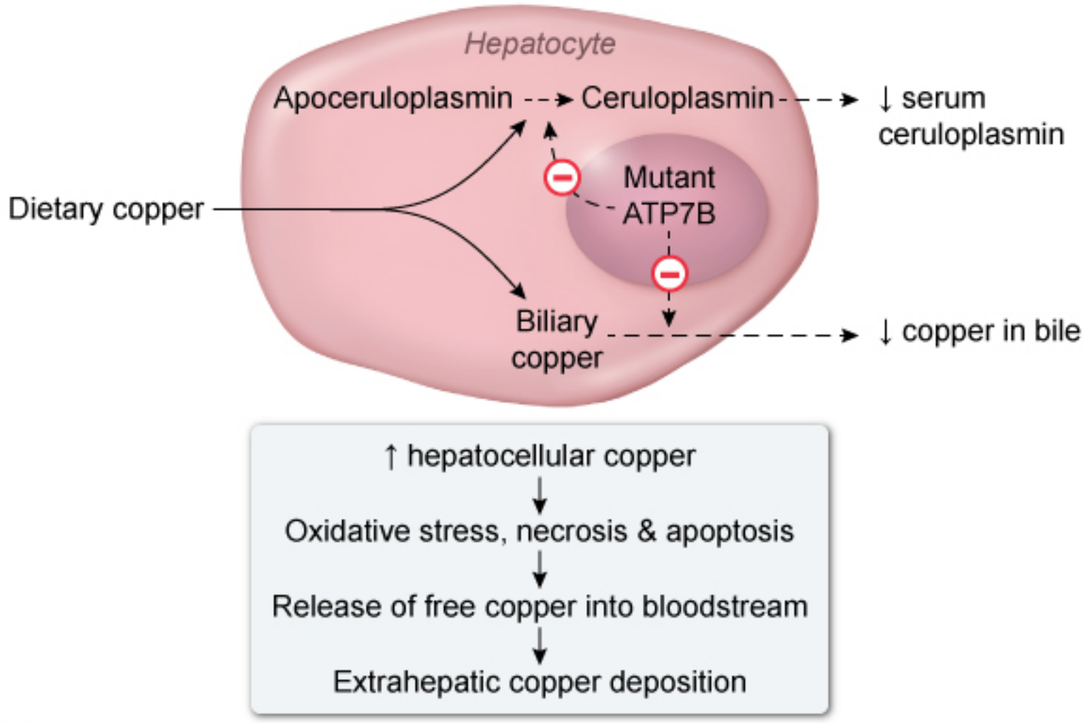

©UWorld

This patient has evidence of **cirrhosis** (eg, nodular liver, splenomegaly, esophageal varices) with **acute liver failure** (ie, encephalopathy) in addition to copper deposition in the basal ganglia. These findings are consistent with **Wilson disease**, an autosomal recessive disorder characterized by accumulation of copper due to a **defective copper transport protein**, ATP7B.

In general, dietary copper is absorbed in the stomach and duodenum and bound to circulating albumin. It is then transported to the liver and taken up by hepatocytes. Excessive intracellular copper levels normally cause ATP7B to transfer the excess copper into the bile canaliculi. This process is essential for biliary excretion of copper, which accounts for the majority of total body copper excretion.

In Wilson disease, defective ATP7B results in **impaired biliary excretion** of copper. The **accumulation** of **hepatocellular copper** results in oxidative stress and apoptosis. Upon cell death, free copper is released into the bloodstream and **deposited into extrahepatic tissues** (eg

1
2
3
4
5
6
7
8
9
10
11
12
13
14
15
16
17
18
19
20
21
22
23
24
25
26
27
28
29
30
31

This patient has evidence of **cirrhosis** (eg, nodular liver, splenomegaly, esophageal varices) with **acute liver failure** (ie, encephalopathy) in addition to copper deposition in the basal ganglia. These findings are consistent with **Wilson disease**, an autosomal recessive disorder characterized by accumulation of copper due to a **defective copper transport protein**, ATP7B.

In general, dietary copper is absorbed in the stomach and duodenum and bound to circulating albumin. It is then transported to the liver and taken up by hepatocytes. Excessive intracellular copper levels normally cause ATP7B to transfer the excess copper into the bile canaliculi. This process is essential for biliary excretion of copper, which accounts for the majority of total body copper excretion.

In Wilson disease, defective ATP7B results in **impaired biliary excretion** of copper. The **accumulation** of **hepatocellular copper** results in oxidative stress and apoptosis. Upon cell death, free copper is released into the bloodstream and **deposited into extrahepatic tissues** (eg, basal ganglia, cornea), causing the classic triad of hepatic, neurologic, and psychiatric (eg, depression) symptoms.

ATP7B is also required for the hepatic production of ceruloplasmin, which is apoceruloplasmin bound to copper. The inability to create and secrete ceruloplasmin in Wilson disease results in low serum ceruloplasmin. This abnormality does not account for the clinical manifestations of Wilson disease but is an important diagnostic finding.

(Choice B) Autoimmune hepatitis due to production of autoantibodies can cause cirrhosis and acute liver failure but not copper accumulation.

(Choice C) Hereditary hemochromatosis is an autosomal recessive disorder that can cause cirrhosis due to increased intestinal absorption of iron, not copper.

(Choice D) Niemann-Pick disease and Gaucher disease are lipid storage disorders that cause hepatosplenomegaly. Symptoms usually present in early childhood, and copper deposition is not seen in either condition.

(Choice E) Renal copper deposition in Wilson disease can cause Fanconi syndrome (eg, proximal tubular dysfunction). However, this occurs as a result of impaired biliary excretion of copper; it is not the cause of copper accumulation in Wilson disease.

Educational objective:
Wilson disease is caused by defective copper transport within hepatocytes, which leads to impaired biliary excretion of copper. Hepatic copper accumulation eventually results in the release of free copper into the bloodstream and copper deposition into extrahepatic tissues (eg, basal ganglia, cornea).

References

In Wilson disease, defective ATP7B results in **impaired biliary excretion** of copper. The **accumulation** of **hepatocellular copper** results in oxidative stress and apoptosis. Upon cell death, free copper is released into the bloodstream and **deposited into extrahepatic tissues** (eg, basal ganglia, cornea), causing the classic triad of hepatic, neurologic, and psychiatric (eg, depression) symptoms.

ATP7B is also required for the hepatic production of ceruloplasmin, which is apoceruloplasmin bound to copper. The inability to create and secrete ceruloplasmin in Wilson disease results in low serum ceruloplasmin. This abnormality does not account for the clinical manifestations of Wilson disease but is an important diagnostic finding.

(Choice B) Autoimmune hepatitis due to production of autoantibodies can cause cirrhosis and acute liver failure but not copper accumulation.

(Choice C) Hereditary hemochromatosis is an autosomal recessive disorder that can cause cirrhosis due to increased intestinal absorption of iron, not copper.

(Choice D) Niemann-Pick disease and Gaucher disease are lipid storage disorders that cause hepatosplenomegaly. Symptoms usually present in early childhood, and copper deposition is not seen in either condition.

(Choice E) Renal copper deposition in Wilson disease can cause Fanconi syndrome (eg, proximal tubular dysfunction). However, this occurs as a result of impaired biliary excretion of copper; it is not the cause of copper accumulation in Wilson disease.

Educational objective:
Wilson disease is caused by defective copper transport within hepatocytes, which leads to impaired biliary excretion of copper. Hepatic copper accumulation eventually results in the release of free copper into the bloodstream and copper deposition into extrahepatic tissues (eg, basal ganglia, cornea).

References

- Wilson disease.

Pathophysiology	Gastrointestinal & Nutrition	Wilson disease
Subject	System	Topic

Copyright © UWorld. All rights reserved.

drugs. Complete blood count is within normal limits. Liver function studies are as follows:

Total protein	6.5 g/dL
Albumin	4 g/dL
Total bilirubin	2.8 mg/dL
Direct bilirubin	2.0 mg/dL
Alkaline phosphatase	90 U/L
Aspartate aminotransferase	28 U/L
Alanine aminotransferase	30 U/L

Liver biopsy shows abundant pigment inclusions in the lysosomes of the otherwise normal hepatocytes. Electron spin resonance spectroscopy reveals that the pigment is composed of polymers of epinephrine metabolites. Which of the following is the most likely cause of this patient's jaundice?

A. Defective hepatocellular excretion of bilirubin glucuronides
B. Impaired conjugation of bilirubin
C. Increased production of catecholamines
D. Ineffective intramedullary erythropoiesis
E. Low serum ceruloplasmin

Submit

1
2
3
4
5
6
7
8
9
10
11
12
13
14
15
16
17
18
19
20
21
22
23
24
25
26
27
28
29
30
31

A 20-year-old man is evaluated in the clinic due to intermittent episodes of self-resolving jaundice. His symptoms are not provoked by any particular circumstances or events. The patient otherwise feels healthy and has no other symptoms. He does not use tobacco, alcohol, or illicit drugs. Complete blood count is within normal limits. Liver function studies are as follows:

Total protein	6.5 g/dL
Albumin	4 g/dL
Total bilirubin	2.8 mg/dL
Direct bilirubin	2.0 mg/dL
Alkaline phosphatase	90 U/L
Aspartate aminotransferase	28 U/L
Alanine aminotransferase	30 U/L

Liver biopsy shows abundant pigment inclusions in the lysosomes of the otherwise normal hepatocytes. Electron spin resonance spectroscopy reveals that the pigment is composed of polymers of epinephrine metabolites. Which of the following is the most likely cause of this patient's jaundice?

A. Defective hepatocellular excretion of bilirubin glucuronides
B. Impaired conjugation of bilirubin
C. Increased production of catecholamines
D. Ineffective intramedullary erythropoiesis
E. Low serum ceruloplasmin

1
2
3
4
5
6
7
8
9
10
11
12
13
14
15
16
17
18
19
20
21
22
23
24
25
26
27
28
29
30
31

particular circumstances or events. The patient otherwise feels healthy and has no other symptoms. He does not use tobacco, alcohol, or illicit drugs. Complete blood count is within normal limits. Liver function studies are as follows:

Total protein	6.5 g/dL
Albumin	4 g/dL
Total bilirubin	2.8 mg/dL
Direct bilirubin	2.0 mg/dL
Alkaline phosphatase	90 U/L
Aspartate aminotransferase	28 U/L
Alanine aminotransferase	30 U/L

Liver biopsy shows abundant pigment inclusions in the lysosomes of the otherwise normal hepatocytes. Electron spin resonance spectroscopy reveals that the pigment is composed of polymers of epinephrine metabolites. Which of the following is the most likely cause of this patient's jaundice?

- ✓ A. Defective hepatocellular excretion of bilirubin glucuronides (61%)
- B. Impaired conjugation of bilirubin (13%)
- C. Increased production of catecholamines (17%)
- D. Ineffective intramedullary erythropoiesis (1%)
- E. Low serum ceruloplasmin (4%)

Omitted 61% 06 secs 02/18/2020

1
2
3
4
5
6
7
8
9
10
11
12
13
14
15
16
17
18
19
20
21
22
23
24
25
26
27
28
29
30
31

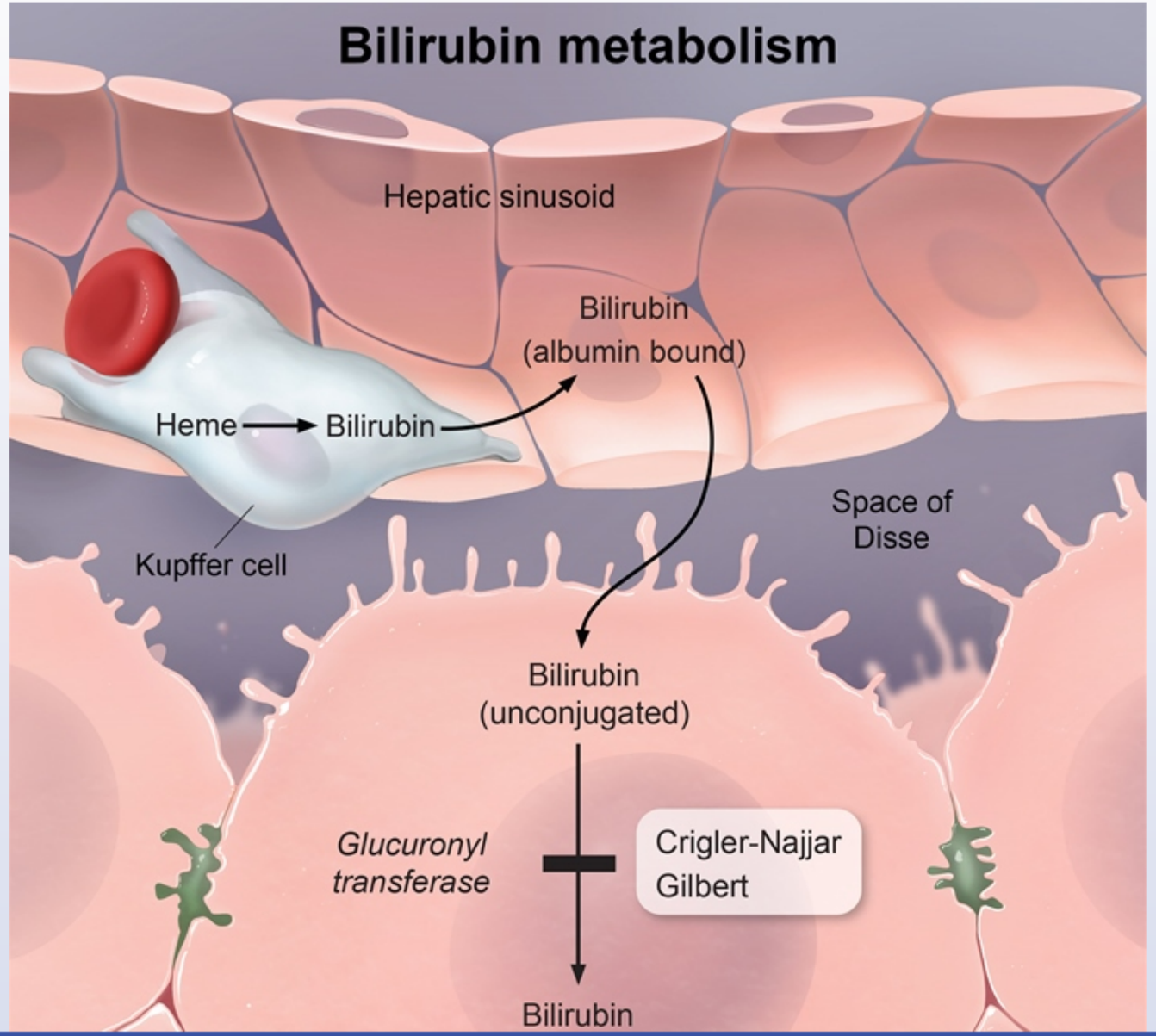

1
2
3
4
5
6
7
8
9
10
11
12
13
14
15
16
17
18
19
20
21
22
23
24
25
26
27
28
29
30
31

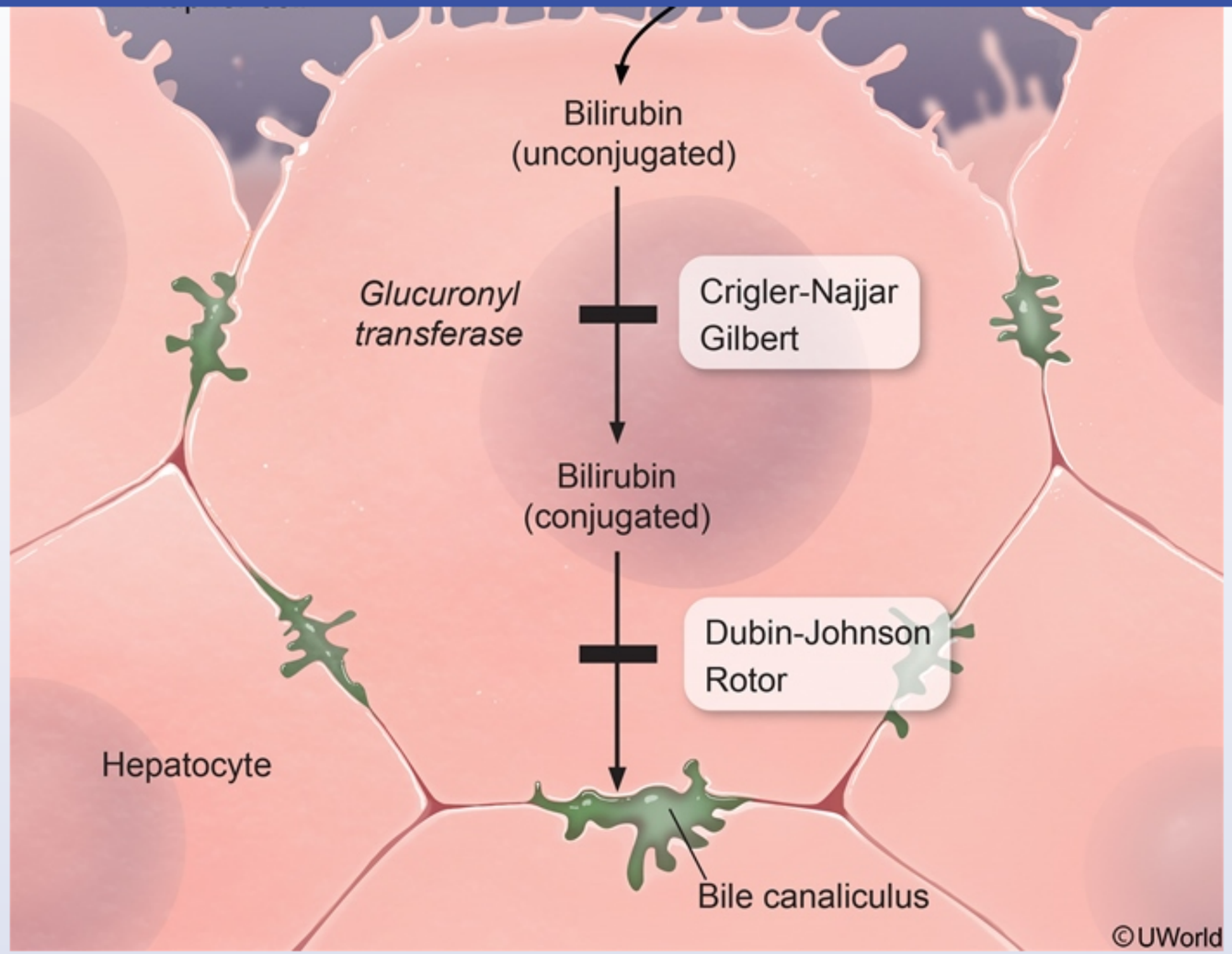

Dubin-Johnson syndrome is a benign autosomal recessive disorder characterized by defective hepatic **excretion of bilirubin glucuronides** due to a mutation in the canalicular membrane transport protein. Individuals with this condition can develop episodes of **jaundice**, which may only become evident in the context of a trigger (eg, illness, pregnancy, oral contraceptive use). Otherwise, they are usually asymptomatic with a normal physical examination.

1
2
3
4
5
6
7
8
9
10
11
12
13
14
15
16
17
18
19
20
21
22
23
24
25
26
27
28
29
30
31

become evident in the context of a trigger (eg, illness, pregnancy, oral contraceptive use). Otherwise, they are usually asymptomatic with a normal physical examination.

Impaired bilirubin excretion may result in **direct (conjugated) hyperbilirubinemia** (eg, usually 2-5 mg/dL), but other routine laboratory tests (eg, complete blood count, liver function studies) are typically normal. Grossly, the liver appears black due to impaired excretion of epinephrine metabolites that accumulate within lysosomes.

(Choice B) Impaired bilirubin conjugation is seen in conditions such as Crigler-Najjar syndrome and Gilbert syndrome and results in indirect (unconjugated) hyperbilirubinemia.

(Choice C) Increased production of catecholamines is not associated with Dubin-Johnson syndrome despite the hepatocyte accumulation of epinephrine metabolites in this condition. Pheochromocytomas are catecholamine-secreting tumors of the adrenal medulla.

(Choice D) Ineffective intramedullary erythropoiesis is seen in conditions such as beta-thalassemia and myelodysplasia, and can result in indirect hyperbilirubinemia.

(Choice E) Low levels of serum ceruloplasmin are seen in Wilson disease, which is typically associated with liver (eg, hepatitis, cirrhosis), psychiatric (eg, depression, personality changes), and neurologic (eg, dysarthria, movement disorder) abnormalities.

Educational objective:
Dubin-Johnson syndrome is a benign disorder characterized by defective hepatic excretion of bilirubin glucuronides across the canalicular membrane, resulting in direct hyperbilirubinemia and jaundice. Grossly, the liver appears black due to impaired excretion of epinephrine metabolites, which histologically appear as dense pigments within lysosomes.

References

- Hyperbilirubinemia syndromes (Gilbert-Meulengracht, Crigler-Najjar, Dubin-Johnson, and Rotor syndrome).
- Inherited disorders of bilirubin transport and conjugation: new insights into molecular mechanisms and consequences.
- Dubin-Johnson syndrome.

Pathophysiology	Gastrointestinal & Nutrition	Hereditary hyperbilirubinemia
Subject	System	Topic

1
2
3
4
5
6
7
8
9
10
11
12
13
14
15
16
17
18
19
20
21
22
23
24
25
26
27
28
29
30
31

A 55-year-old man with a history of chronic pancreatitis and alcohol abuse is investigated for recent onset weight loss, decreased appetite, and worsening of chronic abdominal pain. Physical examination is significant for diffuse muscle atrophy, temporal wasting, and a mildly enlarged liver without ascites. Serum lipase and amylase are normal, and aspartate aminotransferase (AST) is mildly elevated. Abdominal imaging shows a malignant mass in the pancreas. The patient subsequently undergoes an uncomplicated subtotal pancreatectomy and returns for a postoperative nutritional assessment following hospital discharge. Which of the following tests will most likely be normal in this patient after surgery?

A. Duodenal lipase levels after cholecystokinin stimulation

B. Duodenal trypsin levels after cholecystokinin stimulation

C. Intestinal D-xylose absorption

D. Serum trypsinogen

E. Stool neutral fat content

Submit

A 55-year-old man with a history of chronic pancreatitis and alcohol abuse is investigated for recent onset weight loss, decreased appetite, and worsening of chronic abdominal pain. Physical examination is significant for diffuse muscle atrophy, temporal wasting, and a mildly enlarged liver without ascites. Serum lipase and amylase are normal, and aspartate aminotransferase (AST) is mildly elevated. Abdominal imaging shows a malignant mass in the pancreas. The patient subsequently undergoes an uncomplicated subtotal pancreatectomy and returns for a postoperative nutritional assessment following hospital discharge. Which of the following tests will most likely be normal in this patient after surgery?

- A. Duodenal lipase levels after cholecystokinin stimulation (6%)
- B. Duodenal trypsin levels after cholecystokinin stimulation (7%)
- ✓ C. Intestinal D-xylose absorption (68%)
- D. Serum trypsinogen (10%)
- E. Stool neutral fat content (6%)

Omitted
Correct answer
C

68%
Answered correctly

02 secs
Time Spent

05/29/2020
Last Updated

Explanation

The exocrine pancreas has a significant **secretory reserve**, and ≥90% of the glandular tissue must be destroyed before a patient will develop clinical malabsorption. However, this patient likely has significant loss of pancreatic tissue at baseline due to chronic pancreatitis and is at increased risk for **exocrine insufficiency**. Following partial pancreatic resection, he may develop clinically significant deficiency in any of the pancreatic digestive enzymes normally secreted into the duodenum.

Pancreatic amylases, along with salivary and brush border amylases, are required for the degradation of polysaccharides into monosaccharides,

The exocrine pancreas has a significant **secretory reserve**, and ≥90% of the glandular tissue must be destroyed before a patient will develop clinical malabsorption. However, this patient likely has significant loss of pancreatic tissue at baseline due to chronic pancreatitis and is at increased risk for **exocrine insufficiency**. Following partial pancreatic resection, he may develop clinically significant deficiency in any of the pancreatic digestive enzymes normally secreted into the duodenum.

Pancreatic amylases, along with salivary and brush border amylases, are required for the degradation of polysaccharides into monosaccharides, as polysaccharides cannot be absorbed by the intestinal mucosa. In contrast, **monosaccharides** (eg, glucose, galactose) are taken up directly by the epithelial cells of the small intestine through either sodium-dependent cotransport or facilitated diffusion. **D-xylose** is a monosaccharide that is absorbed directly without the action of pancreatic enzymes, and can be used to test for brush border absorptive function independent of pancreatic function. Intestinal D-xylose absorption can also decrease with bacterial overgrowth of the small intestine.

(Choices A and B) Patients with exocrine pancreatic insufficiency will have decreased secretion of trypsin and lipase into the duodenum following cholecystokinin (CCK) stimulation.

(Choice D) Trypsinogen is a proenzyme secreted by the exocrine pancreas into the small intestine. Small quantities are also detectable in serum. Serum trypsinogen levels are increased in acute pancreatitis but often decreased in patients with chronic pancreatitis or other forms of chronic pancreatic insufficiency.

(Choice E) The stool neutral fat (triglyceride) content is increased after pancreatic resection due to deficiency of pancreatic lipase.

Educational objective:
Polysaccharides must be degraded to monosaccharides by pancreatic and brush border amylases before they can be absorbed. Monosaccharides can be absorbed directly. D-xylose is a monosaccharide whose absorption is not affected by exocrine pancreatic insufficiency, and can be used to differentiate between pancreatic versus mucosal causes of malabsorption.

Pathophysiology	Gastrointestinal & Nutrition	Malabsorption
Subject	System	Topic

Copyright © UWorld. All rights reserved.

A 43-year-old man is evaluated for retrosternal discomfort and dysphagia for the past several months. He smokes a pack of cigarettes daily and drinks alcohol on weekends. His BMI is 32.8 kg/m^2. Physical examination is unremarkable. Esophageal manometry is performed; after a single swallow of 5 mL of water, the tracings appear as shown in the image below.

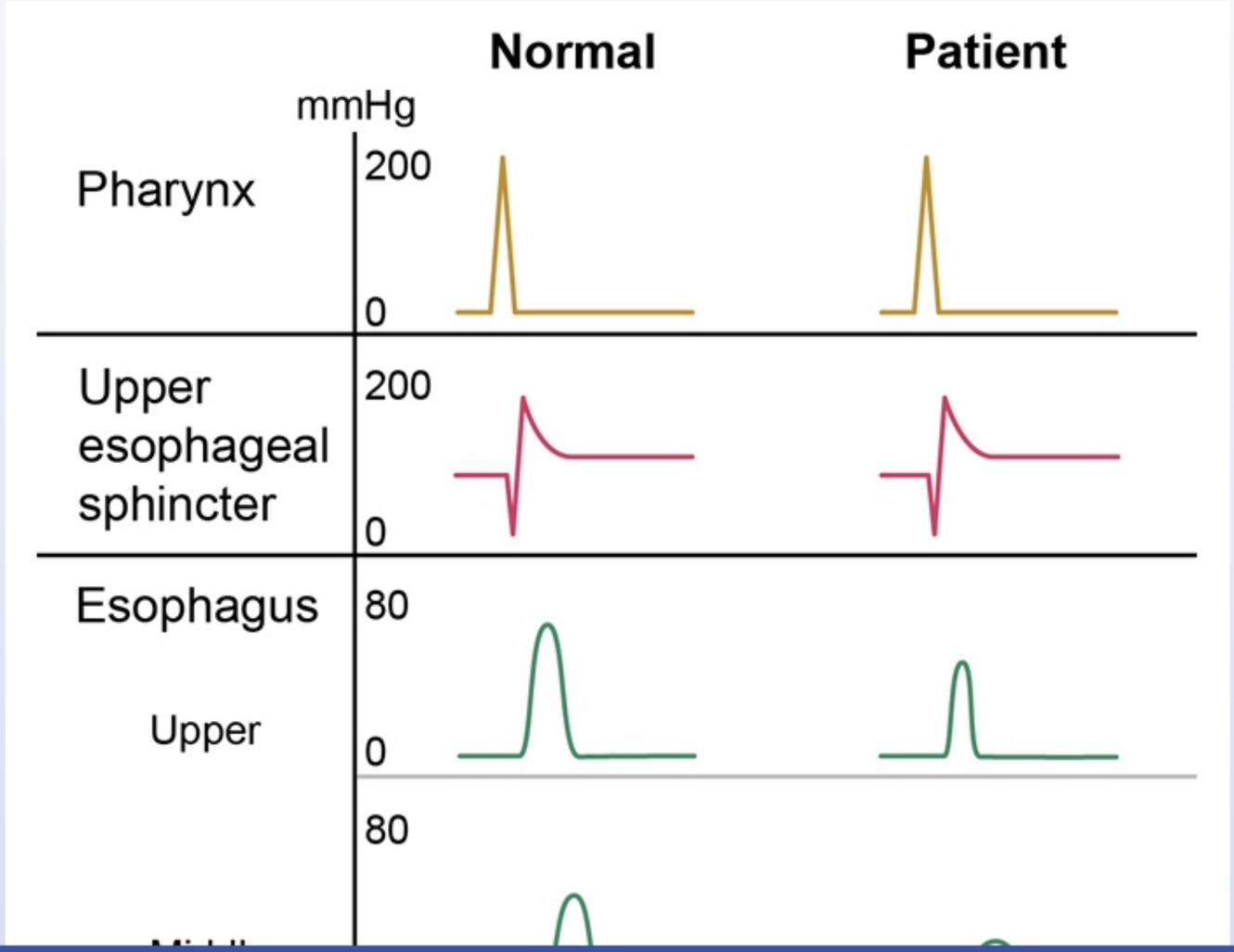

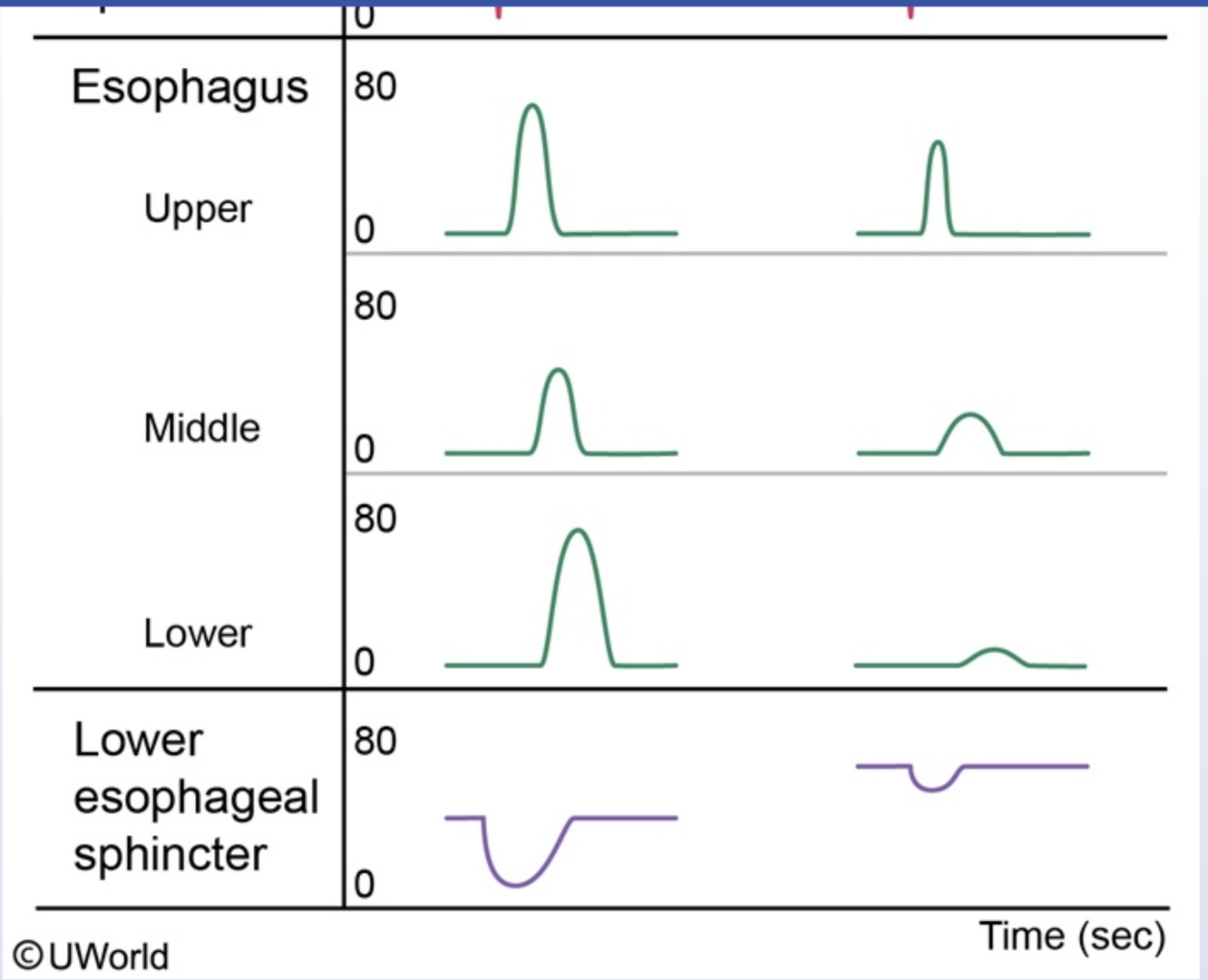

Which of the following is the most likely diagnosis in this patient?

A. Achalasia

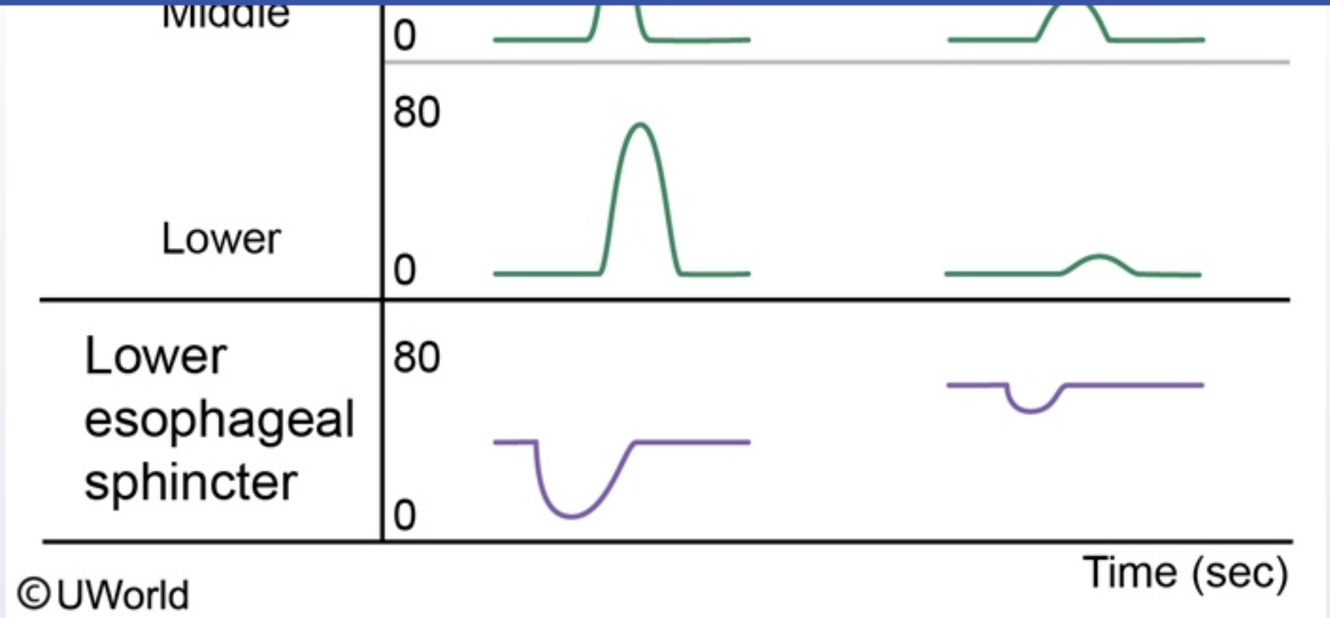

Which of the following is the most likely diagnosis in this patient?

- A. Achalasia
- B. Cricopharyngeal dysfunction
- C. Diffuse esophageal spasm
- D. Esophageal stricture
- E. Systemic sclerosis

Submit

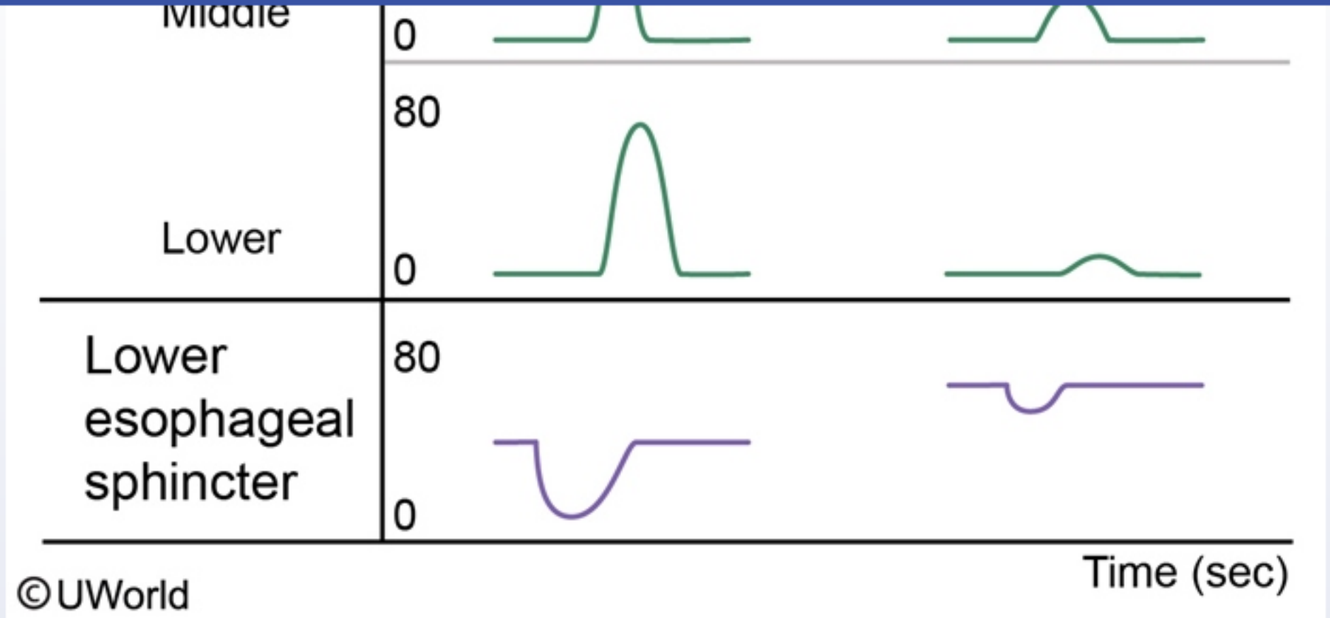

Which of the following is the most likely diagnosis in this patient?

- ✓ A. Achalasia (74%)
- B. Cricopharyngeal dysfunction (1%)
- C. Diffuse esophageal spasm (4%)
- D. Esophageal stricture (9%)
- E. Systemic sclerosis (9%)

Omitted
Correct answer

74%
Answered correctly

17 secs
Time Spent

02/23/2020
Last Updated

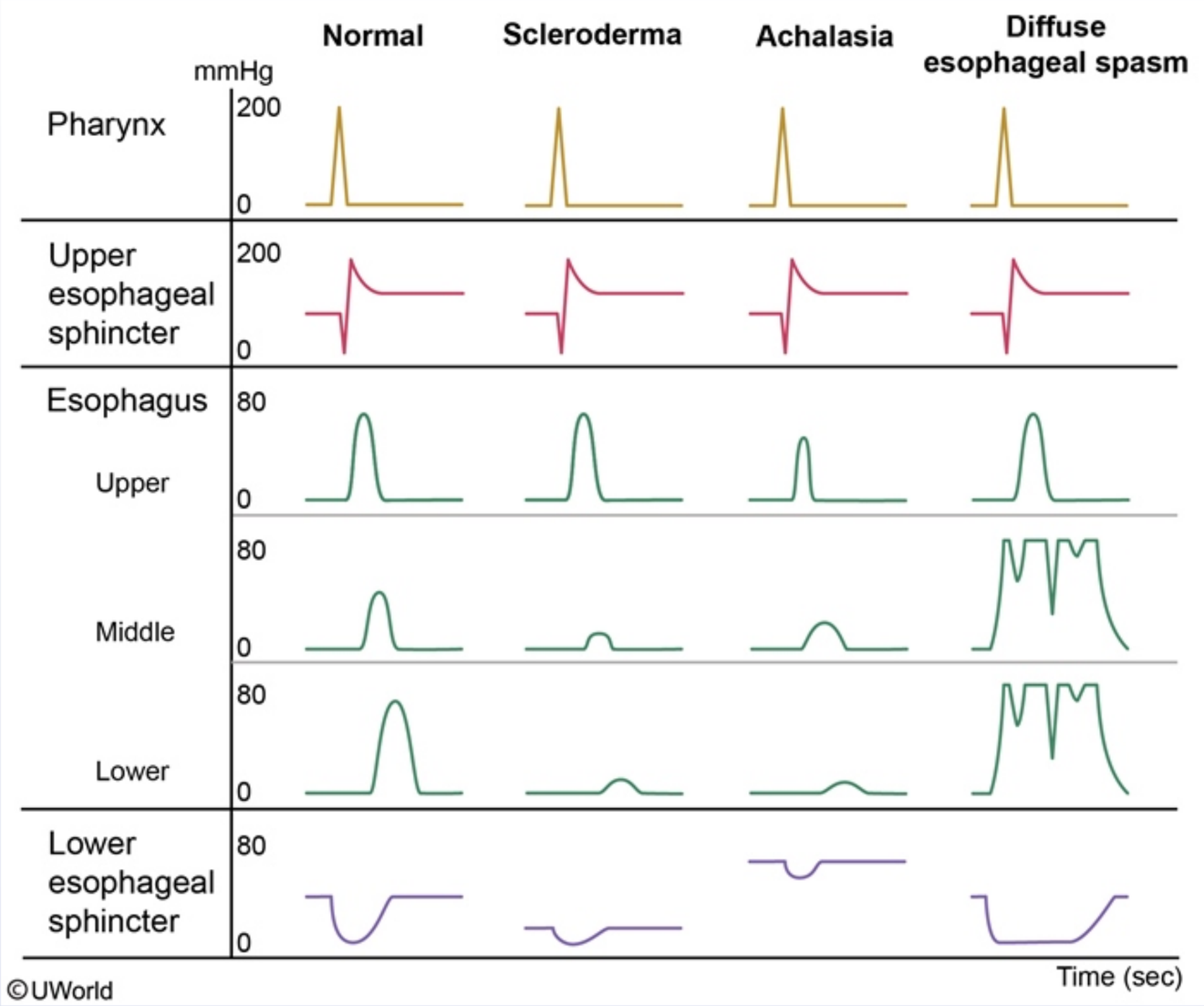

To initiate swallowing, the contents of the oral cavity are collected on the tongue and propelled into the pharynx, where contraction of the

©UWorld

To initiate swallowing, the contents of the oral cavity are collected on the tongue and propelled into the pharynx, where contraction of the pharyngeal muscles pushes the material into the esophagus. The cricopharyngeus muscle contracts behind the food bolus, initiating a peristaltic wave to propel the bolus downward. When the food bolus reaches the lower esophagus, the lower esophageal sphincter (LES) relaxes to allow the material to enter the stomach.

Achalasia is a motility disorder caused by reduced numbers of **inhibitory ganglion cells** in the esophageal wall, which creates an imbalance favoring excitatory ganglion cells. This patient's esophageal manometry shows typical findings in achalasia, including normal contraction of the upper esophageal sphincter, **decreased amplitude of peristalsis** in the mid esophagus, and increased tone and **incomplete relaxation** at the LES. Patients experience dysphagia, regurgitation, and retrosternal chest pain. Barium esophagram typically shows dilation of the esophagus with distal narrowing.

(Choice B) Cricopharyngeal dysfunction results from failure of the cricopharyngeus to relax during swallowing and causes a choking or "food-sticking" sensation on swallowing. Manometry findings are variable and can show decreased pharyngeal tone or incomplete relaxation at the upper esophageal sphincter.

(Choice C) Diffuse esophageal spasm presents with severe, retrosternal chest pain. It is characterized by uncoordinated contractions of the esophageal body. Esophageal manometry shows intermittent peristalsis and multiple simultaneous contractions on tracings from the mid and lower esophagus.

(Choice D) Esophageal stricture presents with progressive solid food dysphagia. It is diagnosed with contrast imaging (eg, barium swallow) rather than manometry. However, most patients will have a long history of gastroesophageal reflux with decreased tone at the LES.

(Choice E) Systemic sclerosis (scleroderma) can affect the esophagus, leading to impaired motility, incompetence of the LES, and gastroesophageal reflux. Manometry will show decreased peristalsis with decreased tone at the LES.

Educational objective:
Achalasia is caused by reduced numbers of inhibitory ganglion cells in the esophageal wall. Esophageal manometry in achalasia shows decreased amplitude of peristalsis in the mid esophagus, with increased tone and incomplete relaxation at the lower esophageal sphincter.

Pathophysiology Gastrointestinal & Nutrition Achalasia

©UWorld

Exhibit Display

Zoom In | Zoom Out | Reset | Add To New Card | Existing Card

Pathophysiology | Gastrointestinal & Nutrition | Achalasia

1
2
3
4
5
6
7
8
9
10
11
12
13
14
15
16
17
18
19
20
21
22
23
24
25
26
27
28
29
30
31

1
2
3
4
5
6
7
8
9
10
11
12
13
14
15
16
17
18
19
20
21
22
23
24
25
26
27
28
29
30
31

A one-month-old Caucasian male with a history of persistent jaundice experiences muscle rigidity, lethargy and seizures. Which of the following causes of hyperbilirubinemia is most likely to produce this patient's neurological abnormalities?

A. Absent liver conjugation enzymes

B. Deficient bilirubin excretion into bile canaliculi

C. Impaired canalicular bile transit

D. Increased gut deconjugation of bilirubin

E. Impaired gut reabsorption of bilirubin

Submit

A one-month-old Caucasian male with a history of persistent jaundice experiences muscle rigidity, lethargy and seizures. Which of the following causes of hyperbilirubinemia is most likely to produce this patient's neurological abnormalities?

- ✓ A. Absent liver conjugation enzymes (81%)
- B. Deficient bilirubin excretion into bile canaliculi (9%)
- C. Impaired canalicular bile transit (4%)
- D. Increased gut deconjugation of bilirubin (2%)
- E. Impaired gut reabsorption of bilirubin (2%)

Omitted
Correct answer
A

81%
Answered correctly

02 secs
Time Spent

02/03/2020
Last Updated

Explanation

The hepatic processing of bilirubin is accomplished in three key steps: 1) carrier-mediated uptake of bilirubin at the sinusoidal membrane; 2) conjugation of bilirubin with glucuronic acid by UGT (uridine diphosphate-glucuronyltransferase) in the endoplasmic reticulum; and 3) biliary excretion of the water-soluble, nontoxic bilirubin glucuronides. Disruption of this process can be fatal, as seen with Crigler-Najjar syndrome.

Crigler-Najjar syndrome type 1 is an autosomal recessive disorder of bilirubin metabolism caused by a genetic lack of the UGT enzyme needed to catalyze bile glucuronidation. When bilirubin is not correctly enzymatically processed by the liver, unconjugated hyperbilirubinemia develops. Indirect bilirubin levels typically approximate 20-25 mg/dL in these infants, but can rise to as high as 50 mg/dL.

Conjugated bilirubin is water soluble, loosely bound to albumin, and excreted in urine when present in excess. In contrast, unconjugated bilirubin

1
2
3
4
5
6
7
8
9
10
11
12
13
14
15
16
17
18
19
20
21
22
23
24
25
26
27
28
29
30
31

The hepatic processing of bilirubin is accomplished in three key steps: 1) carrier-mediated uptake of bilirubin at the sinusoidal membrane; 2) conjugation of bilirubin with glucuronic acid by UGT (uridine diphosphate-glucuronyltransferase) in the endoplasmic reticulum; and 3) biliary excretion of the water-soluble, nontoxic bilirubin glucuronides. Disruption of this process can be fatal, as seen with Crigler-Najjar syndrome.

Crigler-Najjar syndrome type 1 is an autosomal recessive disorder of bilirubin metabolism caused by a genetic lack of the UGT enzyme needed to catalyze bile glucuronidation. When bilirubin is not correctly enzymatically processed by the liver, unconjugated hyperbilirubinemia develops. Indirect bilirubin levels typically approximate 20-25 mg/dL in these infants, but can rise to as high as 50 mg/dL.

Conjugated bilirubin is water soluble, loosely bound to albumin, and excreted in urine when present in excess. In contrast, unconjugated bilirubin binds tightly to albumin and is highly insoluble in water. When bound, this unconjugated bilirubin cannot be filtered by the glomerulus and is therefore not excreted in the urine. Instead, the unconjugated bilirubin is gradually deposited into various tissues, including the brain. These deposits can cause kernicterus (bilirubin encephalopathy), which is a potentially fatal condition characterized by severe jaundice and neurologic impairment, as seen in this child.

(Choice B) Dubin-Johnson syndrome is an autosomal recessive disorder characterized by the absence of a biliary transport protein, MRP2 (multidrug resistance protein 2), used in the hepatocellular excretion of bilirubin glucuronides into bile canaliculi. The liver is darkly pigmented as a result, but patients are typically asymptomatic and suffer no significant adverse effects.

(Choice C) Rotor syndrome is a rare autosomal recessive disorder characterized by an asymptomatic conjugated hyperbilirubinemia that results from numerous defects in the hepatic uptake and excretion of bilirubin pigments. Although patients are often jaundiced, they enjoy normal life expectancies.

(Choice D) High numbers of anaerobes and *Staphylococcus aureus* can result in the deconjugation (via removal of glycine and taurine) of bile acids, rendering them less soluble and therefore less able to form micelles. This deconjugation impedes the active reabsorption of bile acids into portal circulation at the terminal ileum, resulting in lipid malabsorption. However, there are no neurologic abnormalities associated with bilirubin deconjugation in the gut.

(Choice E) Within the colon, bacterial enzymes reduce bilirubin into urobilinogens. A small fraction of these urobilinogens return to the liver through the enterohepatic circulation; these will later either re-enter the gastrointestinal tract or be excreted through the urine. The urobilinogens that remain in the colon are excreted in the feces as stercobilin, contributing to its dark color. Fortunately, there are no neurologic abnormalities

therefore not excreted in the urine. Instead, the unconjugated bilirubin is gradually deposited into various tissues, including the brain. These deposits can cause kernicterus (bilirubin encephalopathy), which is a potentially fatal condition characterized by severe jaundice and neurologic impairment, as seen in this child.

(Choice B) Dubin-Johnson syndrome is an autosomal recessive disorder characterized by the absence of a biliary transport protein, MRP2 (multidrug resistance protein 2), used in the hepatocellular excretion of bilirubin glucuronides into bile canaliculi. The liver is darkly pigmented as a result, but patients are typically asymptomatic and suffer no significant adverse effects.

(Choice C) Rotor syndrome is a rare autosomal recessive disorder characterized by an asymptomatic conjugated hyperbilirubinemia that results from numerous defects in the hepatic uptake and excretion of bilirubin pigments. Although patients are often jaundiced, they enjoy normal life expectancies.

(Choice D) High numbers of anaerobes and *Staphylococcus aureus* can result in the deconjugation (via removal of glycine and taurine) of bile acids, rendering them less soluble and therefore less able to form micelles. This deconjugation impedes the active reabsorption of bile acids into portal circulation at the terminal ileum, resulting in lipid malabsorption. However, there are no neurologic abnormalities associated with bilirubin deconjugation in the gut.

(Choice E) Within the colon, bacterial enzymes reduce bilirubin into urobilinogens. A small fraction of these urobilinogens return to the liver through the enterohepatic circulation; these will later either re-enter the gastrointestinal tract or be excreted through the urine. The urobilinogens that remain in the colon are excreted in the feces as stercobilin, contributing to its dark color. Fortunately, there are no neurologic abnormalities associated with impaired gut reabsorption of bilirubin.

Educational Objective:
Crigler-Najjar syndrome is an autosomal recessive disorder of bilirubin metabolism caused by a genetic lack of the UGT enzyme needed to catalyze bile glucuronidation. Unconjugated hyperbilirubinemia develops in these infants, causing kernicterus and often death.

Pathophysiology	Gastrointestinal & Nutrition	Hereditary hyperbilirubinemia
Subject	System	Topic

Copyright © UWorld. All rights reserved.

A 74-year-old man comes to the office due to several months of choking spells, dysphagia, and cough. He has also had recurrent episodes of pneumonia. His other medical problems include hypertension and osteoarthritis. Blood pressure is 130/70 mm Hg. The patient has foul-smelling breath, but his oropharyngeal and neck examinations are normal. Cardiopulmonary examination is also normal. A barium swallow study is performed and reveals an abnormality in the upper esophagus, as shown in the image below.

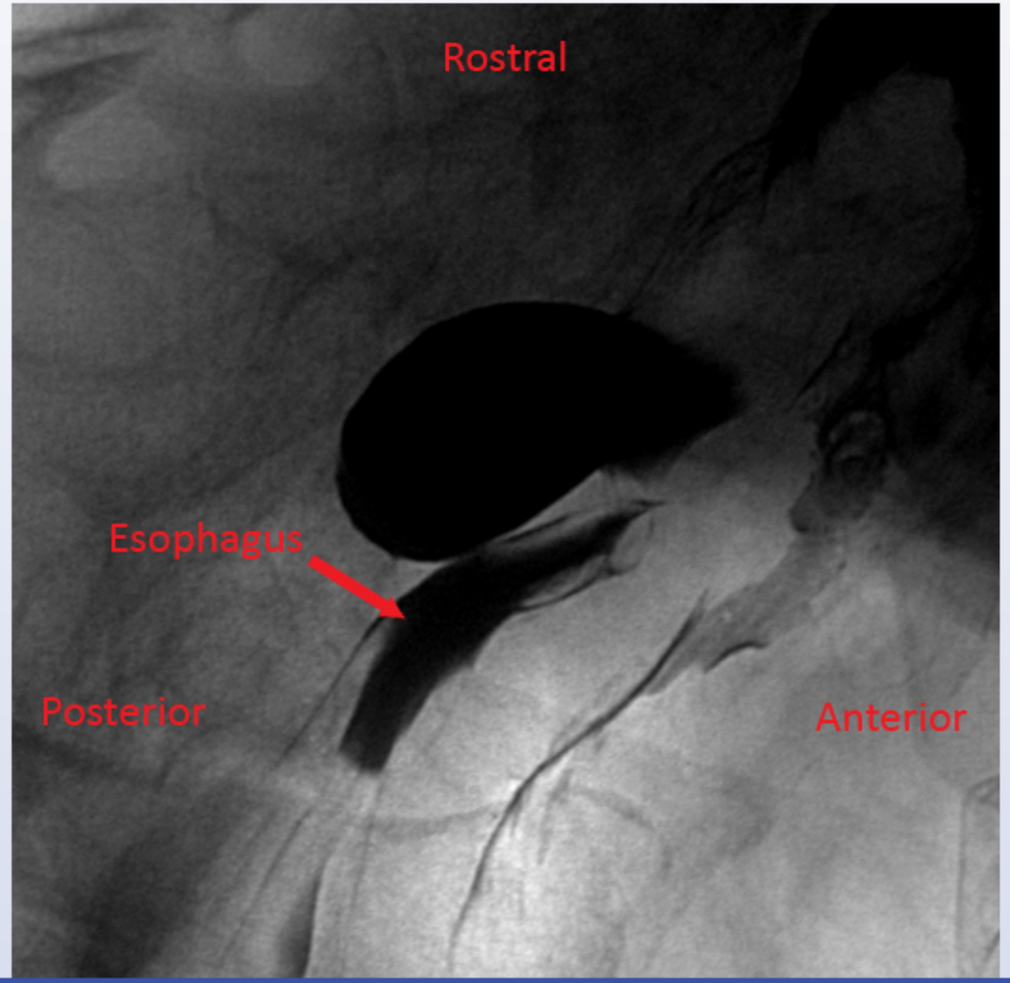

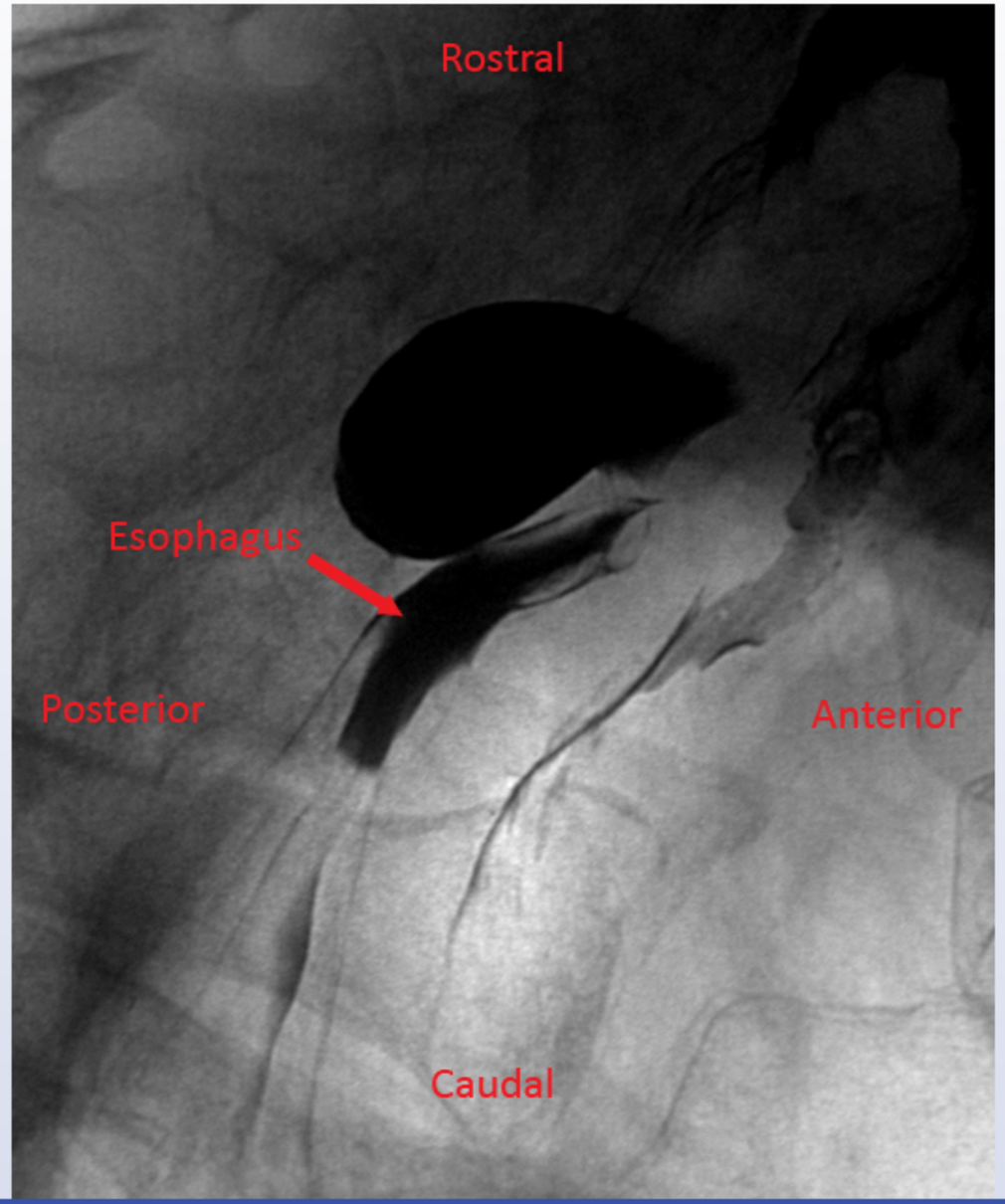
Rostral
Esophagus
Posterior
Anterior
Caudal

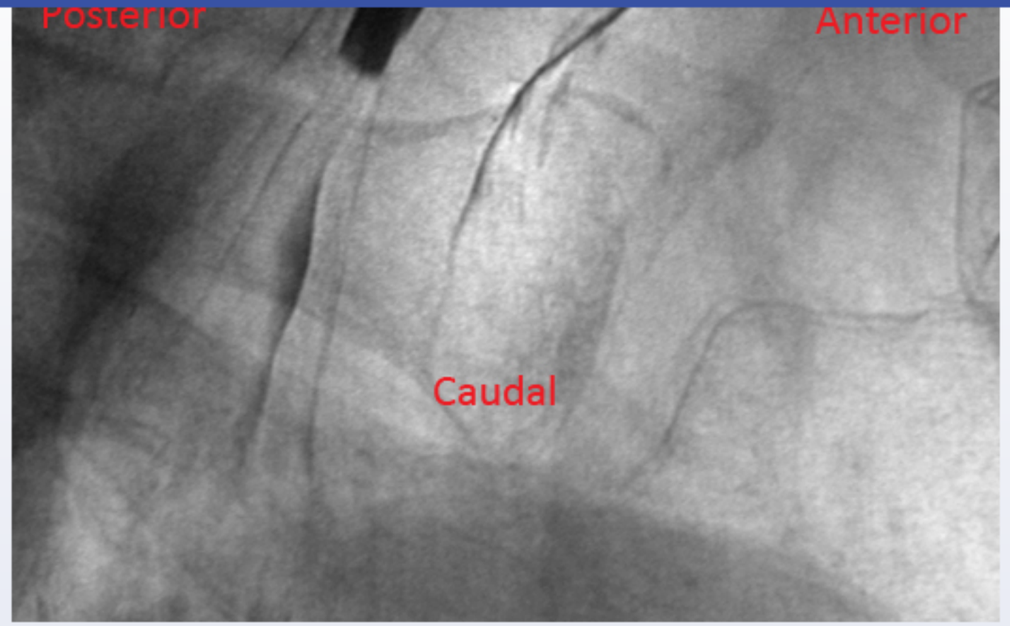

Which of the following mechanisms is the most likely cause of his symptoms?

- A. Cricopharyngeal motor dysfunction
- B. Degenerative changes of the myenteric plexus
- C. Increased intraluminal pressure in the stomach
- D. Retention cyst due to duct obstruction
- E. Scarring and traction of the esophagus

Submit

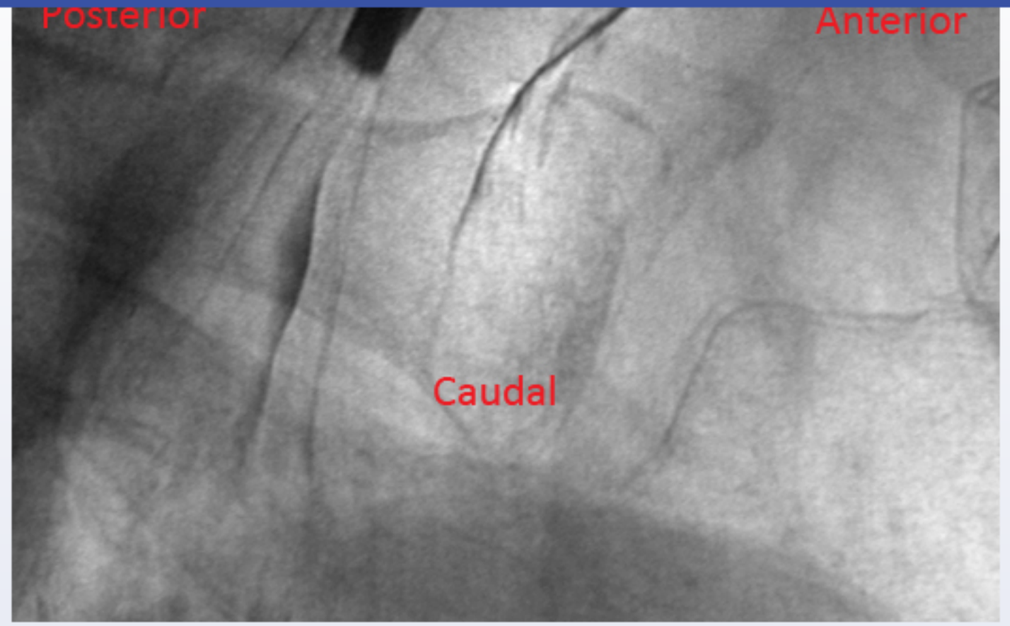

Which of the following mechanisms is the most likely cause of his symptoms?

- A. Cricopharyngeal motor dysfunction (44%)
- B. Degenerative changes of the myenteric plexus (16%)
- C. Increased intraluminal pressure in the stomach (5%)
- D. Retention cyst due to duct obstruction (15%)
- E. Scarring and traction of the esophagus (17%)

Omitted
Correct answer

44%
Answered correctly

09 secs
Time Spent

06/01/2020
Last Updated

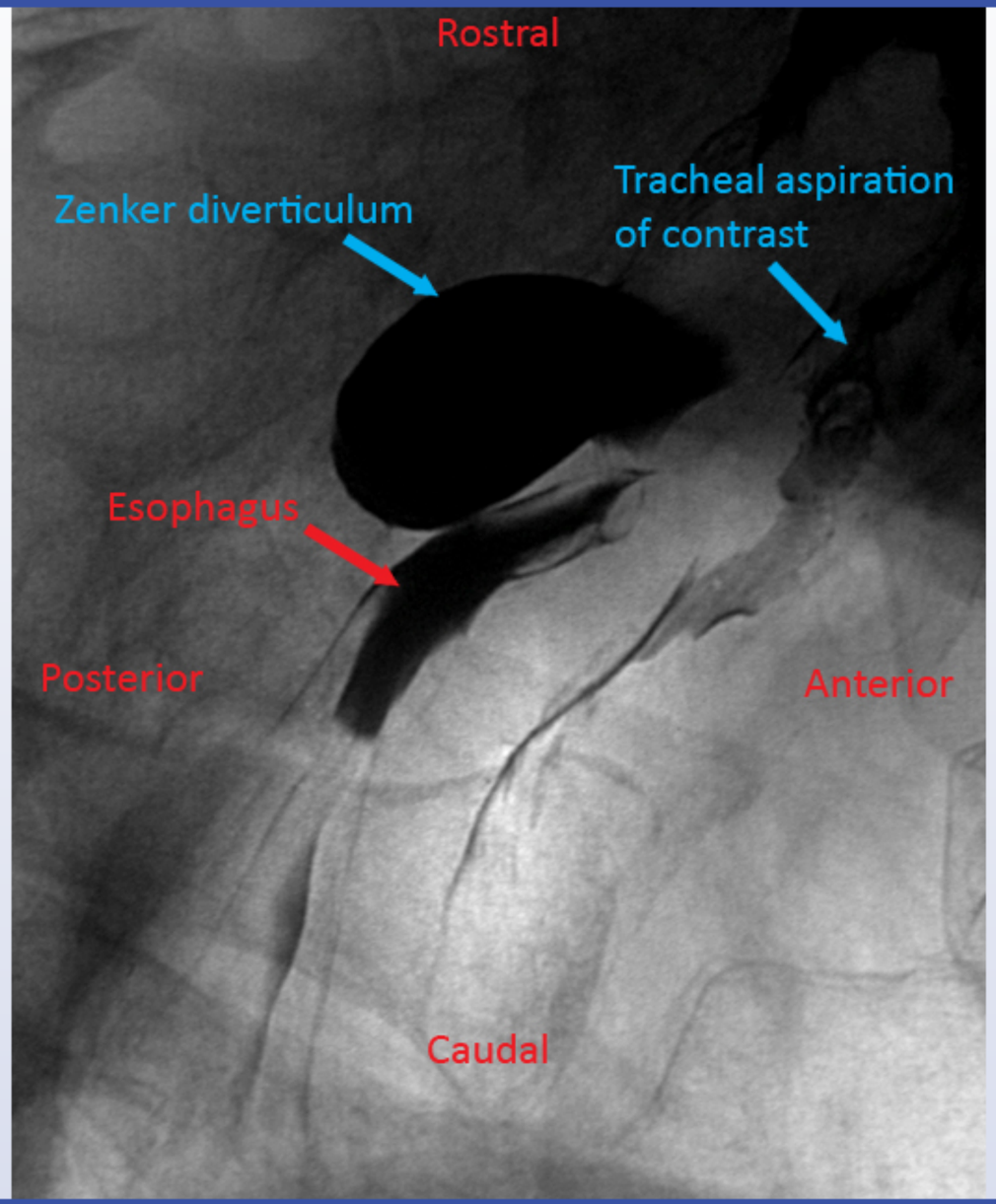
Rostral
Zenker diverticulum
Tracheal aspiration of contrast
Esophagus
Posterior
Anterior
Caudal

Deglutition (swallowing) is a complex process that involves 3 phases:

1. In the voluntary oral phase, the food bolus is collected in the back of the mouth and lifted upward to the posterior wall of the pharynx.
2. This initiates the pharyngeal phase, which consists of involuntary pharyngeal muscle contractions that propel the food bolus to the esophagus.
3. During the esophageal phase, food stretches the walls of the esophagus, stimulating peristalsis just above the site of distension and moving the food downward. Relaxation of the lower esophageal sphincter (LES) follows, allowing the food bolus to enter the stomach.

Abnormal spasm or diminished relaxation of the cricopharyngeal muscles during swallowing (**cricopharyngeal motor dysfunction**) is thought to be the underlying mechanism of Zenker diverticulum formation. This process results in early **oropharyngeal dysphagia** with a feeling of food obstruction at the level of the neck and coughing/choking. Increased oropharyngeal intraluminal pressure eventually results in herniation of the pharyngeal mucosa through a zone of muscle weakness (false diverticulum) in the posterior hypopharynx (Killian triangle). Patients consequently develop food retention with **halitosis/regurgitation**. **Pulmonary aspiration** of diverticular contents may also lead to recurrent pneumonia. As the diverticulum enlarges, it may become palpable as a lateral neck mass, and dysphagia can worsen due to luminal narrowing caused by extrinsic esophageal compression.

(Choice B) Degenerative changes of the myenteric plexus with impaired LES relaxation result in achalasia. Barium swallow typically shows esophageal dilation with esophagogastric junction narrowing ("bird's beak").

(Choice C) Mucosal tears around the gastroesophageal junction can be caused by increased intraluminal pressure in the stomach during prolonged or recurrent retching/vomiting (Mallory-Weiss syndrome).

(Choice D) Retention cysts form due to accumulation of trapped secretions following obstruction of a gland's duct. Chronic rhinosinusitis frequently causes mucus retention cysts in the maxillary sinus.

(Choice E) Mediastinal lymphadenitis (eg, due to tuberculosis, fungal infections) can cause scarring/traction of the mid-portion of the esophagus, resulting in the formation of true diverticula (containing all gut wall layers).

Educational objective:
Diminished relaxation of cricopharyngeal muscles during swallowing results in increased intraluminal pressure in the oropharynx. This may

Deglutition (swallowing) is a complex process that involves 2 phases:

Exhibit Display

Zenker diverticulum

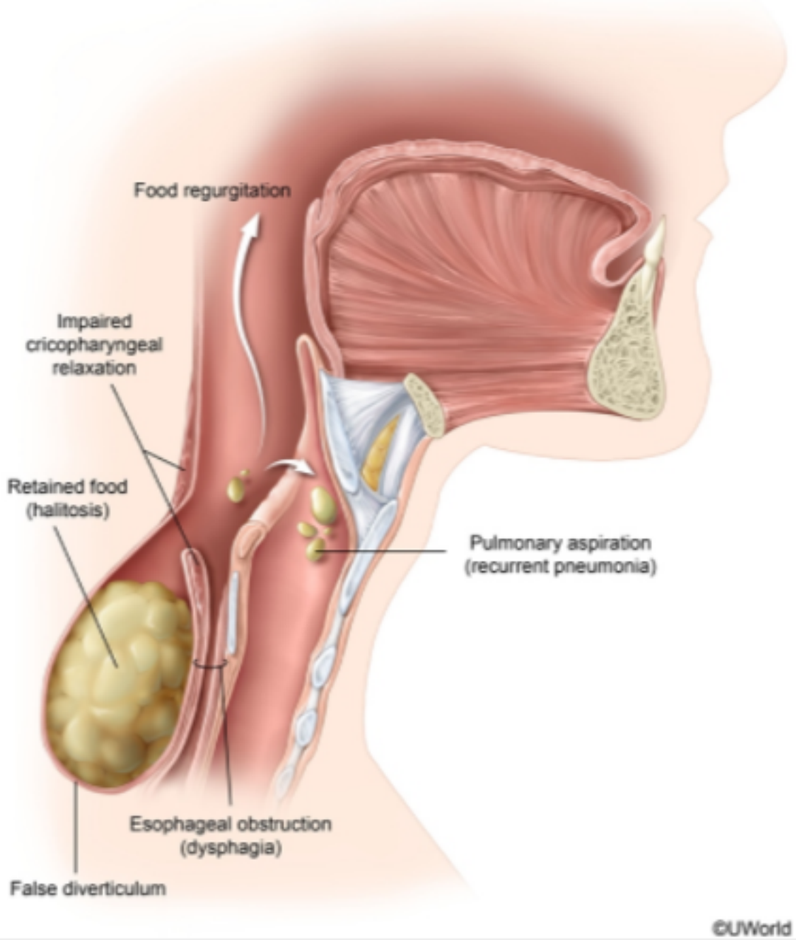

Zoom In | Zoom Out | Reset | Add To New Card | Existing Card

Diminished relaxation of cricopharyngeal muscles during swallowing results in increased intraluminal pressure in the oropharynx. This may eventually cause the mucosa to herniate through a zone of muscle weakness in the posterior hypopharynx, forming a Zenker (false) diverticulum.

Deglutition (swallowing) is a complex process that involves 2 phases:

Exhibit Display

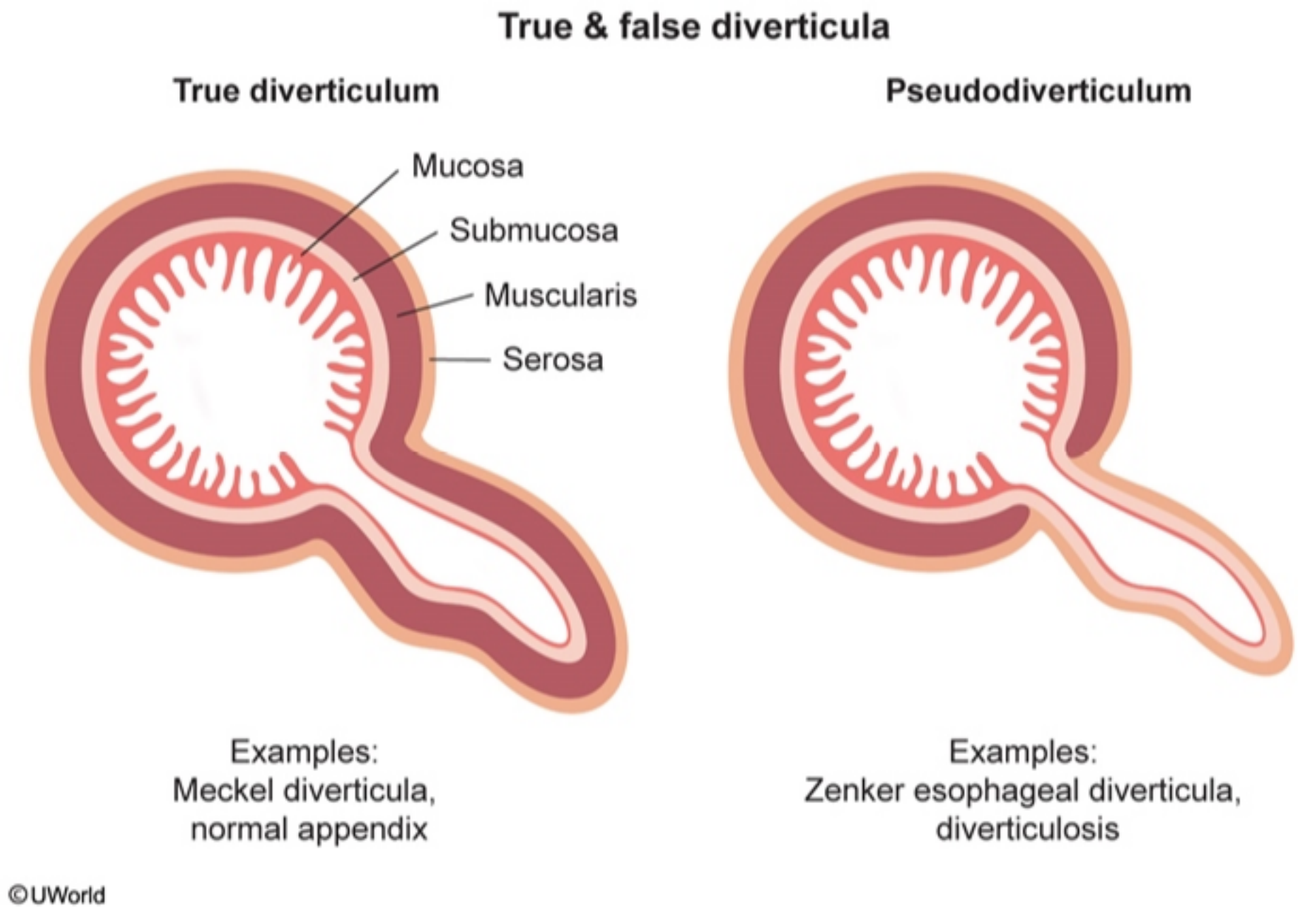

Zoom In | Zoom Out | Reset | Add To New Card | Existing Card

Diminished relaxation of cricopharyngeal muscles during swallowing results in increased intraluminal pressure in the oropharynx. This may eventually cause the mucosa to herniate through a zone of muscle weakness in the posterior hypopharynx, forming a Zenker (false) diverticulum.

Deglutition (swallowing) is a complex process that involves 2 phases:

Exhibit Display

Achalasia

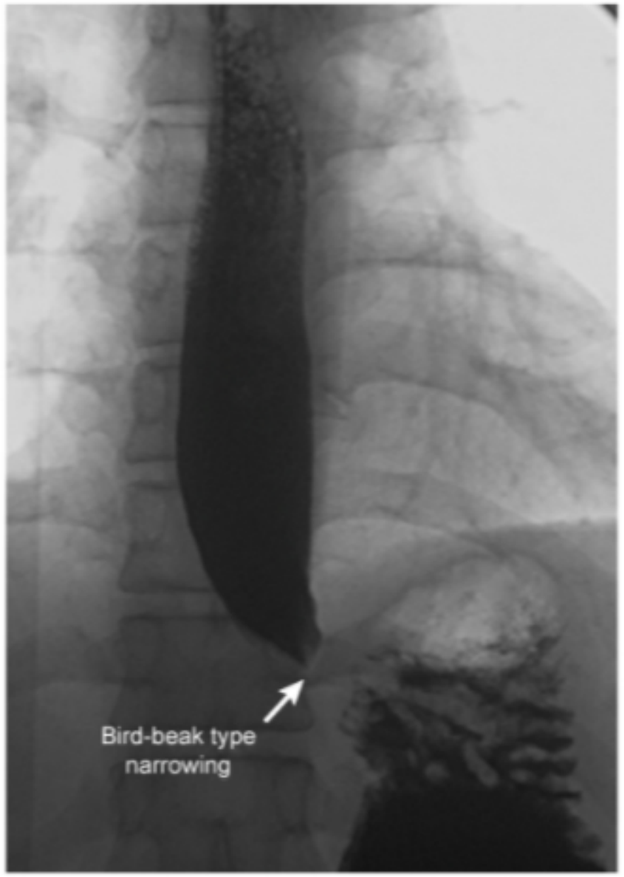

©UWorld

Zoom In | Zoom Out | Reset | Add To New Card | Existing Card

Diminished relaxation of cricopharyngeal muscles during swallowing results in increased intraluminal pressure in the oropharynx. This may eventually cause the mucosa to herniate through a zone of muscle weakness in the posterior hypopharynx, forming a Zenker (false) diverticulum.

be the underlying mechanism of Zenker diverticulum formation. This process results in early **oropharyngeal dysphagia** with a feeling of food obstruction at the level of the neck and coughing/choking. Increased oropharyngeal intraluminal pressure eventually results in herniation of the pharyngeal mucosa through a zone of muscle weakness (false diverticulum) in the posterior hypopharynx (Killian triangle). Patients consequently develop food retention with **halitosis/regurgitation**. **Pulmonary aspiration** of diverticular contents may also lead to recurrent pneumonia. As the diverticulum enlarges, it may become palpable as a lateral neck mass, and dysphagia can worsen due to luminal narrowing caused by extrinsic esophageal compression.

(Choice B) Degenerative changes of the myenteric plexus with impaired LES relaxation result in achalasia. Barium swallow typically shows esophageal dilation with esophagogastric junction narrowing ("bird's beak").

(Choice C) Mucosal tears around the gastroesophageal junction can be caused by increased intraluminal pressure in the stomach during prolonged or recurrent retching/vomiting (Mallory-Weiss syndrome).

(Choice D) Retention cysts form due to accumulation of trapped secretions following obstruction of a gland's duct. Chronic rhinosinusitis frequently causes mucus retention cysts in the maxillary sinus.

(Choice E) Mediastinal lymphadenitis (eg, due to tuberculosis, fungal infections) can cause scarring/traction of the mid-portion of the esophagus, resulting in the formation of true diverticula (containing all gut wall layers).

Educational objective:
Diminished relaxation of cricopharyngeal muscles during swallowing results in increased intraluminal pressure in the oropharynx. This may eventually cause the mucosa to herniate through a zone of muscle weakness in the posterior hypopharynx, forming a Zenker (false) diverticulum, which presents in elderly patients with oropharyngeal dysphagia, halitosis, regurgitation, and recurrent aspiration.

References

- Zenker's diverticulum: exploring treatment options.

Pathophysiology	Gastrointestinal & Nutrition	Zenker diverticulum
Subject	System	Topic

Copyright © UWorld. All rights reserved.

A 44-year-old woman comes to the clinic after several "near collisions" over the past month while driving at night. She also has generalized pruritus. The patient has not seen a physician for several years and has missed several scheduled appointments. She takes no medications. On physical examination, her skin is diffusely coarse and dry. Which of the following processes is most likely responsible for these findings?

- A. Chronic renal failure
- B. Hemolytic anemia
- C. Inadequate sunlight exposure
- D. Prolonged biliary obstruction
- E. Rheumatoid arthritis
- F. Strict vegan diet

Submit

A 44-year-old woman comes to the clinic after several "near collisions" over the past month while driving at night. She also has generalized pruritus. The patient has not seen a physician for several years and has missed several scheduled appointments. She takes no medications. On physical examination, her skin is diffusely coarse and dry. Which of the following processes is most likely responsible for these findings?

- A. Chronic renal failure (3%)
- B. Hemolytic anemia (3%)
- C. Inadequate sunlight exposure (2%)
- ✓ D. Prolonged biliary obstruction (64%)
- E. Rheumatoid arthritis (1%)
- F. Strict vegan diet (23%)

Omitted
Correct answer
D

64%
Answered correctly

02 secs
Time Spent

01/14/2020
Last Updated

Explanation

Vitamin A deficiency	
	• Insufficient dietary intake • Pancreatic insufficiency (chronic pancreatitis, cystic fibrosis)

Vitamin A deficiency	
Causes	• Insufficient dietary intake • Pancreatic insufficiency (chronic pancreatitis, cystic fibrosis) • Cholestatic liver disease/biliary obstruction • Intestinal malabsorption (inflammatory bowel disease, bariatric surgery)
Clinical features	• **Night blindness** • Severe eye dryness & **corneal ulceration** • Hyperkeratosis • Growth retardation

©UWorld

This patient's impaired driving in low light conditions ("night blindness") and thickened, dry skin (hyperkeratosis) are suggestive of **vitamin A deficiency**. Dietary intake of vitamin A comes from a combination of beta-carotene, a provitamin found in plants, and preformed vitamin A from animal sources. Vitamin A is necessary for **vision** (phototransduction, retinal and conjunctival development) and **keratinocyte differentiation**. Most individuals in the United States have adequate dietary intake of vitamin A, but patients may develop deficiency due to malabsorption related to biliary obstruction, exocrine pancreatic insufficiency, or small-bowel resection (eg, Crohn disease, bariatric surgery).

This patient, a middle-aged woman with generalized pruritus and signs of vitamin A deficiency, likely has underlying **primary biliary cholangitis** (PBC), a common autoimmune disease characterized by destruction of small bile ducts in the liver. Bile acids are important for solubilization and absorption of fats; patients with chronic biliary obstruction due to PBC may develop **malabsorption** of fats and **fat-soluble vitamins** (A, D, E, and K). Patients with PBC frequently have generalized pruritus due to bile acid accumulation in the skin. Visible jaundice is often not apparent until later in the disease course.

(Choices A and C) Inadequate exposure to sunlight can cause vitamin D deficiency in individuals without adequate dietary vitamin D intake.

This patient's impaired driving in low light conditions ("night blindness") and thickened, dry skin (hyperkeratosis) are suggestive of **vitamin A deficiency**. Dietary intake of vitamin A comes from a combination of beta-carotene, a provitamin found in plants, and preformed vitamin A from animal sources. Vitamin A is necessary for **vision** (phototransduction, retinal and conjunctival development) and **keratinocyte differentiation**. Most individuals in the United States have adequate dietary intake of vitamin A, but patients may develop deficiency due to malabsorption related to biliary obstruction, exocrine pancreatic insufficiency, or small-bowel resection (eg, Crohn disease, bariatric surgery).

This patient, a middle-aged woman with generalized pruritus and signs of vitamin A deficiency, likely has underlying **primary biliary cholangitis** (PBC), a common autoimmune disease characterized by destruction of small bile ducts in the liver. Bile acids are important for solubilization and absorption of fats; patients with chronic biliary obstruction due to PBC may develop **malabsorption** of fats and **fat-soluble vitamins** (A, D, E, and K). Patients with PBC frequently have generalized pruritus due to bile acid accumulation in the skin. Visible jaundice is often not apparent until later in the disease course.

(Choices A and C) Inadequate exposure to sunlight can cause vitamin D deficiency in individuals without adequate dietary vitamin D intake. Chronic renal failure can also result in vitamin D deficiency due to reduced production of 1,25-dihydroxyvitamin D.

(Choice B) Sickle cell disease is a form of chronic hemolytic anemia that can cause retinopathy due to microvascular occlusion, retinal ischemia, and neovascularization/hemorrhage. However, vision impairment would not be restricted to nighttime, and affected patients would likely have other vasoocclusive symptoms.

(Choice E) Rheumatoid arthritis can cause episcleritis or scleritis, which usually presents with ocular discomfort rather than night blindness.

(Choice F) A strict vegan diet can cause cobalamin, but not vitamin A, deficiency. Dietary deficiency of vitamin A is rarely seen in the United States and usually occurs in patients with highly unusual dietary patterns, severe mental illness, or alcoholism.

Educational objective:
Vitamin A deficiency causes night blindness and hyperkeratosis. Deficiency of this fat-soluble vitamin can develop in patients with biliary disorders, exocrine pancreatic insufficiency, or intestinal malabsorption.

References

- Vitamin A supplementation for cystic fibrosis.

1
2
3
4
5
6
7
8
9
10
11
12
13
14
15
16
17
18
19
20
21
22
23
24
25
26
27
28
29
30
31

Exhibit Display

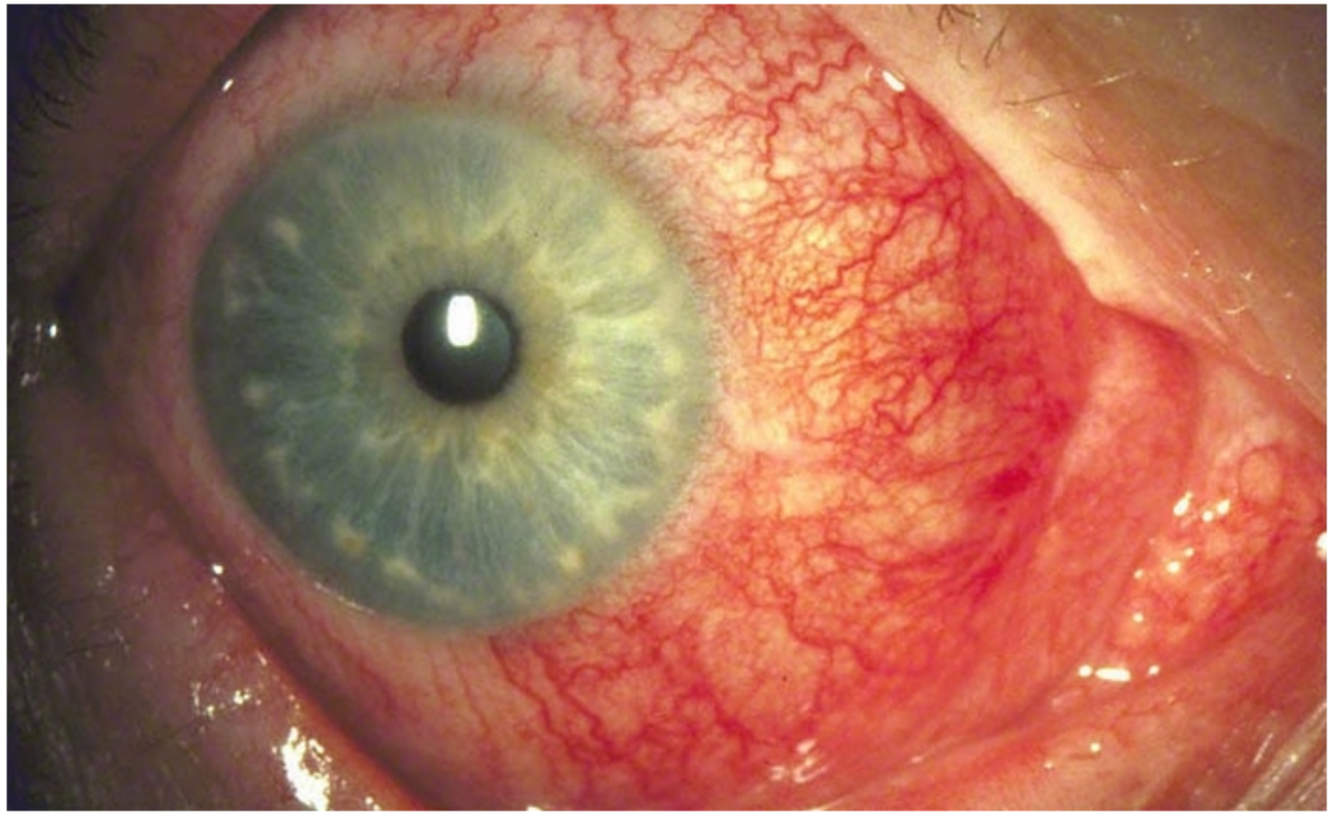

Zoom In | Zoom Out | Reset | Add To New Card | Existing Card

1
2
3
4
5
6
7
8
9
10
11
12
13
14
15
16
17
18
19
20
21
22
23
24
25
26
27
28
29
30
31

Exhibit Display

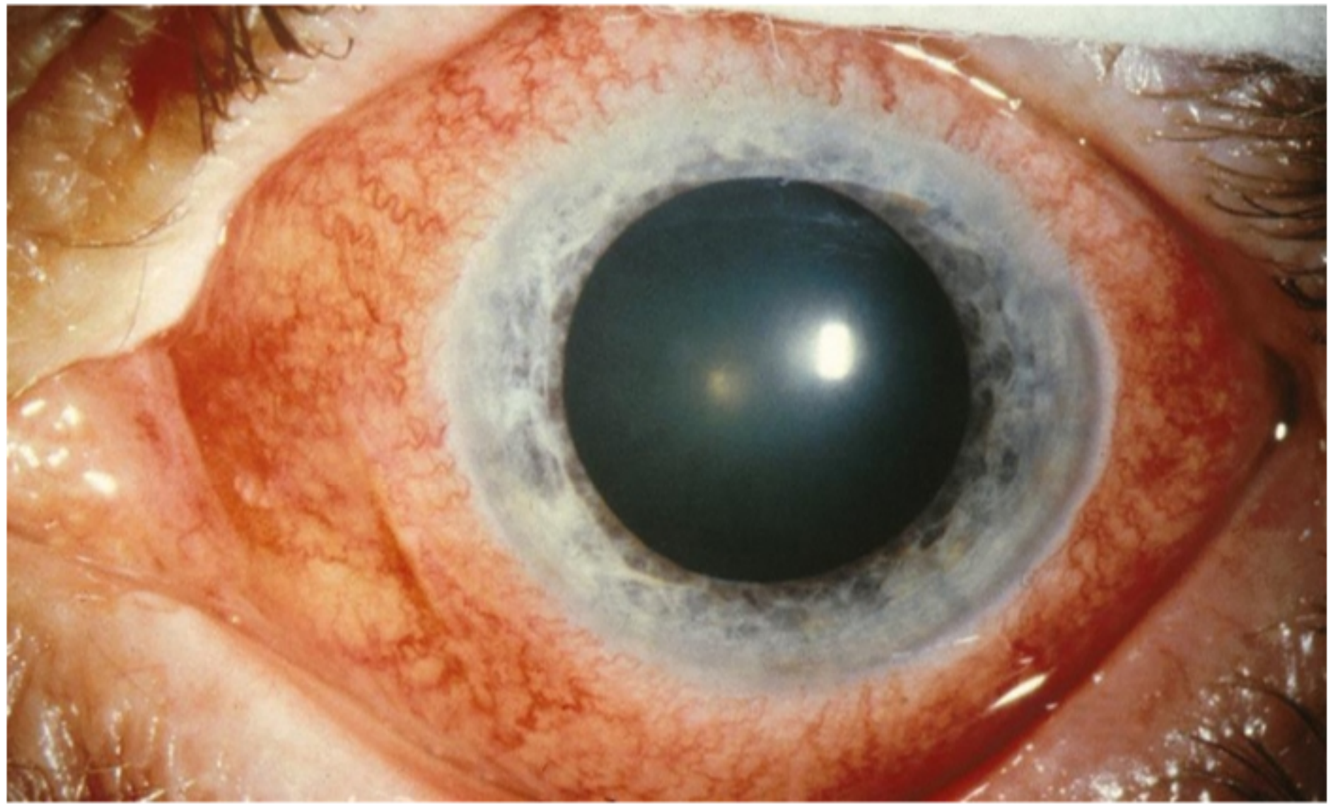

Zoom In | Zoom Out | Reset | Add To New Card | Existing Card

A 64-year-old man comes to the office due to acute-onset right upper quadrant abdominal pain, nausea, and vomiting. The patient had an extensive small bowel resection due to bowel ischemia a year ago and has been receiving total parenteral nutrition since then. His other medical problems include atrial fibrillation and hypertension. Examination shows right upper quadrant tenderness on deep palpation. Initial laboratory studies show moderate leukocytosis with normal hepatic transaminase, amylase, and lipase levels. Abdominal ultrasonography reveals gallstones and edema of the gallbladder wall. Review of prior records indicates that he had no gallstones noted on abdominal imaging performed prior to the bowel resection. Which of the following is most likely responsible for the development of gallstones in this patient?

A. Decreased cholecystokinin release due to lack of enteral stimulation

B. Decreased cholesterol conversion to bile acids due to liver dysfunction

C. High cholesterol content of the nutritional fluids

D. Inadequate supplementation of essential fatty acids

E. Increased gastrin release in response to parenteral amino acids

Submit

A 64-year-old man comes to the office due to acute-onset right upper quadrant abdominal pain, nausea, and vomiting. The patient had an extensive small bowel resection due to bowel ischemia a year ago and has been receiving total parenteral nutrition since then. His other medical problems include atrial fibrillation and hypertension. Examination shows right upper quadrant tenderness on deep palpation. Initial laboratory studies show moderate leukocytosis with normal hepatic transaminase, amylase, and lipase levels. Abdominal ultrasonography reveals gallstones and edema of the gallbladder wall. Review of prior records indicates that he had no gallstones noted on abdominal imaging performed prior to the bowel resection. Which of the following is most likely responsible for the development of gallstones in this patient?

- ✓ A. Decreased cholecystokinin release due to lack of enteral stimulation (84%)
- B. Decreased cholesterol conversion to bile acids due to liver dysfunction (3%)
- C. High cholesterol content of the nutritional fluids (7%)
- D. Inadequate supplementation of essential fatty acids (3%)
- E. Increased gastrin release in response to parenteral amino acids (0%)

Omitted
Correct answer
A

84%
Answered correctly

02 secs
Time Spent

02/09/2020
Last Updated

Explanation

Pathogenesis of cholesterol gallstones

Pathogenesis of cholesterol gallstones

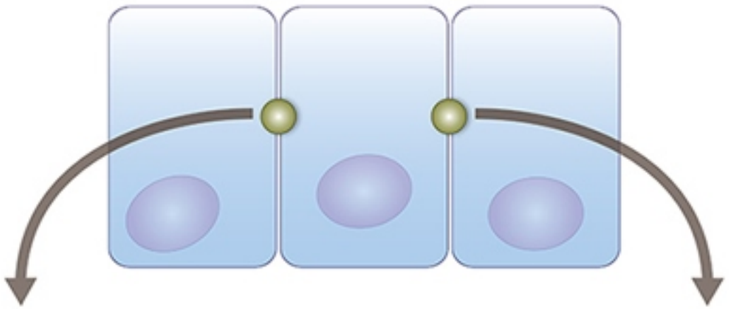

Normal levels of cholesterol, bile salts, and phosphatidylcholine

↓

Biliary micelles and vesicles remain unsaturated with cholesterol

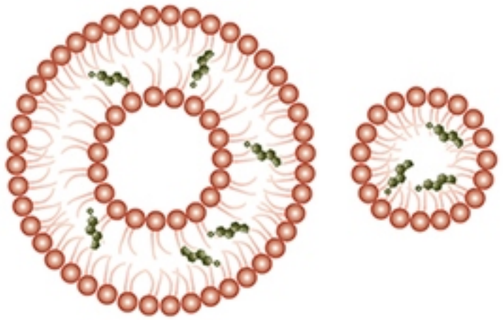

↑ Cholesterol
↓ Bile acids
↓ Phosphatidylcholine

↓

Bile becomes supersaturated with cholesterol

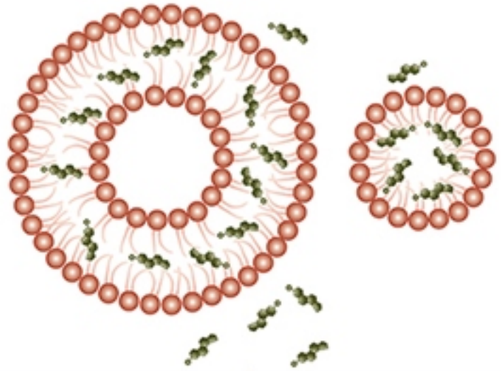

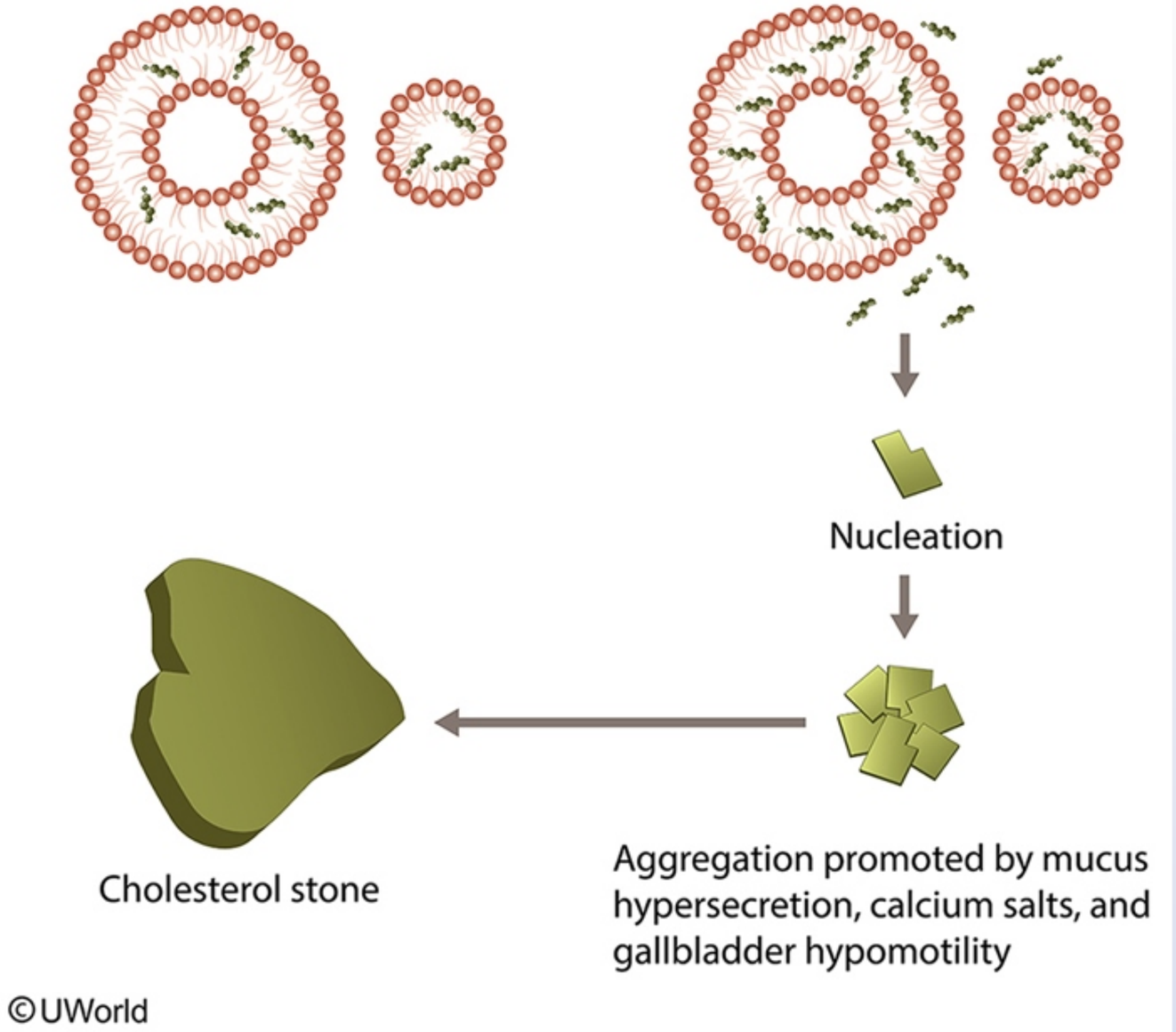

Cholesterol is secreted in bile, where it is solubilized by bile salts and phosphatidylcholine. If there is more cholesterol than can be dissolved by

©UWorld

Cholesterol is secreted in bile, where it is solubilized by bile salts and phosphatidylcholine. If there is more cholesterol than can be dissolved by the bile salts, the cholesterol will precipitate into insoluble crystals, leading to the formation of **gallstones**. Risk factors for gallstone formation include obesity or rapid weight loss, female sex, glucose intolerance, and hypomotility of the gallbladder (eg, pregnancy, prolonged fasting).

A prolonged course of **total parenteral nutrition** (TPN) is often complicated by gallstones. In normal individuals, enteral passage of fat and amino acids into the duodenum triggers release of cholecystokinin (CCK), leading to contraction of the gallbladder. The absence of normal enteral stimulation in patients receiving TPN leads to **decreased CCK release** and subsequent **biliary stasis**. In addition, patients with extensive resection of the ileum can have disruption to the normal enterohepatic circulation of bile acids, leading to inadequate solubilization of biliary cholesterol and formation of cholesterol crystals.

(Choice B) Advanced liver disease can impair cholesterol conversion to bile acids due to the diminished synthetic ability of injured hepatocytes, leading to supersaturation of the bile with cholesterol. This contributes to the increased risk of gallstones seen in cirrhotic individuals but would be unlikely in this patient with no evidence of hepatocellular dysfunction.

(Choice C) TPN preparations contain glucose, amino acids, and fats based on the individual patient's needs, with additional electrolytes, vitamins, minerals, and trace elements in carefully calculated amounts. Serum triglyceride levels may rise on TPN, but TPN does not contain significant amounts of cholesterol, and serum cholesterol levels do not usually change significantly.

(Choice D) Deficient supplementation of essential fatty acids in TPN is associated with a number of clinical complications, including dermatitis, alopecia, neuropathy, visual disturbances, and ataxia. Gallstones are not related.

(Choice E) Digested peptides and free amino acids in the gastric lumen are a major stimulus for gastrin release, so parenteral nutrition typically results in decreased (not increased) gastrin levels. Moreover, gastrin is not a significant factor in the formation of gallstones.

Educational objective:
The absence of normal enteral stimulation in patients receiving total parenteral nutrition leads to decreased cholecystokinin release, biliary stasis, and increased risk of gallstones. Resection of the ileum can also increase the risk of gallstones due to disruption of normal enterohepatic circulation of bile acids.

Pathophysiology Gastrointestinal & Nutrition Gallstone disease

include obesity or rapid weight loss, female sex, glucose intolerance, and hypomotility of the gallbladder (eg, pregnancy, prolonged fasting).

A prolonged course of **total parenteral nutrition** (TPN) is often complicated by gallstones. In normal individuals, enteral passage of fat and amino acids into the duodenum triggers release of cholecystokinin (CCK), leading to contraction of the gallbladder. The absence of normal enteral stimulation in patients receiving TPN leads to **decreased CCK release** and subsequent **biliary stasis**. In addition, patients with extensive resection of the ileum can have disruption to the normal enterohepatic circulation of bile acids, leading to inadequate solubilization of biliary cholesterol and formation of cholesterol crystals.

(Choice B) Advanced liver disease can impair cholesterol conversion to bile acids due to the diminished synthetic ability of injured hepatocytes, leading to supersaturation of the bile with cholesterol. This contributes to the increased risk of gallstones seen in cirrhotic individuals but would be unlikely in this patient with no evidence of hepatocellular dysfunction.

(Choice C) TPN preparations contain glucose, amino acids, and fats based on the individual patient's needs, with additional electrolytes, vitamins, minerals, and trace elements in carefully calculated amounts. Serum triglyceride levels may rise on TPN, but TPN does not contain significant amounts of cholesterol, and serum cholesterol levels do not usually change significantly.

(Choice D) Deficient supplementation of essential fatty acids in TPN is associated with a number of clinical complications, including dermatitis, alopecia, neuropathy, visual disturbances, and ataxia. Gallstones are not related.

(Choice E) Digested peptides and free amino acids in the gastric lumen are a major stimulus for gastrin release, so parenteral nutrition typically results in decreased (not increased) gastrin levels. Moreover, gastrin is not a significant factor in the formation of gallstones.

Educational objective:
The absence of normal enteral stimulation in patients receiving total parenteral nutrition leads to decreased cholecystokinin release, biliary stasis, and increased risk of gallstones. Resection of the ileum can also increase the risk of gallstones due to disruption of normal enterohepatic circulation of bile acids.

Pathophysiology	Gastrointestinal & Nutrition	Gallstone disease
Subject	System	Topic

Copyright © UWorld. All rights reserved.

A 60-year-old woman comes to the office with intermittent flatulence, crampy abdominal pain, and watery diarrhea. Her symptoms started 2 months ago after she recovered from an episode of acute gastroenteritis associated with nausea, vomiting, and diarrhea. The patient's symptoms are worse after drinking "too much milk." She usually has 1 or 2 glasses of wine every evening with dinner. Physical examination is unremarkable. Initial laboratory evaluation, including serum chemistries, blood counts, stool cultures, and studies for ova and parasites, is negative. Which of the following is most likely decreased in this patient?

- A. Breath hydrogen content
- B. Fecal fat
- C. Pancreatic enzymes
- D. Stool osmolality
- E. Stool pH

Submit

A 60-year-old woman comes to the office with intermittent flatulence, crampy abdominal pain, and watery diarrhea. Her symptoms started 2 months ago after she recovered from an episode of acute gastroenteritis associated with nausea, vomiting, and diarrhea. The patient's symptoms are worse after drinking "too much milk." She usually has 1 or 2 glasses of wine every evening with dinner. Physical examination is unremarkable. Initial laboratory evaluation, including serum chemistries, blood counts, stool cultures, and studies for ova and parasites, is negative. Which of the following is most likely decreased in this patient?

- A. Breath hydrogen content (9%)
- B. Fecal fat (2%)
- C. Pancreatic enzymes (17%)
- D. Stool osmolality (23%)
- ✓ E. Stool pH (47%)

Omitted
Correct answer
E

47%
Answered correctly

02 secs
Time Spent

02/26/2020
Last Updated

Explanation

This patient's presentation with flatulence, crampy abdominal pain, and watery diarrhea after consuming dairy products (eg, milk) is consistent with **lactose intolerance**. The most common cause of lactose intolerance is lactase nonpersistence, which is especially prevalent in Asian and African populations and is characterized by declining lactase expression in adulthood. This patient's lactose intolerance is most likely due to **secondary lactase deficiency**, an acquired condition resulting from inflammation/infection (eg, bacterial overgrowth, **infectious enteritis**, Crohn disease) that causes injury to the mucosal brush border of the small bowel where lactase is expressed.

This patient's presentation with flatulence, crampy abdominal pain, and watery diarrhea after consuming dairy products (eg, milk) is consistent with **lactose intolerance**. The most common cause of lactose intolerance is lactase nonpersistence, which is especially prevalent in Asian and African populations and is characterized by declining lactase expression in adulthood. This patient's lactose intolerance is most likely due to **secondary lactase deficiency**, an acquired condition resulting from inflammation/infection (eg, bacterial overgrowth, **infectious enteritis**, Crohn disease) that causes injury to the mucosal brush border of the small bowel where lactase is expressed.

Lactase deficiency results in incomplete hydrolysis of lactose into the monosaccharides glucose and galactose. The fermentation of undigested lactose by gut bacteria leads to increased production of short-chain fatty acids (eg, acetate, butyrate, propionate) that acidify the stool (**decreased stool pH**). During this process, hydrogen gas is also produced, leading to **increased breath hydrogen content (Choice A)**. In addition, the high amounts of undigested lactose in the bowel lead to **elevated stool osmolality**, which attracts excess water in the bowel lumen, causing osmotic diarrhea **(Choice D)**.

(Choice B) Inflammation/infection of the small intestine may lead to fat malabsorption, resulting in steatorrhea (eg, greasy, malodorous stool that is difficult to flush), weight loss, and increased fecal fat content. Fat malabsorption does not typically occur in patients with lactase deficiency.

(Choice C) Reduced pancreatic enzyme production (exocrine insufficiency) can occur with chronic pancreatitis, which is seen frequently in individuals with chronic alcoholism. Pancreatic enzyme levels are not affected by secondary lactase deficiency.

Educational objective:
Lactose intolerance presents with flatulence, crampy abdominal pain, and watery diarrhea after dairy product consumption. It can be acquired by inflammatory/infectious conditions that injure the mucosal brush border of the small intestine where lactase is expressed. Studies can show increased breath hydrogen content, reduced stool pH, and elevated stool osmolality.

References

- Lactose intolerance in adults: biological mechanism and dietary management.

Pathophysiology	Gastrointestinal & Nutrition	Lactose intolerance
Subject	System	Topic

Copyright © UWorld. All rights reserved.

A 54-year-old man comes to the office for evaluation of chronic diarrhea and weight loss. He has had bulky, foul-smelling stools for the past 8 months, which usually occur shortly after eating. There have been no nocturnal bowel movements, and he denies fecal incontinence. The patient also experiences dull, epigastric abdominal pain that is exacerbated by eating and unrelieved by antacids. He drinks 6 or 7 beers a day but denies tobacco or illicit drug use. Vital signs are within normal limits. The abdomen is tender to palpation in the epigastrium without distension, rebound, or guarding. Sudan staining of a fecal specimen is positive, and fecal occult blood testing is negative. Blood testing reveals normal hemoglobin. Which of the following pathophysiologic changes are most likely present in this patient?

A. Decreased bile acid synthesis

B. Decreased levels of fecal elastase

C. Impaired production of intrinsic factor

D. Increased pancreatic bicarbonate secretion

E. Small bowel villous atrophy

Submit

A 54-year-old man comes to the office for evaluation of chronic diarrhea and weight loss. He has had bulky, foul-smelling stools for the past 8 months, which usually occur shortly after eating. There have been no nocturnal bowel movements, and he denies fecal incontinence. The patient also experiences dull, epigastric abdominal pain that is exacerbated by eating and unrelieved by antacids. He drinks 6 or 7 beers a day but denies tobacco or illicit drug use. Vital signs are within normal limits. The abdomen is tender to palpation in the epigastrium without distension, rebound, or guarding. Sudan staining of a fecal specimen is positive, and fecal occult blood testing is negative. Blood testing reveals normal hemoglobin. Which of the following pathophysiologic changes are most likely present in this patient?

- A. Decreased bile acid synthesis (29%)
- ✓ B. Decreased levels of fecal elastase (40%)
- C. Impaired production of intrinsic factor (4%)
- D. Increased pancreatic bicarbonate secretion (7%)
- E. Small bowel villous atrophy (18%)

Omitted
Correct answer
B

40%
Answered correctly

02 secs
Time Spent

02/19/2020
Last Updated

Explanation

This patient with a history of alcohol use disorder who has chronic epigastric pain, weight loss, and steatorrhea (ie, bulky, fatty stools) likely has **chronic pancreatitis**, a progressive inflammatory disease that ultimately leads to pancreatic fibrosis. Major risk factors include **alcohol abuse**, recurrent episodes of acute pancreatitis, and smoking.

Patients classically have **epigastric pain** that worsens with meals; pain is initially intermittent but may become constant in advanced disease.

Explanation

This patient with a history of alcohol use disorder who has chronic epigastric pain, weight loss, and steatorrhea (ie, bulky, fatty stools) likely has **chronic pancreatitis**, a progressive inflammatory disease that ultimately leads to pancreatic fibrosis. Major risk factors include **alcohol abuse**, recurrent episodes of acute pancreatitis, and smoking.

Patients classically have **epigastric pain** that worsens with meals; pain is initially intermittent but may become constant in advanced disease. Other signs and symptoms of chronic pancreatitis are due to the following pathophysiologic changes:

- **Endocrine insufficiency**: Destruction of islet cells results in insulin-dependent diabetes mellitus.
- **Exocrine insufficiency**: Destruction of acinar cells results in lipase, elastase, amylase, trypsin, and chymotrypsin deficiency. This results in protein and fat malabsorption with **weight loss**, **steatorrhea**, and fat-soluble vitamin deficiencies.

Elastase is derived from a zymogen produced by pancreatic acinar cells and activated by trypsin in the duodenum; levels **correlate with pancreatic exocrine activity**. Therefore, **low fecal elastase** can help diagnose **pancreatic insufficiency** and supports a diagnosis of chronic pancreatitis. Other useful tests include Sudan staining (which identifies fecal fat) and hemoglobin A1c (which diagnoses diabetes mellitus).

(Choice A) Bile acid synthesis, which occurs in the liver, is not affected by chronic pancreatitis. Bile acids are necessary for proper biliary flow; therefore, bile acid synthesis disorders usually present with cholestasis, jaundice, and hepatic failure in neonates.

(Choice C) Autoimmune gastritis occurs due to autoantibodies directed at parietal cells and intrinsic factor, resulting in reduced intrinsic factor production. Although patients may have postprandial abdominal pain, they also typically have macrocytic anemia (due to vitamin B_{12} deficiency). Steatorrhea (due to fat malabsorption) is unexpected.

(Choice D) The pancreas normally produces a bicarbonate-rich fluid that neutralizes stomach acid. Chronic pancreatitis results in progressive pancreatic destruction, leading to decreased pancreatic bicarbonate production.

(Choice E) Villous atrophy of the small bowel is characteristic of celiac disease. Although patients can have steatorrhea and abdominal pain, celiac disease also usually causes iron deficiency anemia. In addition, chronic pancreatitis is more likely in this patient with heavy alcohol use.

Educational objective:
Chronic pancreatitis is an inflammatory disorder leading to pancreatic fibrosis and atrophy, resulting in endocrine (ie, insulin) and exocrine (eg,

Elastase is derived from a zymogen produced by pancreatic acinar cells and activated by trypsin in the duodenum; levels **correlate with pancreatic exocrine activity**. Therefore, **low fecal elastase** can help diagnose **pancreatic insufficiency** and supports a diagnosis of chronic pancreatitis. Other useful tests include Sudan staining (which identifies fecal fat) and hemoglobin A1c (which diagnoses diabetes mellitus).

(Choice A) Bile acid synthesis, which occurs in the liver, is not affected by chronic pancreatitis. Bile acids are necessary for proper biliary flow; therefore, bile acid synthesis disorders usually present with cholestasis, jaundice, and hepatic failure in neonates.

(Choice C) Autoimmune gastritis occurs due to autoantibodies directed at parietal cells and intrinsic factor, resulting in reduced intrinsic factor production. Although patients may have postprandial abdominal pain, they also typically have macrocytic anemia (due to vitamin B_{12} deficiency). Steatorrhea (due to fat malabsorption) is unexpected.

(Choice D) The pancreas normally produces a bicarbonate-rich fluid that neutralizes stomach acid. Chronic pancreatitis results in progressive pancreatic destruction, leading to decreased pancreatic bicarbonate production.

(Choice E) Villous atrophy of the small bowel is characteristic of celiac disease. Although patients can have steatorrhea and abdominal pain, celiac disease also usually causes iron deficiency anemia. In addition, chronic pancreatitis is more likely in this patient with heavy alcohol use.

Educational objective:
Chronic pancreatitis is an inflammatory disorder leading to pancreatic fibrosis and atrophy, resulting in endocrine (ie, insulin) and exocrine (eg, lipase, elastase, amylase, trypsin, chymotrypsin) insufficiencies. Patients typically have postprandial steatorrhea (ie, bulky diarrhea that is difficult to flush) and epigastric pain with meals. Low fecal elastase, positive Sudan staining, and elevated hemoglobin A1c support the diagnosis.

References

- Chronic pancreatitis: an international draft consensus proposal for a new mechanistic definition.
- Management of chronic pancreatitis.

Pathophysiology	Gastrointestinal & Nutrition	Chronic pancreatitis
Subject	System	Topic

Copyright © UWorld. All rights reserved.

A 34-year-old man with upper gastrointestinal bleeding is brought to the local emergency department by ambulance. He was found in front of a grocery store after customers called emergency medical services. The patient is unable to provide any information, but his medical records show a history of alcoholism. After undergoing emergency evaluation and appropriate resuscitation, his condition stabilizes. Gastric lavage fluid initially contained blood but cleared quickly. Upper endoscopy shows a linear mucosal tear at the gastroesophageal junction. The process directly responsible for causing this patient's mucosal tear will most likely result in which of the following acid-base disturbances?

A. High anion gap metabolic acidosis

B. Metabolic alkalosis

C. Normal anion gap metabolic acidosis

D. Respiratory acidosis

E. Respiratory alkalosis

Submit

A 34-year-old man with upper gastrointestinal bleeding is brought to the local emergency department by ambulance. He was found in front of a grocery store after customers called emergency medical services. The patient is unable to provide any information, but his medical records show a history of alcoholism. After undergoing emergency evaluation and appropriate resuscitation, his condition stabilizes. Gastric lavage fluid initially contained blood but cleared quickly. Upper endoscopy shows a linear mucosal tear at the gastroesophageal junction. The process directly responsible for causing this patient's mucosal tear will most likely result in which of the following acid-base disturbances?

- A. High anion gap metabolic acidosis (15%)
- ✓ B. Metabolic alkalosis (72%)
- C. Normal anion gap metabolic acidosis (9%)
- D. Respiratory acidosis (1%)
- E. Respiratory alkalosis (1%)

Omitted
Correct answer
B

72%
Answered correctly

02 secs
Time Spent

05/29/2020
Last Updated

Explanation

Characteristics of gastroesophageal mural injury		
	Mallory-Weiss syndrome	**Boerhaave syndrome**
Etiology	• Forceful retching • **Mucosal** tear	• Forceful retching • **Transmural** tear

Characteristics of gastroesophageal mural injury		
	Mallory-Weiss syndrome	**Boerhaave syndrome**
Etiology	• Forceful retching • **Mucosal** tear • Submucosal venous or arterial plexus bleeding	• Forceful retching • **Transmural** tear • Spillage of esophageal air/fluid into surrounding tissues
Clinical presentation	• Epigastric/back pain • **Hematemesis** (bright red or coffee-ground) • Possible hypovolemia	• Chest/back/epigastric pain • **Crepitus, crunching sound** (Hamman sign) • Odynophagia, dyspnea, fever, sepsis
Studies	• **Upper GI endoscopy** confirms diagnosis (& can treat persistent bleeding)	• Chest x-ray: pneumothorax, pneumomediastinum, pleural effusion • **Esophagography or CT scan with water-soluble contrast** confirms diagnosis
Management	• Acid suppression • **Most heal spontaneously**	• Acid suppression, antibiotics, NPO • **Emergency surgical consultation**

GI = gastrointestinal.

This patient has a **Mallory-Weiss tear** of the gastric mucosa near the gastroesophageal junction. Mallory-Weiss tears are caused by high intragastric pressure being transmitted to the esophagus through a tight lower esophageal sphincter. They are most commonly caused by repetitive **retching and vomiting** but can also occur with straining during defecation or heavy lifting, seizures, blunt abdominal injury, and upper gastrointestinal endoscopy. Repetitive vomiting leads to **metabolic alkalosis** due to net loss of acidic gastric secretions.

(Choice A) Unlike methanol or ethylene glycol, acute ethanol intoxication does not usually cause high anion gap metabolic acidosis, but chronic alcoholism can cause ketoacidosis in malnourished patients. Ethanol abuse is a common predisposing factor for Mallory-Weiss tears; however, it is the repetitive vomiting and retching that directly cause the tears.

(Choice C) Normal anion gap metabolic acidosis is usually caused by loss of bicarbonate, which can occur with prolonged diarrhea. Recurrent

Management	• Acid suppression • **Most heal spontaneously**	• Acid suppression, antibiotics, NPO • **Emergency surgical consultation**

GI = gastrointestinal.

This patient has a **Mallory-Weiss tear** of the gastric mucosa near the gastroesophageal junction. Mallory-Weiss tears are caused by high intragastric pressure being transmitted to the esophagus through a tight lower esophageal sphincter. They are most commonly caused by repetitive **retching and vomiting** but can also occur with straining during defecation or heavy lifting, seizures, blunt abdominal injury, and upper gastrointestinal endoscopy. Repetitive vomiting leads to **metabolic alkalosis** due to net loss of acidic gastric secretions.

(Choice A) Unlike methanol or ethylene glycol, acute ethanol intoxication does not usually cause high anion gap metabolic acidosis, but chronic alcoholism can cause ketoacidosis in malnourished patients. Ethanol abuse is a common predisposing factor for Mallory-Weiss tears; however, it is the repetitive vomiting and retching that directly cause the tears.

(Choice C) Normal anion gap metabolic acidosis is usually caused by loss of bicarbonate, which can occur with prolonged diarrhea. Recurrent vomiting causes metabolic alkalosis, not acidosis.

(Choices D and E) Respiratory acidosis usually occurs in patients with chronic obstructive pulmonary disease or central nervous system depression (eg, narcotic overdose). Respiratory alkalosis occurs with hyperventilation (eg, panic attacks, pulmonary emboli).

Educational objective:
A Mallory-Weiss tear is a tear in the gastric mucosa near the gastroesophageal junction. It typically results from repetitive forceful vomiting, which can also cause metabolic alkalosis.

References

• Diagnosis and management of upper gastrointestinal bleeding.

Pathophysiology	Gastrointestinal & Nutrition	Mallory-weiss syndrome
Subject	System	Topic

Copyright © UWorld. All rights reserved.